

Extraction of a Foreign Body from the Breast Using Radio-guided Occult Lesion Localization (ROLL): Metallic Foreign Body in the Breast

Fatih Dal¹, Hasan Ökmen¹, Meltem Küçük Yılmaz¹, Serkan Sarı¹, Mehmet Ali Nazlı², Esra Arslan³

¹Department of General Surgery, Health Sciences University Turkish Ministry of Health, Istanbul Research and Training Hospital, İstanbul, Turkey

²Department of Radyology, Health Sciences University Turkish Ministry of Health, Istanbul Research and Training Hospital, İstanbul, Turkey

³Department of Nuclear Medicine, Health Sciences University Turkish Ministry of Health, Istanbul Research and Training Hospital, İstanbul, Turkey

ABSTRACT

The most common clinical causes of metallic foreign body in the breast are surgical clips, pieces of guide-wire and gunshot wounds. Metallic foreign bodies can lead to local breast pain, abscesses, pneumothorax after granulomas or migration, and cardiac tamponade. Mammotome biopsy, fluoroscopy, guide-wire biopsy and radio-guided occult lesion localization (ROLL) are the standard techniques applied for surgical excision of non-palpable breast lesions. This article presents the second case in the literature undergoing the ROLL technique for the removal of a metallic foreign body from the breast.

Keywords: Breast, gunshot injury, metallic body, mammography

Cite this article as: Dal F, Ökmen H, Küçük Yılmaz M, Sarı S, Nazlı MA, Arslan E. Extraction of a Foreign Body from the Breast Using Radio-guided Occult Lesion Localization (ROLL): Metallic Foreign Body in the Breast. Eur J Breast Health 2017; 13: 159-160.

Introduction

Metallic foreign bodies (MFB) within the breast develop out of surgical clips, broken pieces of guide-wires and gunshot injuries (GSI) (1). As such, metallic foreign bodies can cause local breast pain, abscess, cardiac tamponade, granuloma or pneumothorax, which are clinically significant (1-2). In this report, we aim to present a 35-year-old female patient diagnosed with a metallic foreign body in the left breast as the second case in the literature in which radio-guided occult lesion localization (ROLL) was used for the excision of the foreign body.

Case Presentation

A 35-year-old female patient presented to the general surgery department with pain in the left breast. She had a history of a gunshot wound in the breast four months ago, shortly after which the symptoms had started. The patient told that the bullet was still in her breast. Physical examination revealed tenderness in the upper outer quadrant of the left breast. The breast ultrasound indicated a 10 mm hyper-echoic formation in the upper outer quadrant of the left breast. The mammography and chest x-ray confirmed the presence of a 10 mm hyperdense MFB within the breast. The object was not fragmented (Figure 1-2). It was decided to surgically remove the foreign body and written informed consent from the patient was obtained. On the morning of surgery, the MFB was marked using the ROLL technique in the radiology unit. The foreign body was excised along with the surrounding fibrosis and inflammatory breast tissue by applying a gamma probe through a 3 cm incision in a 20-minute operation. Specimen mammography was performed on the excision material to confirm that the MFB was located within the tissue (Figure 3).

Discussion and Conclusion

Since metallic foreign bodies can cause symptoms such as local breast pain, abscess, cardiac tamponade, granuloma or pneumothorax, they have clinical importance (1-2). Korbin et al. (3) reported broken guide-wire pieces in 5 of 3500 patients who underwent guide-wire biopsy. Montrey et al. (4) reported that the most common types of MFB in the breast are surgical clips and broken pieces of guide-wires. In that same study, the prevalence of MFB related to broken guide-wire pieces was found to be 0.2%. As reported in several studies addressing MFB in the breast, surgical clips, pieces of guide-wires and GSIs are the most common factors in etiology. Mammography is usually helpful for the diagnosis (1, 2, 5). In our case, the patient had a history of GSI as well as pain in the left breast as consistent with the literature. The MFB was clearly visualised in ultrasound, mammography and chest x-ray.

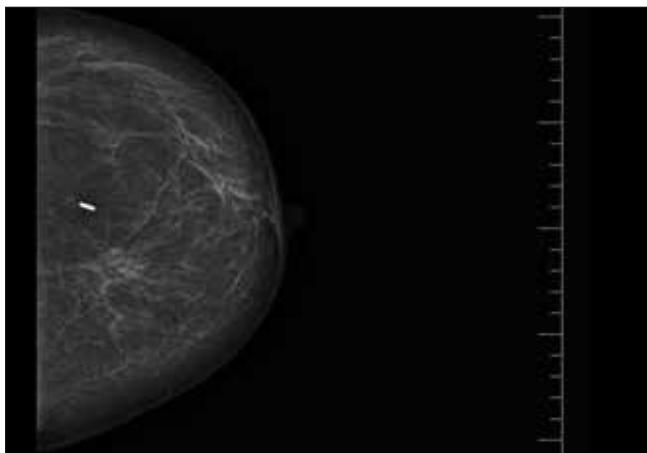


Figure 1. Mammography of left breast and the foreign body

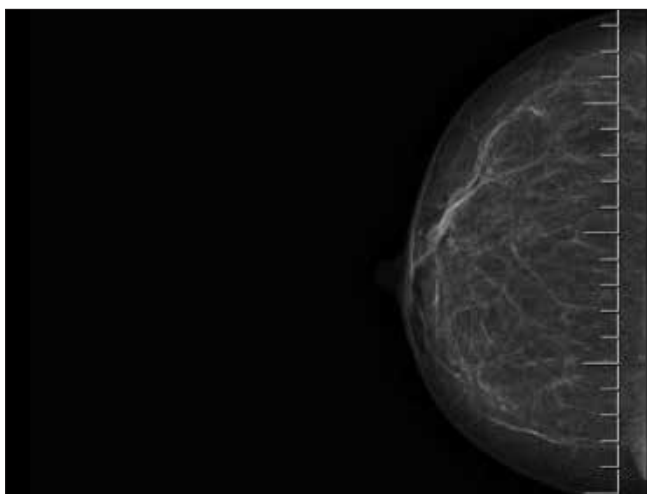


Figure 2. Mammography of right breast




Figure 3. Specimen mammography

Metallic foreign bodies within the breast are treated through surgical excision. Guide-wire, fluoroscopy, mammotome biopsy and ROLL are the guiding techniques reported in the literature for non-palpable MFBs (1, 2, 4-6). The ROLL technique was first introduced in 1996 and has since been successfully applied for various cases including non-palpable breast lesions, parathyroid adenoma, recurrent papillary thyroid cancer and extraction of MFBs from the breast (5, 7, 8, 9). The use of ROLL for the extraction of a foreign body from the breast was first reported in 2010 (5). Moreno et al. (10) stated the ROLL technique to be an effective method for excision of non-palpable breast lesions due to its advantages such as good cosmetic outcomes, lower cost and shortened duration of operation and hospitalization. As the required radionuclide dose in clinical use is

low, there is no need for additional safety precautions (11). Our case is the second case in the literature having the ROLL technique applied for the removal of a metallic foreign body from the breast with similar advantages like smaller incision, shorter operative time and shorter hospital stay.

In conclusion, considering the advantages it offers such as three-dimensional localization, smallness of incision, reduced aesthetic concern, shortened duration of operation and hospitalization and reduced cost, the ROLL technique can be conveniently used for extracting non-palpable organic, inorganic and metallic foreign bodies from the breast.

Informed Consent: Written informed consent was obtained from patient who participated in this study.

Peer-review: Externally peer-reviewed.

Author Contributions: Concept - F.D.; Desingn - F.D., S.S.; Supervision - F.D., S.S.; Fundings - F.D., M.K.Y.; Materials - F.D., M.N., E.A.; Data Collection and/or Processing - M.N., H.Ö.; Analysis and/or Interpretation - F.D., S.S.; Literature Search - F.D., M.K.Y., E.A.; Writing Manuscript - F.D., H.Ö.; Critical Review - F.D., S.S.

Conflict of Interest: No conflict of interest was declared by the authors.

Financial Disclosure: The authors declared this study has received no financial support.

References

1. Akyol C, Akmak A, Kepenekci I, Erkek AB, Baskan S. Metallic foreign body in the breast. *Eur J Breast Health* 2008; 4: 125-126.
2. Bozdag A, Baykara M. Metallic Foreign Bodies in the Breast: A Case Report. *Firat University Medical Journal of Health Sciences* 2014; 28: 33-34.
3. Korbin CD, Denison CM, Lester S. Metallic particles on mammography after wire localization. *Am J Roentgenol* 1997; 169: 1637-1638. (PMID:9393182) [CrossRef]
4. Montrey JS, Levy JA, Brenner RJ. Wire fragments after needle localization. *Am J Roentgenol* 1996; 167: 1267-1269. (PMID:8911193) [CrossRef]
5. Aydogan F, Atasoy D, Olgun DC, Dikici AS, Aliyev A, Gazioglu E. Extraction of a foreign body from the breast parenchyma using radioguided occult lesion localisation (ROLL) technique: a new approach. *Br J Radiol* 2010; 83: 147-149. (PMID:20603400) [CrossRef]
6. Parker SH, Kercher JM, Dennis MA. Sonographically guided mammotome extraction of retained localization wire. *Am J Roentgenol* 1999; 173: 903-904. (PMID:1051145) [CrossRef]
7. Luini A, Zurrida S, Galimberti V, Paganelli G. Radioguided surgery of occult breast lesions. *Eur J Cancer* 1998; 34: 204-205. (PMID:9624261)
8. Ilgan S, Ozbas S, Bilezikci B, Sengezer T, Aydin OU, Gursoy A, Kocak S. Radioguided occult lesion localization for minimally invasive parathyroidectomy: technical consideration and feasibility. *Nucl Med Commun* 2014; 35: 1167-1174. (PMID:25153058) [CrossRef]
9. Giles YS, Sarici IS, Tunca F, Sormaz IC, Salmaslioglu A, Adalet I, Ozgur I, Tezelman S, Terzioglu T. The rate of operative success achieved with radioguided occult lesion localization and intraoperative ultrasonography in patients with recurrent papillary thyroid cancer. *Surgery* 2014; 156: 1116-1126. (PMID:24953276) [CrossRef]
10. Moreno M, Wiltgen JE, Bodanese B, Schmitt RL, Gutflen B, Da Fonseca LM. Radioguided breast surgery for occult lesion localization- correlation between two methods. *J Exp Clin Cancer Res* 2008; 27: 29. (PMID:18706096) [CrossRef]
11. Rampaul RS, Dudley NJ, Thompson JZ, Burrell H, Evans AJ, Wilson AR, Macmillan RD. Radioisotope for occult lesion localisation (ROLL) of the breast does not require extra radiation protection procedures. *Breast* 2003; 12: 150-152. [CrossRef]