



Leiomyosarcoma of the Breast: Case Report and Review of the Literature

Amal Alimi, Hafedh Abbassi, Skander Abid, Amrou Dinari, Abdeljlil Khelifi, Samir Hidar, Sassi Boughizane, Hedi Khairi

Department of Obstetrics and Gynecology, Sousse University Faculty of Medicine, Farhat Hached Teaching Hospital, Sousse, Tunisia

ABSTRACT

Primary breast leiomyosarcoma is an extremely rare malignancy, accounting for approximately 1% of breast tumors and less than 5% of soft tissue sarcomas. Due to its rarity, standardized treatment guidelines remain unclear. We report the case of a 38-year-old woman who presented with a 3 cm, freely mobile breast nodule, initially classified as American College of Radiology Breast Imaging Reporting and Data System 4 on imaging. Core needle biopsy confirmed primary breast leiomyosarcoma, with histopathological and immunohistochemical analysis revealing strong positivity for α -smooth muscle actin, desmin, and H-caldesmon, consistent with smooth muscle differentiation. Epithelial, neural, and vascular markers were negative, ruling out differential diagnoses. The Ki-67 index was 15%, indicating moderate proliferative activity. Staging classified the tumor as T2N0M0 (Stage IIA, the American Joint Committee on Cancer 8th edition), and the patient underwent radical mastectomy with sentinel lymph node exploration, followed by adjuvant radiotherapy. Despite the aggressive nature of leiomyosarcomas, this case exhibited favorable prognostic factors, including small tumor size, intermediate grade, negative margins, and no lymphatic spread, suggesting a less aggressive course. After four years of follow-up, the patient remains free of complications, underscoring the importance of long-term monitoring and the need for further research to refine therapeutic approaches.

Keywords: Breast cancer subtypes; immunohistochemistry; leiomyosarcoma; mastectomy; rare tumors

Cite this article as: Alimi A, Abbassi H, Abid S, Dinari A, Khelifi A, Hidar S, et al. Leiomyosarcoma of the breast: case report and review of the literature. Eur J Breast Health. [Epub Ahead of Print].

Key Points

- Primary sarcomas can affect any organ but their occurrence in the breast remains exceptional. Only a few isolated cases have been reported in the literature.
- Given the clinical and epidemiological diversity and rarity of this subtype of cancer, its positive diagnosis is based on anatomopathological examination where immunohistochemistry is often used.
- The treatment follows the same rules as those used in the treatment of soft tissue sarcomas.

Introduction

Primary breast sarcoma (PBS) is a rare and aggressive entity that fits into the nosological framework of non-epithelial tumors of the breast. They account for about 1% of breast tumors and less than 5% of all soft tissue sarcomas (1). Two groups can be distinguished: Phyllodes sarcomas, which are specific to the breast, and non-phyllodes sarcomas, such as leiomyosarcomas, which are ubiquitous but rarely, if ever, found in the breast (2).

These tumors are characterized by non-specific clinical manifestations that often mimic benign pathology, significant histological diversity, and a poor prognosis (3).

We report a case of primary breast leiomyosarcoma, discovered through self-palpation and treated surgically, followed by additional radiotherapy.

Written informed consent was obtained from the patient for publication of this case report.

Case Report

A 38-year-old woman with no significant medical history or familial history of mastopathy presented with a right breast nodule. She is multiparous with two children and a history of breastfeeding. She has never used hormonal contraceptives.

Corresponding Author:
Alimi Amal MD; alimiamal44@gmail.com

Received: 01.02.2025
Accepted: 14.04.2025
Epub: 29.05.2025



Clinical examination revealed a 3 cm nodule in the lower outer quadrant of the right breast, freely mobile with no overlying skin changes. The axillary fossa was unremarkable. A breast ultrasound, performed for better lesion characterization, revealed a mass suggestive of a phyllodes tumor classified as American College of Radiology Breast Imaging Reporting and Data System category 4 (ACR4). A breast ultrasound, performed for better lesion characterization, revealed a mass suggestive of a phyllodes tumor classified as ACR4, indicating a suspicious lesion.

A core needle biopsy established the diagnosis of primary breast leiomyosarcoma, confirmed through histopathological evaluation and immunohistochemical analysis. The tumor exhibited strong positivity for α -smooth muscle actin, desmin, and H-caldesmon, supporting its smooth muscle differentiation. In contrast, epithelial (Cytokeratin AE1/AE3, EMA), neural (S-100), and vascular markers (CD34, CD31) were negative, effectively excluding metaplastic carcinoma, malignant peripheral nerve sheath tumors, and angiosarcoma. The Ki-67 proliferation index was 15%, suggesting a moderate proliferative activity.

A thoracic-abdominal-pelvic CT scan and bone scintigraphy showed no evidence of metastatic spread.

The tumor was therefore classified as T2N0M0 (Stage IIA, the American Joint Committee on Cancer 8th edition), indicating a tumor size between 2–5 cm (T2) with no regional lymph node involvement (N0) and no distant metastasis (M0).

The patient then underwent radical surgery with axillary fossa exploration using the sentinel lymph node technique using patent blue dye.

Final pathology confirmed the initial biopsy diagnosis and revealed no lymph node involvement (Figures 1-5). Surgical margins were clear. Subsequently, to achieve better local disease control, the patient was offered additional radiotherapy without chemotherapy.

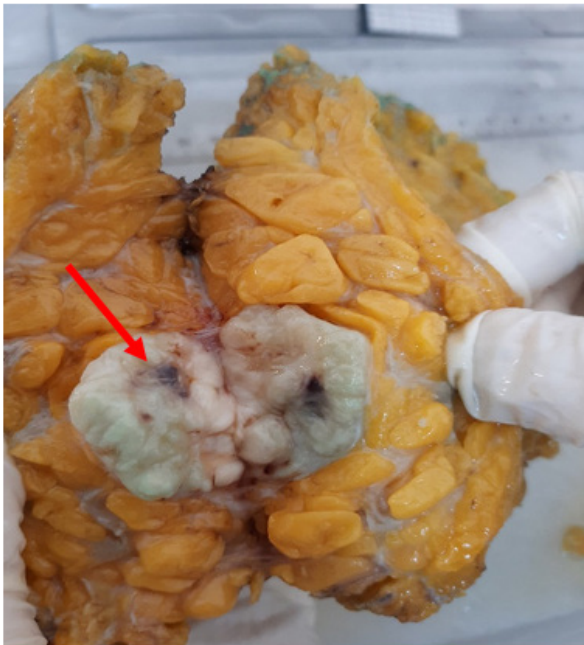


Figure 1. Macroscopic study of the mastectomy specimen with patent blue dye used for the exploration of the axillary fossa

After four years of follow-up, the patient remains free of local recurrence, distant metastasis, and treatment-related complications.

Discussion and Conclusion

A rare occurrence, primary sarcomas can develop in any organ, but their presence in the breast is exceptional, accounting for about 1% of breast tumors and less than 5% of all soft tissue sarcomas (1). A few isolated cases have been reported in the literature. A study by Amberger et al. (4), which compiled all documented cases, identified 68 cases between 1968 and 2017. This highlights the rarity of this pathology, complicating the study of its characteristics and the standardization of its management (Table 1).



Figure 2. Study of the specimen by a section through the nodule showing a 3 cm pearly white lesion (arrow) with healthy borders

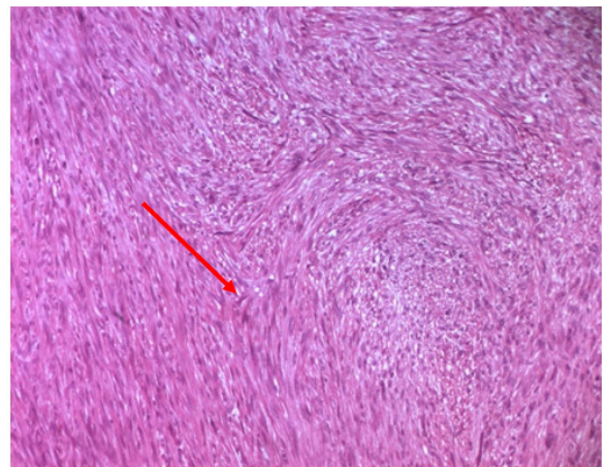


Figure 3. Microscopic study showing proliferation of elongated muscle fibers with round-ended nuclei with nuclear atypia of monstrosity type without epithelial proliferation (arrow) (hematoxylin and eosin stain $\times 40$)

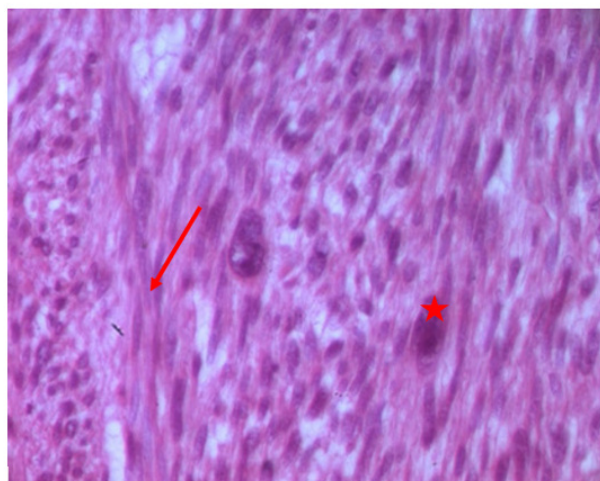


Figure 4. Microscopic study showing proliferation of elongated muscle fibers (arrow) with round-ended nuclei with nuclear atypia of monstrosity type without epithelial proliferation (asterisk) (hematoxylin and eosin stain ×400)

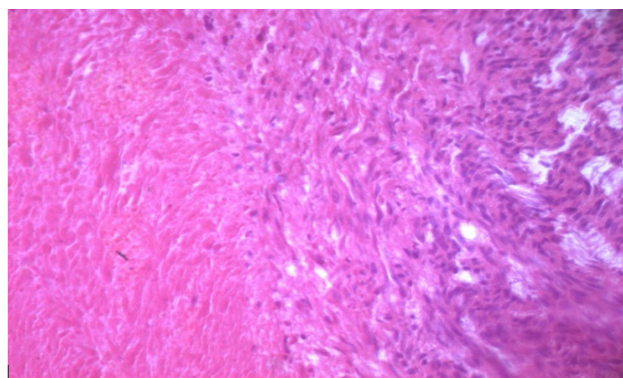


Figure 5. Microscopic study with hematoxylin and eosin stain ×100 showing a proliferation of muscle fibers with the presence of some mammary lobules in the middle of the lesion

Although primary sarcomas most commonly affect women during the first decade after menopause, cases in younger individuals have been reported, including at ages 20 Amberger et al. (4) and 24 Waterworth et al. (5). More recently, Masadah et al. (6) reported a 30-year-old female patient with a 12×8 cm breast leiomyosarcoma managed by wide local excision with 2 cm surgical margins, without the use of adjuvant therapy. At 8-month follow-up, there was no recurrence.

The most common reason for consultation is the detection of a large palpable mass, which may sometimes grow rapidly and be painful (7). At diagnosis, this is reflected in the mean size of the mass, which is 4 cm, with extremes ranging from 1.5 to 9 cm. These masses are typically well-circumscribed and mobile with respect to the pectoral muscle and the overlying skin (5). However, given the clinical and epidemiological diversity and rarity of this subtype of cancer, histopathological and immunohistochemical analysis remain the gold standard for diagnosis (8).

The treatment of primary breast leiomyosarcoma follows the same rules as those used in the treatment of soft tissue sarcomas. Surgical excision, either by breast-conserving surgery or mastectomy, is the cornerstone of treatment. While some studies suggest that wide local excision with negative margins may be sufficient, others advocate for mastectomy to minimize recurrence risk. Horton et al. (9) described a case of breast leiomyosarcoma treated successfully with lumpectomy and breast reduction surgery, with no recurrence at follow-up.

Since axillary lymph node metastases are not common in PBS, several authors do not recommend lymph node dissection as it does not affect prognosis and tends to increase the risk of morbidity from lymphedema.

Yet, because of the rarity of this disease and the limited number of studies to guide treatment decisions, the sentinel node technique is often performed to confirm the absence of lymph node involvement, as was the case in the presented patient (8).

Table 1. Summary of reported cases of primary breast leiomyosarcoma: Clinicopathological features, surgical approaches, and outcomes

Study	Years	Sex	Size (cm)	Approach	Margin width	Adjuvant radiotherapy	Adjuvant chemotherapy	Outcome	Follow-up
Masadah et al. (6) (2023)	30	Female	12*8	Wide local excision	2 cm	Not administered	Not administered	No recurrence	8 moths
Horton et al. (9) (2020)	61	Female	Not specified	Lumpectomy + breast reduction surgery	Not specified	Not administered	Not administered	No recurrence	Not specified
Amberger et al. (4) (2018)	44	Female	Rapidly increasing size	Chemotherapy followed by surgery	Not specified	Not specified	administred	Tumor progression	Metastases after 3 years
Waterworth et al. (5) (1992)	24	Female	Not specified	Mastectomy	Not specified	Not administred	Not administred	No recurrence	14 years
Zelek et al. (13) (2003)	37	Female	2.5	Wide local excision	Not specified	Not administred	Not administred	Tumor progression	Metastases after 20 years

The role of radiotherapy in the treatment of PBS remains controversial because of its rarity and the lack of randomized studies, but it is still the second most important therapeutic tool after surgery (10, 11). Zelek et al. (13) advocated an extrapolation of the principles of treatment of soft tissue sarcomas (12). Thus, they recommended adjuvant radiotherapy to improve the local control rate. However, the latter contributes to a better local control rate of breast sarcomas but does not improve the overall survival rate. In the absence of specific data for breast sarcoma, the indications for the use of adjuvant radiotherapy at this location should follow those of soft tissue sarcomas. Thus, the indications widely accepted in the literature are (10, 11):

- The high histological grade of the tumor
- A tumor diameter of more than 5 cm
- Clear surgical margins of less than 1 cm
- Conservative treatment

The role of adjuvant chemotherapy in the treatment of breast sarcoma is not currently well established. Indeed, a meta-analysis supported the role of adjuvant doxorubicin-based chemotherapy in improving the probability of recurrence-free survival, though without appreciable effect on overall survival (12). The role of adjuvant chemotherapy remains uncertain, with some studies suggesting a modest improvement in recurrence-free survival but no effect on overall survival (13). Chemotherapy is typically reserved for high-risk tumors (>5 cm, high histological grade, or metastatic disease) (14). The most commonly used agents are doxorubicin and ifosfamide (13, 15).

The occurrence of leiomyosarcoma metastases has been reported, most commonly involving the lungs, although cases of liver and brain metastases have been documented up to 20 years post-treatment (4). Masadah et al. (6) and Horton et al. (9) did not observe metastatic progression in their respective cases, reinforcing the notion that early-stage low-grade tumors may have a better prognosis.

In summary, despite the aggressive nature of leiomyosarcomas, the surgical management of this case followed established practices and proved effective, with a favorable clinical outcome. The presence of favorable prognostic factors-including tumor size <5 cm, intermediate grade, Ki-67 index of 15%, no lymphatic spread, and clear margins (>1 cm)-suggests a less aggressive progression. Given the rarity of this tumor, long-term follow-up and further studies remain crucial to optimize treatment strategies.

Ethics

Informed Consent: Written informed consent was obtained from the patient for publication of this case report.

Footnotes

Authorship Contributions

Surgical and Medical Practices: A.A., H.A., S.A., A.D., A.K., S.H., S.B., H.K.; Concept: A.A., H.A., A.K., S.H., S.B., H.K.; Design: A.A., H.A., A.D., A.K., S.H., H.K.; Data Collection or Processing: A.A., H.A., S.A.; Analysis or Interpretation: A.A., H.A., A.D., A.K., S.B., H.K.; Literature Search: A.A., H.A., S.A.; Writing: A.A., H.A.

Conflict of Interest: No conflict of interest was declared by the authors.

Financial Disclosure: The authors declared that this study received no financial support.

References

- Moore MP, Kinne DW. Breast sarcoma. *Surg Clin North Am.* 1996; 76: 383-392. (PMID: 8610270) [\[Crossref\]](#)
- Lim SZ, Selvarajan S, Thike AA, Nasir ND, Tan BK, Ong KW, et al. Breast sarcomas and malignant phyllodes tumours: comparison of clinicopathological features, treatment strategies, prognostic factors and outcomes. *Breast Cancer Res Treat.* 2016; 159: 229-244. (PMID: 27541020) [\[Crossref\]](#)
- Al-Benna S, Poggemann K, Steinau HU, Steintraesser L. Diagnosis and management of primary breast sarcoma. *Breast Cancer Res Treat.* 2010; 122: 619-626. (PMID: 20480227) [\[Crossref\]](#)
- Amberger M, Park T, Petersen B, Baltazar GA. Primary breast leiomyosarcoma with metastases to the lung in a young adult: case report and literature review. *Int J Surg Case Rep.* 2018; 47: 34-37. (PMID: 29705677) [\[Crossref\]](#)
- Waterworth PD, Gompertz RH, Hennessy C, Henry JA, Lennard TW. Primary leiomyosarcoma of the breast. *Br J Surg.* 1992; 79: 169-170. (PMID: 1555069) [\[Crossref\]](#)
- Masadah R, Anwar F, Nelwan BJ, Faruk M. Primary leiomyosarcoma of the breast: a case report and literature review. *Int J Surg Case Rep.* 2023; 106: 108290. (PMID: 37148719) [\[Crossref\]](#)
- Trent II JC 2nd, Benjamin RS, Valero V. Primary soft tissue sarcoma of the breast. *Curr Treat Options Oncol.* 2001; 2: 169-176. (PMID: 12057135) [\[Crossref\]](#)
- Stolnicu S, Moldovan C, Podoleanu C, Georgescu R. Mesenchymal tumors and tumor-like lesions of the breast: a contemporary approach review. *Ann Pathol.* 2015; 35: 15-31. (PMID: 25533916) [\[Crossref\]](#)
- Horton L, Wohlfeil M, Al-Kourainy N, Choi L. Rare case of primary leiomyosarcoma of the breast treated with wide local excision and planned cosmetic breast reduction surgery. *BMJ Case Rep.* 2020; 13: e236013. (PMID: 33257357) [\[Crossref\]](#)
- Brown AP, Gaffney DK, Macdonald OK. Malignant phyllodes tumor of the breast: is adjuvant radiotherapy necessary? In: Hayat MA, éditeur. *Methods of cancer diagnosis, therapy and prognosis: breast carcinoma* [Internet]. Dordrecht: Springer Netherlands; 2008. p. 625635. (Methods of Cancer Diagnosis, Therapy and Prognosis). [\[Crossref\]](#)
- Bousquet G, Confavreux C, Magné N, de Lara CT, Poortmans P, Senkus E, et al. Outcome and prognostic factors in breast sarcoma: a multicenter study from the rare cancer network. *Radiother Oncol.* 2007; 85: 355-361. (PMID: 18023492) [\[Crossref\]](#)
- Wang F, Jia Y, Tong Z. Comparison of the clinical and prognostic features of primary breast sarcomas and malignant phyllodes tumor. *Jpn J Clin Oncol.* 2015; 45: 146-152. (PMID: 25387733) [\[Crossref\]](#)
- Zelek L, Llombart-Cussac A, Terrier P, Pivot X, Guinebreteiere JM, Le Pechoux C, et al. Prognostic factors in primary breast sarcomas: a series of patients with long-term follow-up. *J Clin Oncol.* 2003; 21: 2583-2588. (PMID: 12829679) [\[Crossref\]](#)
- El Amine Elhadj O, Nasri M, Thabet S, Ben Hassouna J, Goucha A, Rahal K, et al. Sarcomes mammaires primitifs : à propos de 30 cas traités à l'institut Salah-Azaiez de Tunis [primary breast sarcomas: about 30 cases treated at Salah-Azaiez institute in Tunisia]. *Cancer Radiother.* 2017; 21: 45-50. French. (PMID: 28223032) [\[Crossref\]](#)
- Brain EC, Mita A, Soulié P, Errihani H, Hardy Bessard AC, Chaouche M, et al. 6-day continuous infusion of high-dose ifosfamide with bone marrow growth factors in advanced refractory malignancies. *J Cancer Res Clin Oncol.* 1997; 123: 227-231. (PMID: 9177496) [\[Crossref\]](#)