



Efficacy of the Radiofrequency Identification Technique in Breast Cancer Patients: A Single Institution Retrospective Study

Mahmoud Kassem¹, Ahmed Kamr², Creighton B. Wright³, Anna P. Sobolewski¹

¹Department of Surgery, Mercy Health West Hospital, Cincinnati, USA

²College of Veterinary Medicine, The Ohio State University, Columbus, USA

³School of Health Science, Mount St. Joseph University, Cincinnati, USA

ABSTRACT

Objective: Breast conserving surgery is an excellent option in the treatment of breast cancer. To achieve a good result with this modality, a surgeon needs to identify and excise the tumor with adequate margins. The radiofrequency identification (RFID) technique is a wireless localization technique used for intraoperative breast lesion identification. We assessed the efficacy and outcomes of the RFID technique in breast cancer patients at our institution.

Materials and Methods: This is a single institution, retrospective study (BSMH 22-02X-MWH) of 73 patients. We analyzed the medical records of women with biopsy-proven breast cancer from June 2020 to August 2022; participants received surgical care at Mercy Health West Hospital. Data collected included demographics, clinicopathological characteristics, and surgical procedure. The primary objective was to determine the safety and efficacy of RFID. The secondary objective was to assess the impact of obesity and breast density on the RFID outcomes.

Results: A total of 73 female patients met the eligibility criteria with stage I (59%) and grade I (51%) breast cancer with mean age of at diagnosis of 66.8 years and mean body mass index of 31.4 kg/m². Patients had invasive ductal carcinoma (61%), hormonal positive (56%), and human epidermal growth factor receptor 2 negative (68%) disease. All RFID tags were placed under image guidance with 100% accuracy of placement with no evidence of migration or procedure revision. Ninety percent of patients had free surgical margins and only seven patients needed margin re-excision with successful removal of the lesion and the tag.

Conclusion: RFID localization technique is a safe, effective and reliable procedure that results in favorable patient outcomes and quality of life.

Keywords: Breast cancer; breast conserving surgery; RFID technique; localization techniques

Cite this article as: Kassem M, Kamr A, Wright CB, Sobolewski AP. Efficacy of the Radiofrequency Identification Technique in Breast Cancer Patients: A Single Institution Retrospective Study. Eur J Breast Health 2024; 20(1): 52-56

Key Points

- Safety and efficacy of RFID technique in treatment of breast cancer.
- Feasibility of breast conservative surgery using RFID technique.
- Decreasing unnecessary excision of breast tissue.

Introduction

Breast cancer is the most frequently diagnosed cancer in females and accounts for the second highest number of cancer-related deaths in women (1). In 2021, The American Cancer Society estimated that 30% of the anticipated cancer incidence among women would be breast malignancy (2). Surgical treatment of breast cancer is either mastectomy or breast-conserving surgery (BCS) and it has been shown that there are no significant differences in the outcome (3, 4). Due to the expansion in radiological techniques and breast cancer

screening, one-third of breast cancers are not palpable during physical examination (5). Pinpoint localization of the breast mass is one of the most important factors that determines the success of BCS (3). Numerous studies have demonstrated the advantages and disadvantages of different methods of breast mass localization. The wire-guided localization (WL) technique was the only preferable technique for non-palpable breast masses; however, this method has some complications such as infection, wire transection, migration, patient discomfort, and interference with surgical approach (6-8). A novel technique has been developed to overcome some of the potential complications.

In 2017, The radiofrequency identification (RFID) technique was given approval by the US Food and Drug Administration (FDA). Simply, a radiofrequency tag is placed under radiographic image guidance one week preoperatively, allowing the tag to set in place and determine the optimal surgical approach. The primary objective of our study was to determine the safety and efficacy of RFID. The secondary objective was to determine the impact of obesity and breast density on RFID outcomes.

Materials and Methods

Study Design

This study was an IRB-approved (BSMH 22-02X-MWH) retrospective chart review of clinical and histopathological data from female patients ≥ 18 years of age, with biopsy-proven stage 0-IV breast cancer who underwent BCS using LOCALIZER RFID and were seen at Mercy Health West Hospital between June 2020 and August 2022. Patients with incomplete clinical data and those treated at other institutions were excluded.

Data Collection

Data were obtained from the BSMH EPIC system and uploaded into a secured database. Any missing data was populated using manual review of each patient's electronic medical record. Data were collected on demographic characteristics, biomarker profiles including estrogen receptor (ER), prolactin receptor (PR), and human epidermal growth factor receptor 2 (HER2) positivity of the tumor, therapy modalities (surgery and radiotherapy), disease recurrence, and survival outcomes.

Statistical Analysis

Demographic and clinical characteristics, and treatment modalities were summarized using descriptive statistics. All data analyses were performed using IBM SPSS statistics, version 28 (IBM Corp., Armonk, NY, USA). Operative time and re-excision rate were assessed by independent t-test. Significance was assumed when $p < 0.05$.

Surgical Technique

Preoperative: All cases with positive mammographic findings and biopsy-proven breast cancer underwent the RFID tag placement following The National Comprehensive Cancer Network guidelines. One week pre-operatively, the radiologist placed the RFID tag under image guidance using a local anesthetic. The RFID tag dimensions are 11-mm long and 2 mm in diameter (Figure 1). Each tag includes a distinctive identification number (Figure 2) and a polypropylene cap to protect against migration. Placing the tag involves making a 2-mm incision in the skin before inserting the applicator.

Intraoperative: Using a handheld reader, the LOCALIZER™ RFID (Hologic, Inc., Marlborough, MA, USA) (Figure 3), the surgeon can identify the tag with safe and accurate lesion removal with adequate margin. Intraoperative radiograph of the specimen was done to confirm removal of the tag, biopsy clip, and the lesion (Figure 4).

Results

A total of 73 patients with biopsy-proven breast cancer stage 0-IV were included. Patient demographic and clinical characteristics are summarized in Table 1. Patients were predominantly white (80%) and postmenopausal (67%) with a median age of 66 years (range 30-91) and mean body mass index (BMI) of 31.4 kg/m² (median 30.26 kg/m²; range 20-49) at diagnosis. The right breast was the predominant

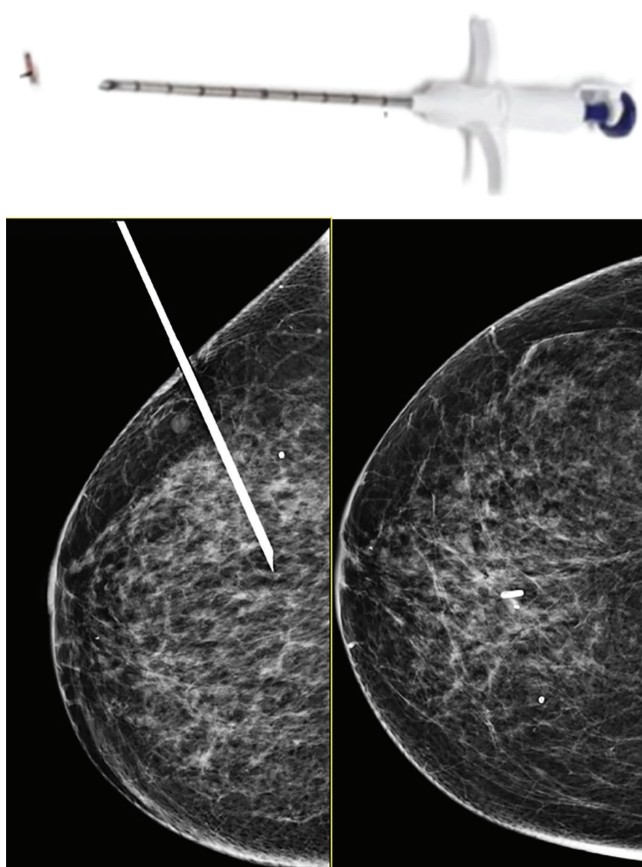


Figure 1. Tag applicator with mammography showing its placement

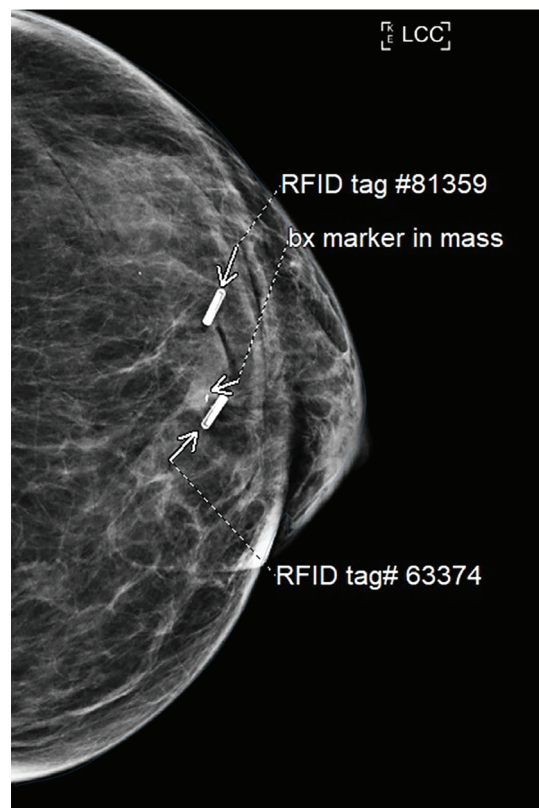


Figure 2. Mammography of the breast tissue showing the RFID tags with its identification numbers

RFID: Radiofrequency identification

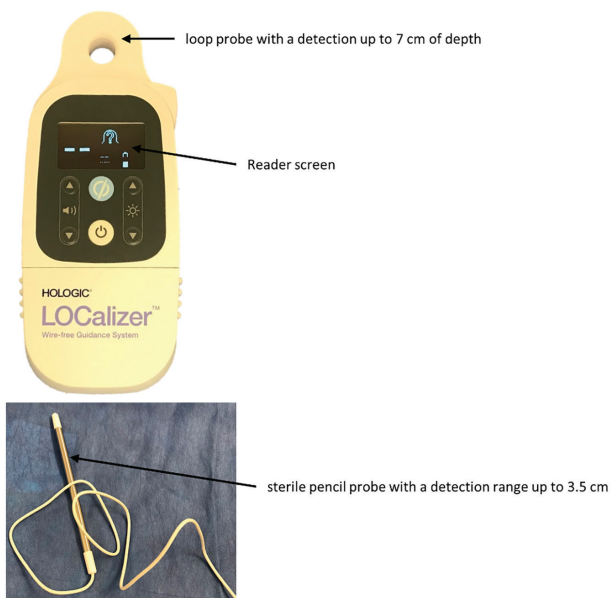


Figure 3. Handheld RFID hologic localizer (reader and detection probe)

RFID: Radiofrequency identification




Figure 4. Intraoperative X-ray radiograph showing successful retrieval of the mass and the tags

cancer site in our cohort (59%). The mean size of the mass was 12.3 mm (range 2–58 mm). The majority of the excisions were for invasive ductal carcinoma (44%) which was stage I (59%), grade 1 (51%) and ten were node positive (14%). Biomarker evaluation revealed that 86% of patients were ER positive, 5% of patients were positive for HER-2, and 7% had triple negative breast cancer. Only six patients (8%) received neoadjuvant chemotherapy, three (50%) of them had pathological complete response. The mean operative time was 58.8±28.7 minutes. Postoperative pathology discussion revealed that 10% of patients required margin re-excision with no patient required completion mastectomy Table 2. The independent t-test found that

Table 1. Patients demographics and clinical characteristics

Variable	Total (n = 73)
Median (range) age at diagnosis, years	66.8 (30–91)
Gender	Female 73 (100%)
Menopausal status	Postmenopausal 67 (92%) Premenopausal 6 (8%)
BMI, kg/m²	≥30 38 (52%) <30 35 (48%)
Ethnicity	White 58 (80%) African American 14 (19%) Asian 1 (1%)
Laterality	Right 43 (59%) Left 30 (41%)
Stage (clinical)	Stage 0 23 (32%) Stage I 43 (59%) Stage II 2 (3%) Stage III 4 (5%) Stage IV 1 (1%)
Histological subtypes	DCIS 21 (29%) IDC 44 (61%) ILC 3 (4%) LCIS 1 (1%) Mucinous 2 (3%) Papillary 1 (1%) Metaplastic 1 (1%)
Grade	1 37 (51%) 2 22 (30%) 3 14 (19%)
Tumor size	≥2 cm 9 (12%) <2 cm 64 (88%)
Biomarker status	Positive 63 (86%) Negative 10 (14%)
Estrogen receptor	Positive 43 (59%) Negative 9 (12%)
Progesterone receptor	Unknown 21 (29%) Positive 4 (5%) Negative 48 (68%)
HER-2	Unknown 21 (29%) Yes 10 (14%) No 63 (86%)
Nodal involvement	B: Scattered areas of fibro-glandular density 27 (37%) C: Heterogeneously dense 43 (59%) D: Extremely dense 3 (4%)
Breast density	
Mean ± SD operative time, minutes	58.8±28.7

SD: Standard deviation; BMI: Body mass index; HER2: Human epidermal growth factor receptor 2; DCIS: Ductal carcinoma *in situ*; IDC: Invasive ductal carcinoma; ILC: Invasive lobular carcinoma; LCIS: Lobular carcinoma *in situ*

there was no significant difference in the technique outcomes between patient with high BMI ($\geq 30 \text{ kg/m}^2$) and lower BMI ($< 30 \text{ kg/m}^2$) ($p = 0.5$). Furthermore, there was no significant difference in the outcomes in different types of breast density ($p = 0.2$). However, patients with higher BMI and heterogeneously dense breast had some postoperative adverse events, such as hematoma and seroma (8%).

Discussion and Conclusion

Several studies have established that BCS has the same survival outcomes compared to simple and modified radical mastectomy, as well as improved cosmetic outcomes (9-11). A positive surgical margin is the presence of any invasive or *in-situ* tumor on the surgical specimen, as defined by the surgical practice guidelines. Therefore, the most crucial step in BCS is obtaining a negative margin that will decrease the recurrence rate and contribute to successful cancer treatment (12-14). In order to obtain a successful BCS, you must determine the mass boundaries with adequate margins around it. Consequently, multiple methods of localization have emerged to accomplish the clear margin. The WL technique was the gold standard since its description in the 1970s. However, its limitations as highlighted earlier opened the space to develop alternative wireless localization techniques (15). The first attempt was radioactive seed localization (RSL) but its limitations were found in the extra requirements for handling the radioactive materials and arrangement of the combination of surgical and radiological appointments (16). A randomized prospective evaluation of RSL and WL determined that there were no significant differences as regard the re-excision of positive margin (26% vs 57%) and the operative excision (5.4 vs 6.1 minutes) (17). In 2016, the FDA approved another technique, Magseed, which was based on recognition of a ferromagnetic seed using the Sentimag, a handheld magnetometer. When compared to the WL in a single institution, randomized controlled trial, the Magseed had the advantage in terms of overall patient satisfaction ($p < 0.001$) and surgical usability score (70.2 ± 8.9 vs. 58.1 ± 9.1 , $p < 0.001$). However, this technique has its limitation such as other ferromagnetic materials should be totally cleared from the operative field while using the magnetometer because it might interfere with seed localization (18-20). The RFID technique has been reported to be superior to the other techniques, such as wire localization, radioactive seeds, and cryo-assisted localization due to its wireless advance, absence of radioactive material, and feasibility of surgery scheduling (6, 19). Our findings are compatible with other studies investigating RFID technique outcomes. A recent study done by Lowes et al. (21) demonstrated that the re-excision rate was 8.7% with successful placement of the tags in all cases. Recently, two wireless methods have been developed for identification of breast masses but are still under investigation. SAVI SCOUT[®] radar localization has the limitation of its interaction with electrocautery, which can disturb the signal or deactivate the reflector. The magnetic marker implantation (Magseed) requires special instruments during the procedure that do not interfere with the marker detection (22-25). In contrast, the RFID technique is more reliable and does not have these limitations. Although, as determined by McGugin et al. (26), the operative time was higher in patients with ductal carcinoma *in situ* (DCIS), our study demonstrated that there was no significance difference in the operative time between invasive cancer and DCIS ($p = 0.4$) (Figure 5). A recent study by Christenhusz et al. (27), found that the breast density interfered with tag placement, especially type C and D densities. However, in our study, there was 100% successful tag placement and localization with no evidence of migration, regardless of the breast density and patient BMI.

Table 2. Margin re-excision for different histological types

Variable	Category	Number of patients (%) n = 73
Margin re-excision (n=7)	DIC	2 (2.7%)
	IDC	2 (2.7%)
	ILC	1 (1.4%)
	LCIS	1 (1.4%)
	Metaplastic carcinoma	1 (1.4%)

DCIS: Ductal carcinoma *in situ*; IDC: Invasive ductal carcinoma; ILC: Invasive lobular carcinoma; LCIS: Lobular carcinoma *in situ*

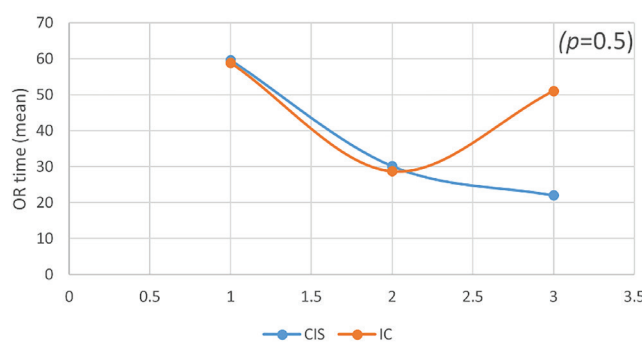


Figure 5. Plot graph of the odds ratio time for the Invasive and *in-situ* carcinoma

Study Limitations

Potential limitations of our study include being a retrospective study, having a small sample size, and being a single institution study.

To summarize, preoperative localization of breast lesion is an important factor in successful breast conserving surgery. In this study the RFID technique was shown to have favorable efficacy and safety margin rates among alternative localization techniques.

Acknowledgements

The authors would like to thank Theresa Hageman for her assistance in the preparation and editing of this manuscript.

Ethics Committee Approval: Ethics committee approval was received for this study from the Ethics Committee of Bon Secours Mercy Health (BSMH 22-02X-MWH, date: 07.04.2023).

Informed Consent: Retrospective study.

Peer-review: Externally and internally peer-reviewed.

Authorship Contributions

Surgical and Medical Practices: M.K., A.K., C.B.W., A.P.S.; Concept: M.K., A.P.S.; Design: M.K., A.P.S.; Data Collection and/or Processing: M.K.; Analysis and/or Interpretation: M.K., A.K.; Literature Search: M.K., A.K., A.P.S.; Writing: M.K., A.K., C.B.W., A.P.S.

Conflict of Interest: The authors have no conflicts of interest to declare.

Financial Disclosure: The authors declared that this study has received no financial support.

References

- Bray F, Soerjomataram I. The Changing Global Burden of Cancer: Transitions in Human Development and Implications for Cancer Prevention and Control. In: Gelband H, Jha P, Sankaranarayanan R, Horton S, editors. *Cancer: Disease Control Priorities, 3rd*. Washington (DC): 2015. <https://www.ncbi.nlm.nih.gov/books/NBK343643/> [Crossref]
- Siegel RL, Miller KD, Fuchs HE, Jemal A. Cancer statistics, 2022. *CA Cancer J Clin* 2022; 72: 7-33. (PMID: 35020204) [Crossref]
- Fisher B, Anderson S, Bryant J, Margolese RG, Deutsch M, Fisher ER, et al. Twenty-year follow-up of a randomized trial comparing total mastectomy, lumpectomy, and lumpectomy plus irradiation for the treatment of invasive breast cancer. *N Engl J Med* 2002; 347: 1233-1241. (PMID: 12393820) [Crossref]
- Veronesi U, Cascinelli N, Mariani L, Greco M, Saccozzi R, Luini A, et al. Twenty-year follow-up of a randomized study comparing breast-conserving surgery with radical mastectomy for early breast cancer. *N Engl J Med* 2002; 347: 1227-1232. (PMID: 12393819) [Crossref]
- Lovrics PJ, Cornacchi SD, Farrokhyar F, Garnett A, Chen V, Franic S, et al. The relationship between surgical factors and margin status after breast-conservation surgery for early stage breast cancer. *Am J Surg* 2009; 197: 740-746. (PMID: 18789424) [Crossref]
- Chan BK, Wiseberg-Firtell JA, Jois RH, Jensen K, Audisio RA. Localization techniques for guided surgical excision of non-palpable breast lesions. *Cochrane Database Syst Rev* 2015; 2015: CD009206. (PMID: 26718728) [Crossref]
- De Cicco C, Pizzamiglio M, Trifirò G, Luini A, Ferrari M, Prisco G, et al. Radioguided occult lesion localisation (ROLL) and surgical biopsy in breast cancer. Technical aspects. *Q J Nucl Med* 2002; 46: 145-151. (PMID: 12114878) [Crossref]
- Van Esser S, Hobbelink M, Van der Ploeg IM, Mali WP, Van Diest PJ, Borel Rinkes IH, et al. Radio guided occult lesion localization (ROLL) for non-palpable invasive breast cancer. *J Surg Oncol* 2008; 98: 526-529. (PMID: 18767074) [Crossref]
- Johns N, Dixon JM. Should patients with early breast cancer still be offered the choice of breast conserving surgery or mastectomy? *Eur J Surg Oncol* 2016; 42: 1636-1641. (PMID: 27665053) [Crossref]
- van Maaren MC, de Munck L, de Bock GH, Jobsen JJ, van Dalen T, Linn SC, et al. 10 year survival after breast-conserving surgery plus radiotherapy compared with mastectomy in early breast cancer in the Netherlands: a population-based study. *Lancet Oncol* 2016; 17: 1158-1170. (PMID: 27344114) [Crossref]
- van Maaren MC, Strobbe LJA, Koppert LB, Poortmans PMP, Siesling S. Nationwide population-based study of trends and regional variation in breast-conserving treatment for breast cancer. *Br J Surg* 2018; 105: 1768-1777. (PMID: 30091459) [Crossref]
- Buchholz TA, Somerfield MR, Griggs JJ, El-Eid S, Hammond ME, Lyman GH, et al. Margins for breast-conserving surgery with whole-breast irradiation in stage I and II invasive breast cancer: American Society of Clinical Oncology endorsement of the Society of Surgical Oncology/American Society for Radiation Oncology consensus guideline. *J Clin Oncol* 2014; 32: 1502-1506. (PMID: 24711553) [Crossref]
- Moran MS, Schnitt SJ, Giuliano AE, Harris JR, Khan SA, Horton J, et al. consensus guideline on margins for breast-conserving surgery with whole-breast irradiation in stages I and II invasive breast cancer. *Int J Radiat Oncol Biol Phys* 2014; 88: 553-564. (PMID: 24521674) [Crossref]
- Wang J, Deng JP, Sun JY, Dong Y, Zhang WW, He ZY, et al. Noninferior Outcome After Breast-Conserving Treatment Compared to Mastectomy in Breast Cancer Patients With Four or More Positive Lymph Nodes. *Front Oncol* 2019; 9: 143. (PMID: 30931256) [Crossref]
- Cheang E, Ha R, Thornton CM, Mango VL. Innovations in image-guided preoperative breast lesion localization. *Br J Radiol* 2018; 91: 20170740. (PMID: 29271240) [Crossref]
- Jakub J, Gray R. Starting a Radioactive Seed Localization Program. *Ann Surg Oncol* 2015; 22: 3197-3202. (PMID: 26254168) [Crossref]
- Gray RJ, Salud C, Nguyen K, Dauway E, Friedland J, Berman C, et al. Randomized prospective evaluation of a novel technique for biopsy or lumpectomy of nonpalpable breast lesions: radioactive seed versus wire localization. *Ann Surg Oncol* 2001; 8: 711-715. (PMID: 11597011) [Crossref]
- Gera R, Tayeh S, Al-Reefy S, Mokbel K. Evolving Role of Magseed in Wireless Localization of Breast Lesions: Systematic Review and Pooled Analysis of 1,559 Procedures. *Anticancer Res* 2020; 40: 1809-1815. (PMID: 32234869) [Crossref]
- Hayes MK. Update on Preoperative Breast Localization. *Radiol Clin North Am* 2017; 55: 591-603. (PMID: 28411682) [Crossref]
- Struik GM, Schermers B, Mares I, Lont HE, Bradshaw JW, Ten Haken B, et al. Randomized controlled trial comparing magnetic marker localization (MaMaLoc) with wire-guided localization in the treatment of early-stage breast cancer. *Breast J* 2021; 27: 638-650. (PMID: 34142409) [Crossref]
- Lowes S, Bell A, Milligan R, Amonkar S, Leaver A. Use of Hologic LOCALizer radiofrequency identification (RFID) tags to localise impalpable breast lesions and axillary nodes: experience of the first 150 cases in a UK breast unit. *Clin Radiol* 2020; 75: 942-949. (PMID: 32919756) [Crossref]
- Cox CE, Russell S, Prowler V, Carter E, Beard A, Mehindru A, et al. A Prospective, Single Arm, Multi-site, Clinical Evaluation of a Nonradioactive Surgical Guidance Technology for the Location of Nonpalpable Breast Lesions during Excision. *Ann Surg Oncol* 2016; 23: 3168-3174. (PMID: 27469121) [Crossref]
- Falcon S, Weinfurter RJ, Mooney B, Niell BL. SAVI SCOUT® localization of breast lesions as a practical alternative to wires: Outcomes and suggestions for trouble-shooting. *Clin Imaging* 2018; 52: 280-286. (PMID: 30193186) [Crossref]
- Srouf MK, Kim S, Amersi F, Giuliano AE, Chung A. Comparison of wire localization, radioactive seed, and Savi scout® radar for management of surgical breast disease. *Breast J* 2020; 26: 406-413. (PMID: 31448530) [Crossref]
- Zacharioudakis K, Down S, Bholah Z, Lee S, Khan T, Maxwell AJ, et al. Is the future magnetic? Magseed localisation for non palpable breast cancer. A multi-centre non randomised control study. *Eur J Surg Oncol* 2019; 45: 2016-2021. (PMID: 31288944) [Crossref]
- McGugin C, Spivey T, Coopey S, Smith B, Kelly B, Gadd M, et al. Radiofrequency identification tag localization is comparable to wire localization for non-palpable breast lesions. *Breast Cancer Res Treat* 2019; 177: 735-739. (PMID: 31302856) [Crossref]
- Christenhusz A, den Dekker BM, van Dalen T, Jongen L, van der Schaaf MC, Alic L, et al. Radiofrequency localization of nonpalpable breast cancer in a multicentre prospective cohort study: feasibility, clinical acceptability, and safety. *Breast Cancer Res Treat* 2023; 201: 67-75. (PMID: 37322358) [Crossref]