



Breast Hemangioma Evaluation with Magnetic Resonance Imaging: A Rare Case Report

Özge Aslan¹, Ayşenur Oktay¹, Gürdeniz Serin², Levent Yeniay³, Orkhan Aghamirzayev¹

¹Department of Radiology, Ege University Faculty of Medicine, İzmir, Turkey

²Department of Medical Pathology, Ege University Faculty of Medicine, İzmir, Turkey

³Department of General Surgery, Ege University Faculty of Medicine, İzmir, Turkey

ABSTRACT

Vascular tumors are rare in the breasts, and the most common forms include hemangiomas and angiosarcomas. Hemangiomas are rare benign vascular tumors. Most of them are asymptomatic and nonpalpable clinically, and the vast majority of such lesions are detected incidentally by mammography. Breast hemangiomas are difficult to diagnose using conventional imaging modalities since their imaging findings are variable. The following is a case presentation of an asymptomatic forty-five-year old female patient who was diagnosed with a rare hemangioma. Physical examination, ultrasonography (US) and mammographic examination were normal. Dynamic contrast enhanced magnetic resonance imaging (MRI) showed a non-mass pathological enhancement. After a short-term follow up, a comparative MRI was obtained and biopsy was planned, due to the heterogeneous non-mass enhancement on MRI. Needle core biopsy with US guidance was performed, resulting in benign findings. However, because of the discordance between imaging and histopathology, an MRI-guided wire localization followed by open surgical biopsy was performed. Histopathologic evaluation reported capillary hemangioma. The imaging findings, including US, mammography and MRI, of hemangioma are reviewed and described in this case report.

Keywords: Breast; hemangioma; angiosarcoma; MRI

Cite this article as: Aslan Ö, Oktay A, Serin G, Yeniay L, Aghamirzayev O. Breast Hemangioma Evaluation with Magnetic Resonance Imaging: A Rare Case Report. Eur J Breast Health 2022; 18(2): 190-194

Key Points

- Benign hemangiomas can occur in the breast parenchyma and are usually small and incidentally found on excisional biopsy for other lesions.
- Hemangiomas are rare benign vascular tumors.
- Differential diagnosis of any type of hemangioma within the breast should be well-differentiated angiosarcoma.
- Due to the potential malignancy risk in vascular breast tumors, surgical excision is recommended in all cases of breast hemangioma.

Introduction

Vascular tumors are rare in the breasts, and the most common forms include angiosarcomas and hemangiomas. Hemangiomas are usually seen in adult women at any age (19 to 82 years with a mean of 60 years) (1). Hemangiomas are usually found incidentally through imaging techniques, including mammography, ultrasonography (US) or magnetic resonance imaging (MRI) (2).

In this case, the breast hemangioma was not visible on US or mammography and could not be differentiated from malignancy with MRI, eventually requiring open biopsy.

Case Presentation

A 45-year-old female patient was referred to our clinic for evaluation of MRI taken at another hospital. There was a weak heterogeneous nonmass contrast enhancement in the upper inner quadrant of the right breast on dynamic, contrast-enhanced MRI (Figures 1 and 2).

She had no previous history of breast-related problems, radiation treatment, or family history of breast or ovarian cancer. The only complaint was breast pain, and there was no skin color change and no finding on physical examination of the breasts. Mammography and ultrasonography were performed at our clinic. There was a mass opacity in the upper outer quadrant on the mammograms, which was confirmed as a cyst on US.

Corresponding Author:
Özge Aslan; dr.ozgeaslan@gmail.com

Received: 20.10.2020
Accepted: 30.01.2021
Available Online Date: 01.04.2022

No suspicious finding was present in the inner upper quadrant either with mammography and US (Figure 3).

A follow-up appointment was scheduled for three months later. Craniocaudal (CC) view mammogram and US of the right breast were negative. Therefore, follow-up MRI was performed using a 3-T MR imaging unit (Siemens MAGNETOM® Verio) with the patient prone and breast positioned within a dedicated surface breast coil with seven-channels. The MRI images were acquired using the following sequences: axial, fat-suppressed, and fast spin-echo T2-weighted imaging sequence and pre-contrast and post-contrast dynamic axial T1-weighted three-dimensional, fat-suppressed, fat-spoiled, gradientecho sequence.

The images were obtained before and after a rapid bolus injection of gadolinium- diethylenetriamine penta acetic acid (Magnevist; Schering, Berlin, Germany) at 0.1 mmol/kg of body weight.

In the early phase of dynamic contrast MRI, a non-mass heterogeneous pathologic enhancement, 4 cm in size, was seen in this area. The enhancement was continued and the finding was more evident from the previous MRI in the delayed phase with type 2 kinetic curve (Figure 4). It was categorized as Breast Imaging Reporting and Data System (BI-RADS) 4.

An US-guided core biopsy was performed, using the coordinates of the lesion obtained with MRI, which resulted in benign histopathological findings of fibrocystic changes of the breast and sclerosing adenosis.

Due to the discordance between radiology and pathology results, we recommended a second biopsy with MRI guidance. The patient requested surgical examination and so we performed an MRI-guided hook wire localization followed by open biopsy (Figure 5a). Once the lesion was localized, the MRI-compatible guide hook wire was introduced to the appropriate depth. After the appropriate location and depth was confirmed, a guide wire was deployed through the needle.

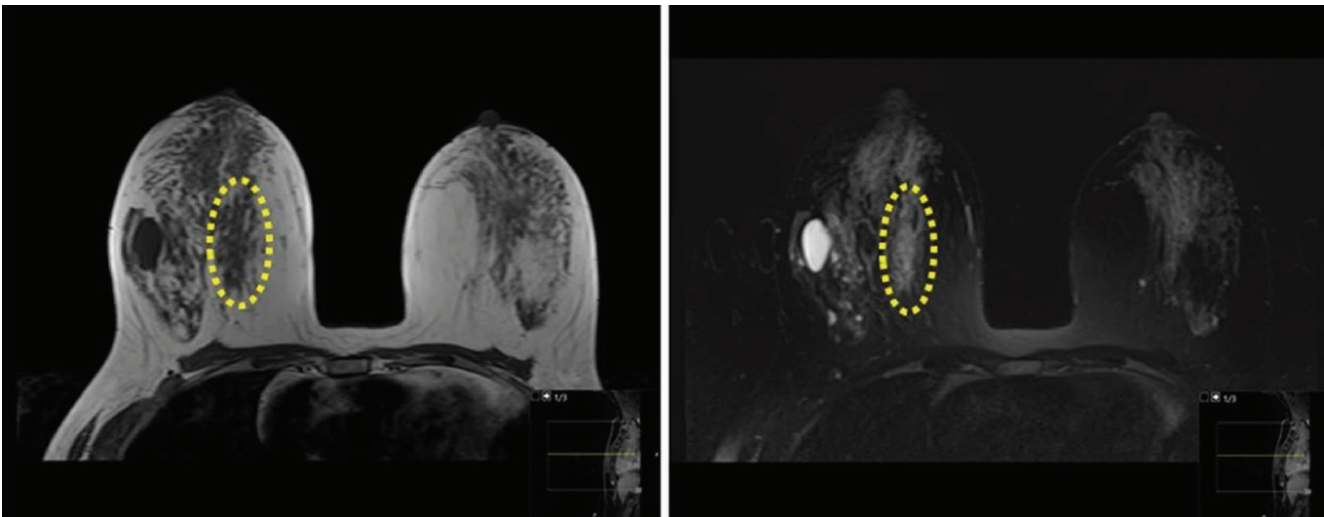


Figure 1. T1W and T2W MRI ; the circle indicates asymmetric tissue in the upper inner quadrant of the right breast that was isointense with breast tissue on T1W MRI and slightly hyperintense on T2W MR image

MRI: magnetic resonance imaging

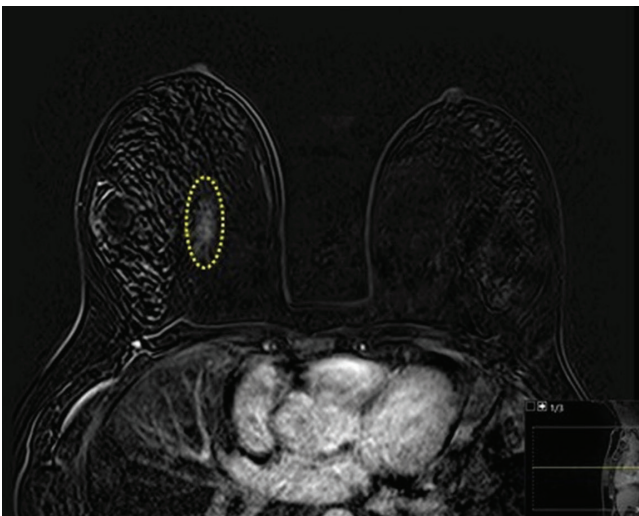


Figure 2. Dynamic, contrast-enhanced MRI subtracted image showing a weak non-mass enhancement in the upper inner quadrant of right breast

MRI: magnetic resonance imaging

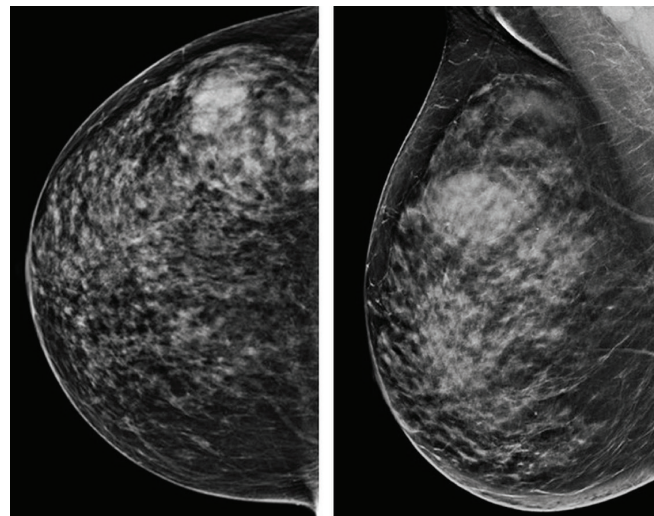


Figure 3. On US, there was a mass opacity of a cyst in the upper outer quadrant of the right breast; there were no suspicious findings in the inner quadrant on mammography images

US: ultrasonography

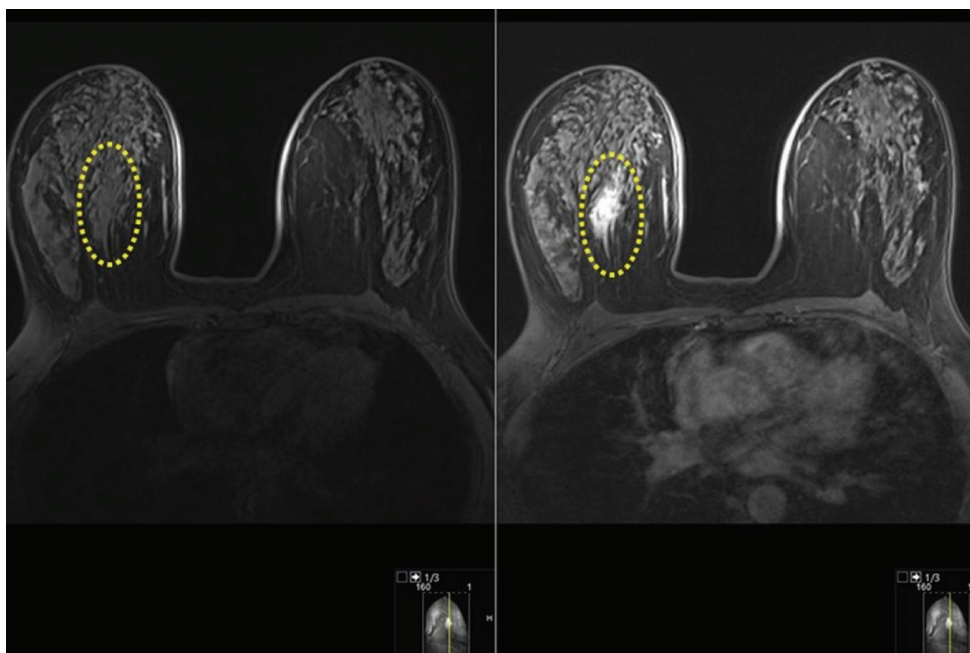


Figure 4. On pre-contrast T1W MRI, there was a 4 cm hypointense asymmetric lesion with irregular borders in the upper inner quadrant of the right breast. On postcontrast T1W image non-mass enhancement was seen which became more evident at a subsequent follow-up three months later

MRI: magnetic resonance imaging

After MRI, a mammogram was taken in the CC position in order to understand the location and depth of the wire and to show its interference with the surrounding tissue and nipple. After the excision, a specimen mammography was taken (Figure 5b).

On macroscopic evaluation of excision material, there was an irregularly circumscribed lesion (Figure 6). Histopathological evaluation revealed numerous vascular spaces, randomly distributed within the breast tissue, with no sign of anastomosis (Figures 7a and 7b).

Immunohistochemical study showed positive staining for endothelial markers such as CD31 and ERG in vascular spaces scattered between normal breast ducts (Figure 8). Final histopathological diagnosis of the lesion was capillary hemangioma.

Discussion and Conclusion

Benign vascular breast lesions, including hemangioma and angiomatosis, are rare (1). Angiosarcoma, which is one of the malignant vascular tumors and is usually a very aggressive tumor, is less common than the benign vascular tumors (1). In the literature, there is no evidence that benign vascular tumors, with or without atypia, are later upgraded to angiosarcoma (3, 4). However, when hemangioma is detected by needle biopsy, surgical excision is preferred because the sample taken may coincide with the well-differentiated area of a possible underlying angiosarcoma (1). Thus, it is clearly very important to be able to make the differential diagnosis of hemangioma and angiosarcoma.

Breast hemangiomas have variable imaging features (5). Benign hemangiomas can occur in the breast parenchyma and are usually small and incidentally found on excisional biopsy for other lesions (4, 6). Most common types are capillary and cavernous hemangioma (7).

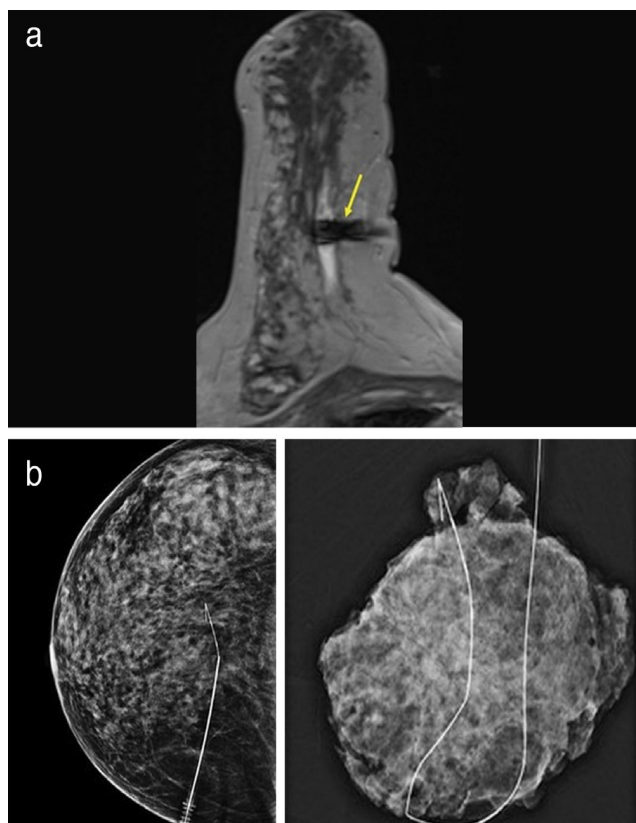


Figure 5. a) Susceptibility artefact of the hook wire is seen in the lesion on axial dynamic contrast enhanced T1W images. **b)** Mammography shows location of the hook wire system and specimen mammography shows the excised area with the wire

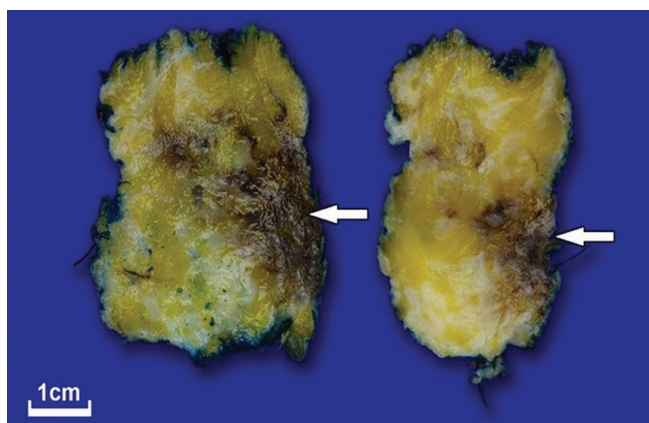


Figure 6. Macroscopic view of an irregularly demarcated lesion, 4.0 x 1.8 cm, with a hemorrhagic cross-sectional surface, abutting the margin of the surgical excision, in serial sections of partial mastectomy material

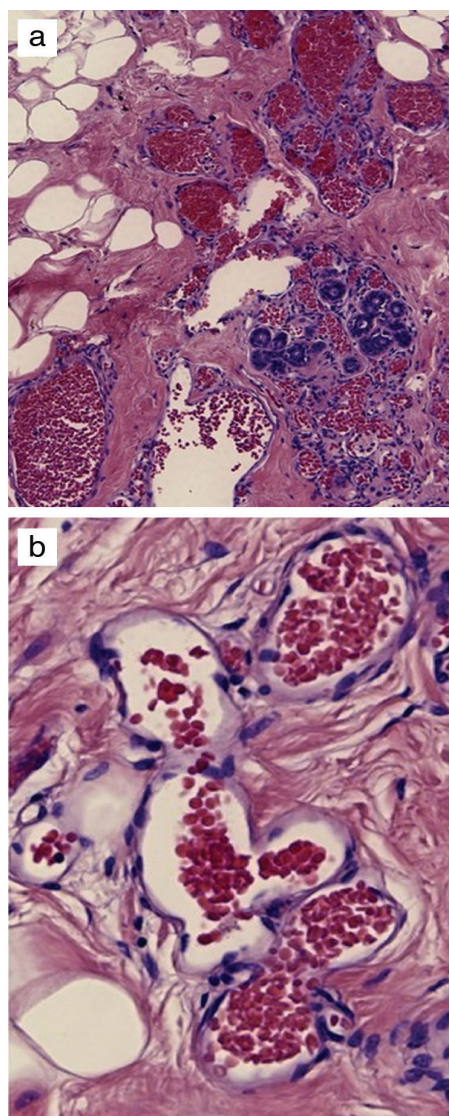


Figure 7. a) Vascular spaces scattered around the breast ducts, without significant anastomosis, containing erythrocytes (hematoxylin & eosin, 200x). b) Vascular spaces lined with a single layer of endothelium without signs of proliferation or atypia (hematoxylin & eosin, 400x).

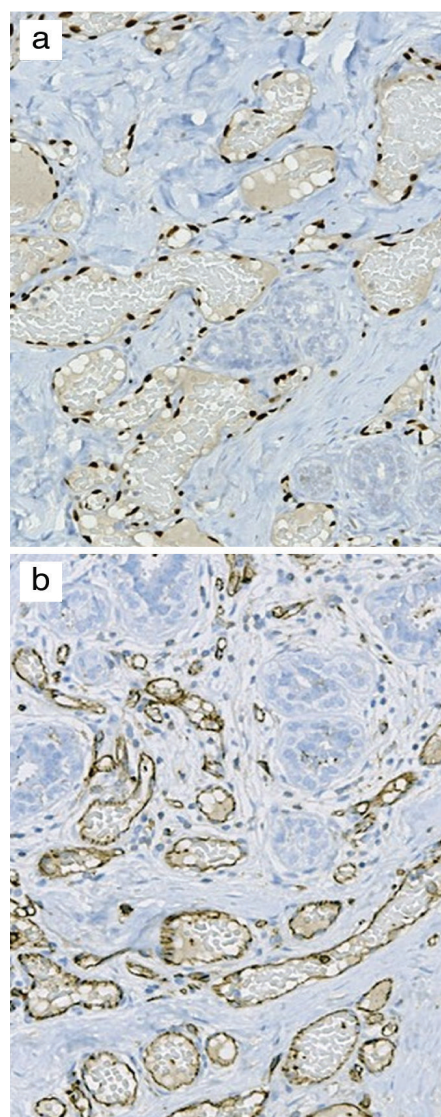


Figure 8. Positive staining for endothelial markers in vascular spaces scattered between and around normal breast ducts, in immunohistochemical study. a) ERG nuclear positivity, 200x, b) CD31, cytoplasmic positivity, 200x

ERG: erythroblast transformation-specific related gene

Breast hemangiomas may have nonspecific features on mammograms and usually there is no finding in these patients. Some hemangiomas may show a mass opacity with well-defined margins, with or without calcifications (8). On US examination, a hemangioma might be seen as an oval solid mass with circumscribed or microlobulated margins, and the echotexture can be hypoechoic, isoechoic or heterogeneous (8).

MRI demonstrates a variable appearance, depending on the size and subtype of the hemangioma. Hemangiomas are isointense with muscle in T1W images and hyperintense in T2W images. Also, there may be hypointense areas in the lesion because of calcifications, phleboliths and fibrous tissue in T2W images. These features are important for differentiation with malignancy. Dynamic, contrast-enhanced MRI is necessary for accurate determination of the size and distribution of the lesion. Hemangiomas have an early and diffuse enhancement pattern in dynamic, contrast-enhanced MRI.

The differential diagnosis must be made between any type of hemangioma within the breast and the possibility of a well-differentiated angiosarcoma, because in the latter, prognosis is poor. Angiosarcoma is of two types, primary and secondary (9, 10). In angiosarcoma, US and mammography may sometimes seem completely normal (11). As in our case, US and mammography findings may not be present, and hemangioma and angiosarcoma cannot be differentiated without tissue biopsy. In some cases, especially when the lesion is small, US and mammography cannot identify the lesion. MRI is a more sensitive modality than US and mammography. Hemangiomas enhance in the early phase of dynamic, contrast-enhanced MRI. Surgical excision is recommended because of this feature and because of the malignant potential of a hemangioma (12, 13). In our case, the MRI enhancement pattern mimicked malignancy and the lesion was only evident in MRI. The discordance between radiological and pathological findings prompted open surgical biopsy after needle wire localization with MRI guidance.

In conclusion, in the breast, hemangioma imaging findings can mimic malignancy. As there is a potential malignancy risk in vascular breast tumors, surgical excision and imaging follow-up is recommended in all cases of breast hemangioma.

Informed Consent: Informed consent was obtained from the patient.

Peer-review: Externally peer-reviewed.

Authorship Contributions

Surgical and Medical Practices: Ö.A., A.O., L.Y.; Concept: Ö.A., A.O.; Design: Ö.A., A.O. Data Collection and/or Processing: Ö.A., O.A., G.S., L.Y.; Analysis and/or Interpretation: Ö.A., A.O., O.A.; Literature Searching: Ö.A., A.O.; Writing: Ö.A., A.O., G.S.

Conflict of Interest: No conflict of interest declared by the authors.

Financial Disclosure: The authors declare that this study received no financial disclosure.

References

1. Lesueur GC, Brown RW, Bhathal PS. Incidence of perilobular hemangioma in the female breast. *Arch Pathol Lab Med* 1983; 107: 308-310. (PMID: 6687795) [\[Crossref\]](#)
2. Sebastiano C, Gennaro L, Brogi E, Morris E, Bowser ZL, Antonescu CR, et al. Benign vascular lesions of the breast diagnosed by core needle biopsy do not require excision. *Histopathology* 2017; 71: 795-804. (PMID: 28644513) [\[Crossref\]](#)
3. Hoda SA, Cranor ML, Rosen PP. Hemangiomas of the breast with atypical histological features. Further analysis of histological subtypes confirming their benign character. *Am J Surg Pathol* 1992; 16: 553-560. (PMID: 1599035) [\[Crossref\]](#)
4. Mesurolle B, Sygal V, Lalonde L, Lisbona A, Dufresne MP, Gagnon JH, et al. Sonographic and mammographic appearances of breast hemangioma. *AJR Am J Roentgenol* 2008; 191: W17-W22. doi: 10.2214/AJR.07.3153. (PMID: 18562711) [\[Crossref\]](#)
5. Kim SM, Kim HH, Shin HJ, Gong G, Ahn SH. Cavernous haemangioma of the breast. *Br J Radiol* 2006; 79: e177-e180. doi: 10.1259/bjr/11217388. (PMID: 17065282) [\[Crossref\]](#)
6. Apple SK, Dascalos JM, Bassett LW. Solid benign lesions of the breast. Bassett LW, Mahoney MC, Apple SK, D'Orsi CJ, editors. *Breast Imaging*. 1st ed. Philadelphia: Elsevier Saunders; 2011. p. 265-268. [\[Crossref\]](#)
7. Mango VL, Goodman S, Clarkin K, Wynn RT, Friedlander L, Hibshoosh H, et al. The unusual suspects: A review of unusual benign and malignant male breast imaging cases. *Clin Imaging* 2018; 50: 78-85. (PMID: 29328960) [\[Crossref\]](#)
8. Zafrakas M, Papasozomenou P, Eskitzis P, Zouzoulas D, Boulogianni G, Zaramboukas T. Cavernous breast hemangioma mimicking an invasive lesion on contrast Enhanced MRI. *Case Rep Surg* 2019; 2019: 2327892. (PMID: 31093413) [\[Crossref\]](#)
9. Monroe AT, Feigenberg SJ, Price Mendenhall N. Angiosarcoma after breast-conserving therapy. *Cancer* 2003; 97: 1832-1840. (PMID: 12673708) [\[Crossref\]](#)
10. Shet T, Malaviya A, Nadkarni M, Kakade A, Parmar V, Badwe R, et al. Primary angiosarcoma of the breast: observations in Asian Indian women. *J Surg Oncol* 2006; 94: 368-374. (PMID: 16967461) [\[Crossref\]](#)
11. Liberman L, Dershow DD, Kaufman RJ, Rosen PP. Angiosarcoma of the breast. *Radiology* 1992; 183: 649-654. (PMID: 1584913) [\[Crossref\]](#)
12. Ameen R, Mandalia U, Marr A, Mckensie P. Breast Hemangioma: MR Appearance with Histopathological Correlation *J Clin Imaging Sci* 2012; 2: 53. (PMID: 23029636) [\[Crossref\]](#)
13. Funamizu N, Tabei I, Sekine C, Fuke A, Yabe M, Takeyama H, Okamoto T. Breast hemangioma with difficulty in preoperative diagnosis: a case report *World J Surg Oncol* 2014; 12: 313. (PMID: 25312096) [\[Crossref\]](#)