



Oncoplastic Breast-Conserving Surgery According to Tumor Location

Nuh Zafer Cantürk¹, Turgay Şimşek¹, Sibel Özkan Gürdal²

¹Department of General Surgery, Kocaeli University School of Medicine, Kocaeli, Turkey

²Department of General Surgery, Tekirdağ University School of Medicine, Tekirdağ, Turkey

ABSTRACT

The use of oncoplastic breast surgery is an essential cornerstone for breast cancer management. The main aim of breast cancer surgery is to obtain an adequate oncological safety margin. Still, the cosmetic outcome also seems important for social and psychological wellbeing and quality of life. After breast-conserving surgery, the remaining breast may be reconstructed with volume displacement or volume replacement techniques. A better cosmetic outcome can be achieved by selecting appropriate surgical techniques according to tumor location. In this review, we show each technique step-by-step based on the tumor's location for each quadrant. The most important thing is to select the technique first for oncological safety and then for better cosmesis.

Keywords: Breast-conserving surgery, breast neoplasms, oncoplastic surgery

Cite this article as: Cantürk NZ, Şimşek T, Özkan Gürdal S. Oncoplastic Breast-Conserving Surgery According to Tumor Location. Eur J Breast Health 2021; 17(3): 220-233

Key Points

- Oncoplastic breast surgery aims to perform breast cancer treatment without deviating from the oncological principles
- The oncoplastic surgical methods selected vary by the location of the tumor.
- Level II oncoplastic breast surgery may be performed for the necessity of 20%–50% of breast tissue excision during the partial mastectomy in moderate- to large-sized breasts with moderate to severe ptosis.
- Techniques of Oncoplastic Breast-Conserving Surgery for the Upper or Central Breast Tumors are Crescent mastopexy, batwing or hemi batwing mastopexy, donot mastopexy, Grisotti or Racket mastopexy.
- Techniques of Oncoplastic Breast-Conserving Surgery for the Lower Quadrant Breast Tumors are triangular resection, inframammary resection, J, V or S mastopexy and reduction mammoplasty.
- In literature, there is no difference in surgical complications when compared OPS and breast-conserving surgery.

Introduction

Following oncoplastic breast-conserving surgery, the postoperative success rate is mainly related to appropriate patient selection, proper planning, a systematic examination, and preoperative drawing. Patients must be informed about the operative processes, postoperative outcomes, and possible complications.

The basics of oncoplastic surgery (OPS) stand on “primum nil nocere,” which is also essential to general medicine. At every step, the patient's demands must be considered and noted in her file. Also, the following questions must be answered.

- Is the patient appropriate for breast-conserving surgery?
- Does the patient have diabetes mellitus or any other comorbidity that would delay wound healing?
- Is there any addictive habit, including smoking, alcohol consumption, or other?
- Does the patient have any previous wound healing problems, such as keloid formation?
- Is there any previous breast surgery history or scar in the operation field?
- Is there any neoadjuvant chemotherapy history or malnutrition signs and symptoms? (1-3).

Corresponding Author:
Nuh Zafer Cantürk; canturkz@yahoo.com

Received: 19.01.2021
Accepted: 28.03.2021

Oncoplastic breast surgery aims to perform breast cancer treatment without deviating from the oncological principles and making the patient feel better by providing a better appearance. The indication of treatment is identified by the following:

- patients request,
- tumor characteristics,
- size and shape of the ipsilateral and contralateral breast,
- experience of the surgeon (4).

Understanding the patient's perspectives and sharing decision-making with her is critical.

First, surgeons must foster a comfortable setting. They should introduce themselves and their teams which helps them while providing the details on their skills. Surgeons must explain why they need to learn not only conditions related to the patient's disease but other personal issues. Also, surgeons need to take some measurements of her breast and take images of her breast and body naked. In addition, the surgeon has to provide her a chance to ask questions about the operative techniques, unexpected results, and complications. Surgeons should discuss with the patient a warranty for taking care of her, paying extreme attention to her individual preferences, allowing her to think about what to do and what she prefers before proceeding.

Next, surgeons need to determine what she knows about breast cancer and then offer options according to OPS standards.

During this step, if needed, surgeons can recommend neoadjuvant treatment. They must pay attention to making scars as small as possible with minimal asymmetry during one-stage breast reconstruction preferred or delayed reconstruction if post-mastectomy radiotherapy is required. So, surgeons will give the patient the chance to understand their aim to maximize reshaping. Surgeons must assist the patient with decision-making by providing the patient with a description of options and then summarizing everything.

In the last step, surgeons must analyze the patient's values and preferences. It is essential to remember that patients typically want fewer scars, the shortest hospitalization, less foreign materials, the lowest complication risk, a suitable and natural-looking appearance when naked, and the fewest number of surgeries. Surgeons must inform the patient that she can defer her decision, or if decided, she can change her mind before the operation without hesitation. This flexibility will build confidence and trust between the patient and surgeon. On the other hand, there are still some challenges about sharing decision-making. These are patient's reticents about deciding, difficulties understanding options, socioeconomic barriers, and request against evidence (1, 4-6).

The oncoplastic surgical methods selected vary by the tumor's location. Although radial ellipse segmentectomy and circumareolar segmental resection methods may be used for a tumor located in any breast region, more appropriate surgeries may be preferred by the tumor's location (1). Technique selection based on location is shown in Table 1. Surgeons should select the round block and batwing techniques for superior-medial quadrant lesion; lateral mastopexy for superior-lateral quadrant lesions, V mammoplasty for inferior medial and J-mammoplasty for inferolateral quadrant lesions, round block and inferior pedunculated mastectomy for lesions between the upper medial and lateral quadrant, and superior pedunculated mastectomy between the inferior medial and lateral quadrant lesions. Oncoplastic techniques, proposed by the French surgeon Krishna Clough, can include level I and level II OPS. Level I oncoplastic breast surgery is defined as the excision of less than 20% of the breast volume during breast-conserving surgery in small- to moderate-sized breasts with minimal ptosis (7).

In contrast, Level II oncoplastic breast surgery is defined as the necessary excision of 20% to 50% of the breast tissue during partial mastectomy in moderate- to large-sized breasts with moderate-to-severe ptosis. If the breasts' maximum excision volume is less than 20%

Table 1. Quadrant per quadrant techniques preferred

Location	Size of breast		
	Small	Medium	Large
Upper			
• Outer quadrant	Round block	Round block, inferior pedicle reduction	Round block, inferior pedicle reduction
• Middle quadrant	Round block Batwing	Round block, inferior pedicle reduction Batwing	Round block, inferior pedicle reduction
• Inner quadrant	Round block	Round block, inferior pedicle reduction	Round block, inferior pedicle reduction
Lower			
• Outer quadrant	Grisotti	Superior pedicle reduction, Grisotti, J mammoplasty	Superior pedicle reduction, inferior pedicle reduction
• Middle quadrant	Superior pedicle reduction, Grisotti	Superior pedicle reduction, Grisotti, triangular resection	Superior pedicle reduction, Grisotti, triangular resection
• Inner quadrant	Grisotti, triangular resection, inframammarian resection	Superior pedicle reduction, Grisotti, V mammoplasty	Superior pedicle reduction, inferior pedicle reduction, inframammarian resection
Central	Batwing, central, quadraneotomy	Grisotti, Batwing, inferior pedicle reduction	Inferior pedicle reduction, inverted T resection, Grisotti

and skin excision for reshaping and mammoplasty is not a necessity, it is called Level I. In contrast, Level II oncoplastic breast surgery excises more than 20% of breast tissue with skin and mammoplasty for moderate- to large-sized breasts with moderate-to-severe ptosis for breast cancer treatment (4, 8).

Level I OPS

One of the crucial points for Level I OPS techniques is having a sufficient amount of subcutaneous undermining. For undermining, the mastectomy plane must be followed and extended from one-fourth to two-thirds of the breast's surface area. It helps to both resect and redistribute the glandular tissue after the tumor excision. The recommended approach is to perform a full-thickness excision from the subcutaneous fat to the pectoralis fascia to ensure free anterior and posterior margins. The excision is made in a fusiform pattern for a better orientation toward the nipple-areolar complex (NAC) and easy re-approximation. Extensive tissue resection leads to NAC deviation. For both levels I and II OPS, a complete transection of the terminal ducts and separation of the NAC from the underlying tissue with 0.5–1 cm width to ensure vascularization. The tissue must be mobilized from the remaining breast's lateral positions or recruited from the breast's central portion (Figure 1) (9-12).

Level II OPS

Oncoplastic Breast-Conserving Surgery for Upper or Central Breast Tumors

Crescent Mastopexy Resection

Location and indication

It is suitable for a superior central tumor that does not involve the nipple or areola. The ideal lesion for this method is a lesion located between the periareolar ten to one o'clock position. Using this procedure in more medial or lateral lesions is not recommended because it may change the NAC's position.

Technique

An incision parallel to the areola is made to resect the skin and glandular tissue surrounding the mass with wide macroscopic margins on the breast. The incision is resected up to the pectoralis muscle in the presence of a small breast and large lesion. However, the procedure may be performed with a more superficial incision on a large breast because the two margins' approximation is more straightforward. The wound closure may be accomplished by approximating the superior and inferior dermoglandular edges in the retro-areolar fatty region to enable closure of the glandular tissue and skin (Figure 2) (13).

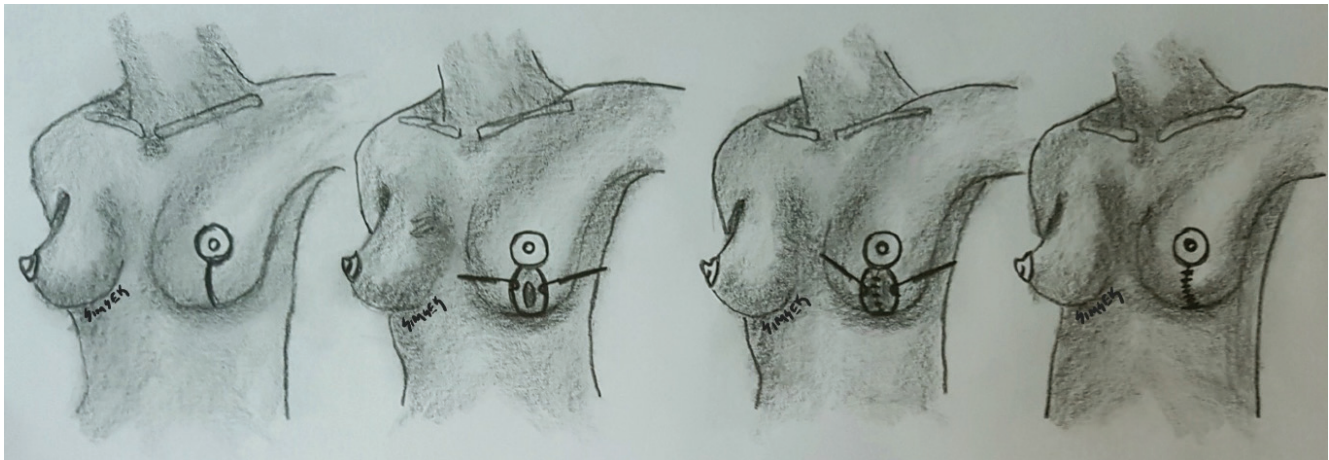


Figure 1. Step by step Level I Oncoplastic Breast Surgery (Drew by Turgay Şimşek)

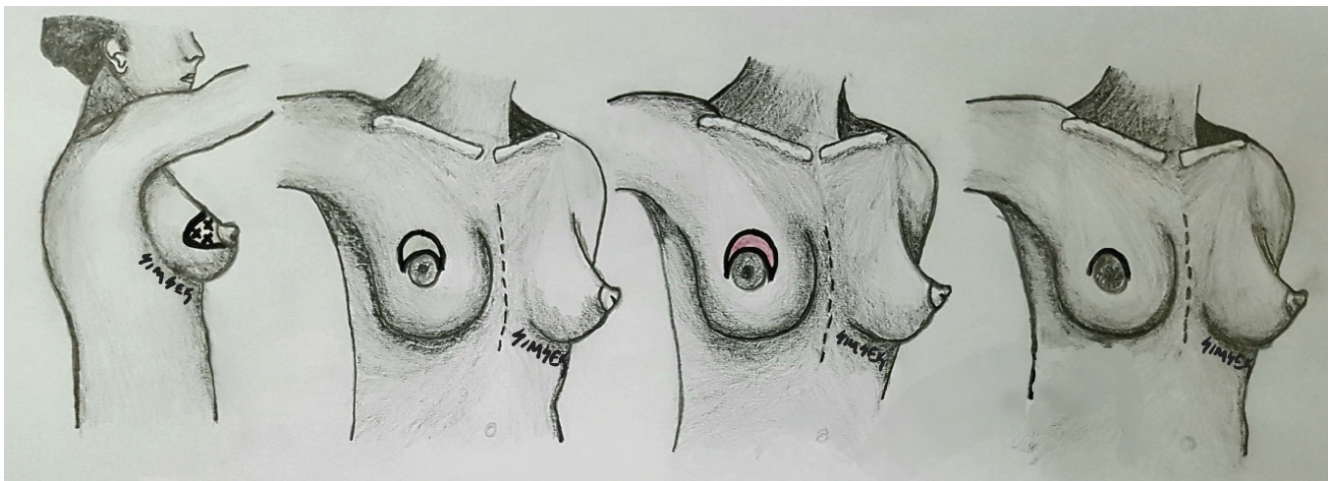


Figure 2. Crescent Mastopexy (Drew by Turgay Şimşek)

Batwing Resection

Location and indication

Batwing resection is used for wider excisions of the upper central regions within a few centimeters of the nipple but does not involve the nipple. Unlike crescent mastopexy, breast surgeons usually prefer to use this technique or hemibatwing resection when the areola is smaller and the tumor is more extensive.

Technique

Arches and wings parallel to the areola are drawn to provide triangular sections on both edges in addition to two rings as in the crescent incision, and then the incision is performed. Next, a full-thickness fibroglandular resection is extended to the chest wall to include the mass. It is essential to avoid performing a suture on the chest wall. However, bilateral closure of the released deep tissues is performed using absorbable sutures. The superficial tissues are closed as in the lumpectomy. The main problem with this technique is the unilateral nipple elevation and asymmetry. The correction procedures may be performed on the non-cancer breast to avoid this problem (Figures 3, 4) (13, 14).

Hemibatwing Resection

Location and indication

This method's optimal condition is the wide excision of superior outer periareolar lesions similar to 9–10 (on the right) or 2–3 (on the left)

o'clock. This method is not the preferred method for medial lesions because of possible visible scars.

Technique

A triangular excision is performed only on a single side. This is the difference between the hemibatwing resection and the batwing resection (Figure 5) (13).

Donut Mastopexy Resection (Round Block Technique)

Location and indication

Surgeons prefer this technique to treat tumors located in the upper and lateral quadrants. It is a beneficial technique for long and narrow segment resections of the breast. Its disadvantage is that the areolar complex and the nipple-areolar region will be denervated when the full-thickness skin excision is performed.

Technique

A second circular incision is performed in the areola's surrounding area and opening, and the ring-shaped skin in between is excised in full or partial thickness. Thus, access to approximately every section of the breast is enabled by subcutaneous releasing. The breast portions are closed using a 2-0 absorbable suture after the required resection is completed. Subcutaneous purse-string continuous sutures are used on the outer skin incision and are narrowed, and a new areolar margin is generated by suturing the two-incision sections (Figure 6) (15-17).

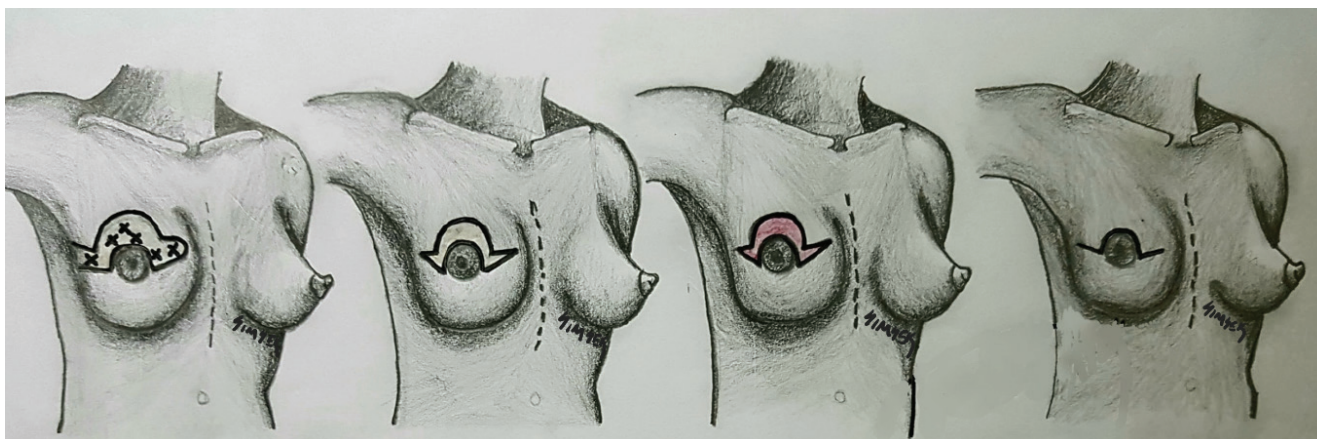


Figure 3. Batwing mammoplasty (Drew by Turgay Şimşek)

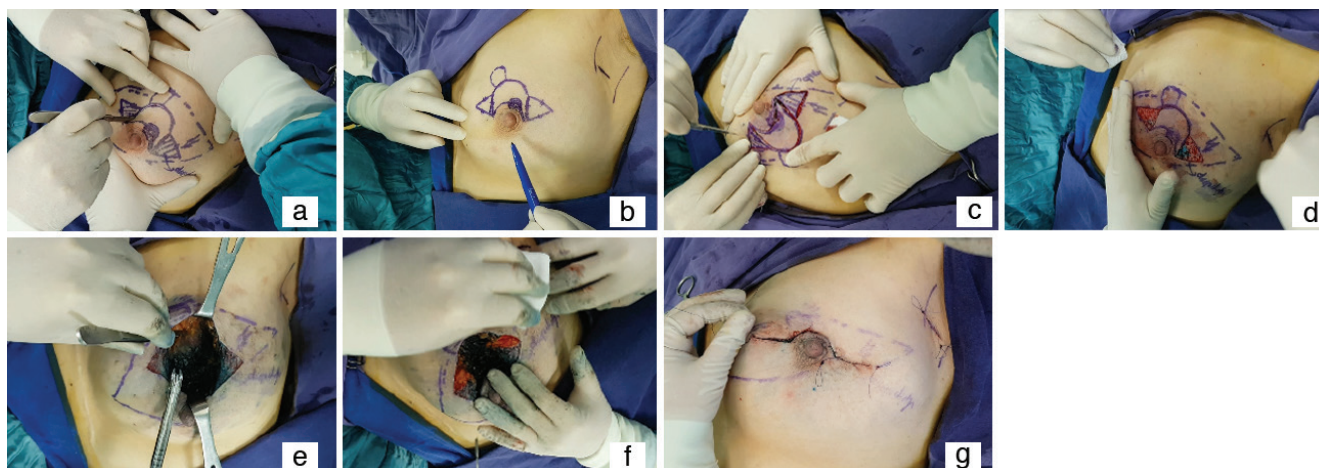


Figure 4a-g. Batwing procedure a-b) drawing c-f) excision, de-epithelization and preparation new nipple localization g) closing of incision

B-Flap Resection (Grisotti Mastopexy Technique)

Location and indication

This method is ideal for reconstructing the central breast when NAC resection is required because of the tumor's proximity in women with sufficient breast volume and moderate breast ptosis.

Technique

The NAC is resected until reaching the pectoral fascia. The breast tissue and the skin section in the shape of the areolar region from the lower quadrant are repositioned to the areola (new areola) as the inferior pedicle in this method, referred to as the B-flap resection. Also, the nipple formation and areola tattoo may be performed later (Figures 7, 8) (18-21).

Central Quadrantectomy

Location and indication

Apart from other techniques for centrally located lesions explained above, this technique is preferred for centrally located lesions in patients with widely ranging breast sizes.

Technique

The circumareolar incision includes 50% of the areola in this method and may be used mainly in women with larger breasts. The nipple-areola is preserved relatively thick for adequate vascular supply and nutrition in this method. The entire region behind it, which might have been marked using localizing wires, is resected in a cylinder shape from the subareolar plane to the pectoral muscle. Dissection of the subareolar plane can be extended in all directions to separate the areolar skin from the central gland. The tissue and skin layers are then closed by the tissues' approximation using 2–3 layers of several purse-string sutures (18, 19).

Racquet Mammoplasty

Location and indication

Breast-conserving surgery can easily excise large tumors in the upper outer quadrant without any deformity. More than a 20% excision of the breast may cause a deformity in small- or medium-sized breasts.

Technique

First, the NAC's circular line, another circular line situated 1–2 cm away from the NAC line, and a wedge-shaped line extending from

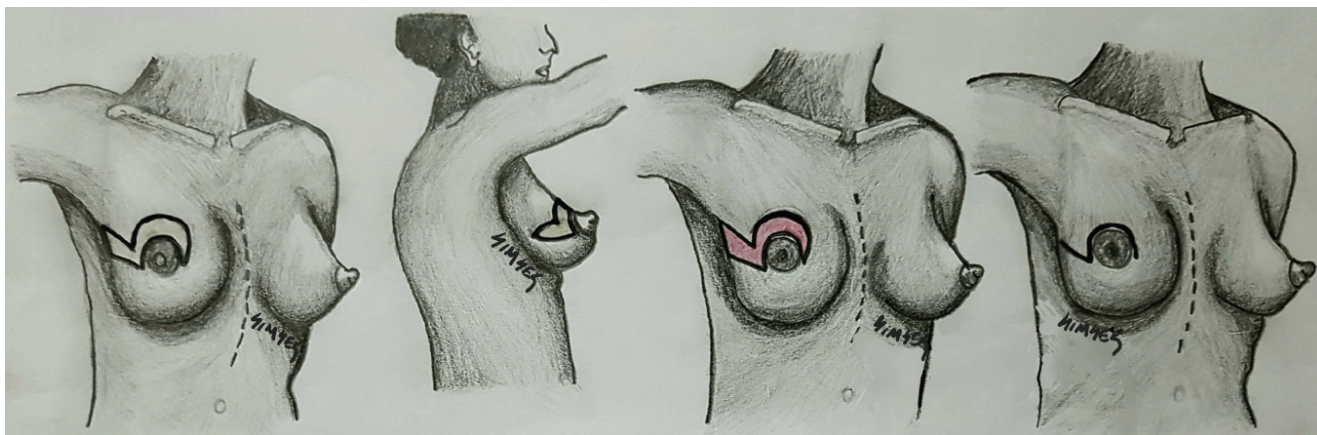


Figure 5. Hami- Batwing mammoplasty (Drew by Turgay Şimşek)

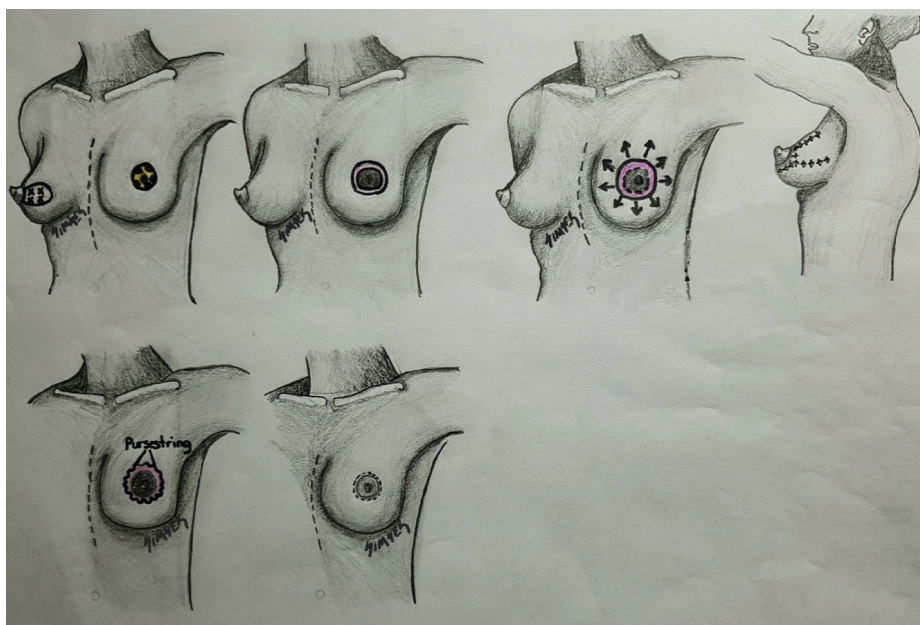


Figure 6. Donut mastopexy (Drew by Turgay Şimşek)

the areola to the axilla, are drawn and then incised. The next step is excision of the tumor, surrounding glandular tissue, and the pectoralis fascia with a wedge-shaped incision and de-epithelization between two circular lines around the NAC. Undermining the skin flap from the glandular tissue is the initial procedure. After that, the medial and lateral glandular tissue is mobilized from the pectoralis muscle. Following these procedures, four to six marking clips should be placed at the cavity's base. Both epithelial tissues are reapproximated with interrupted absorbable sutures to close the hole. If needed, the central gland could be undermined by the NAC. The subcutaneous tissue and the skin over the cavity are closed with absorbable sutures (Figure 9) (22, 23).

Oncoplastic Breast-Conserving Surgery for Lower Quadrant Breast Tumors

Triangular Resection

Location and indication

Cosmetic problems, such as a “bird beak” deformity, may develop after the tumors' excision is located in the breast's lower quadrants. However, the breast's lower pole may be reformed with the surrounding tissues' dislocating to the lumpectomy cavity. Relatively larger lesions located in that region may also be resected with this technique in which the total thickness wedge-shaped skin specimen and glandular tissue are resected.

Technique

- A triangular or wedge incision is made on the skin of the lesion in the breast.
 - The base of the triangle corresponds to the inframammary fold, and the apex points upward; however, it should not exceed the inferior areolar margin.
- The underlying glandular tissue is resected toward the chest wall after the skin is passed through.
 - The dissection plane during the resection is widened. It is completed on the surface of the serratus anterior muscle or through the incision of the rectus fascia toward the inframammary fold.
 - The rectus fascia and serratus anterior may be resected to ensure a negative deep surgical border posterior to the specimen if required.
 - Surgeons must generate a perpendicular glandular dissection plane compared with the skin to allow for the surgical margin. Surgeons must pay attention to avoid the specimen's excessive traction during dissection, resulting in the unintended dissection of tissue below the nipple and normal glandular tissue.
- The surrounding lower outer and lower inner quadrant glandular tissues are approximated in full-thickness on wound closure.
 - This is accomplished by extending the inframammary fold incision toward the breast's medial and lateral edges.

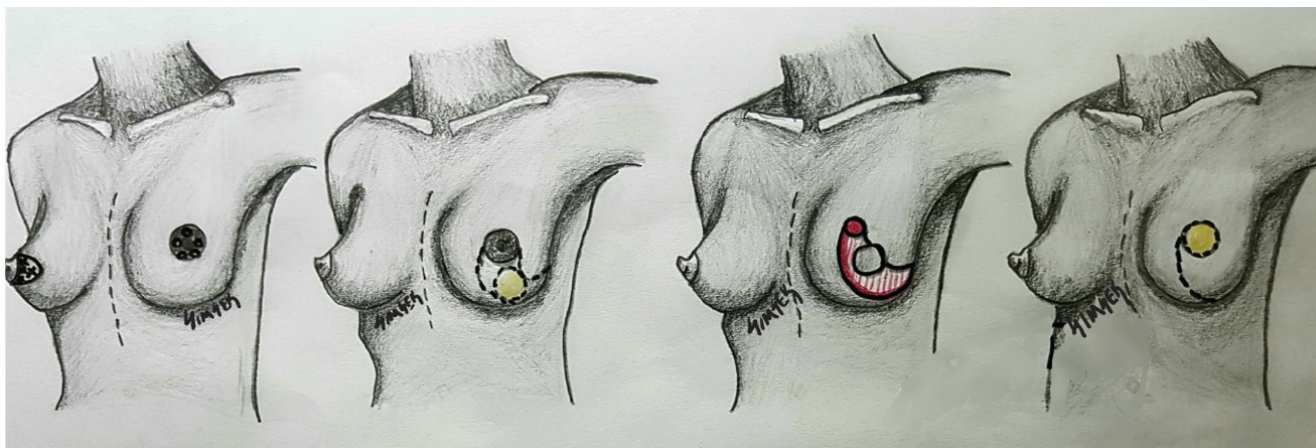


Figure 7. Step by step Grisotti Flap (Drew by Turgay Şimşek)

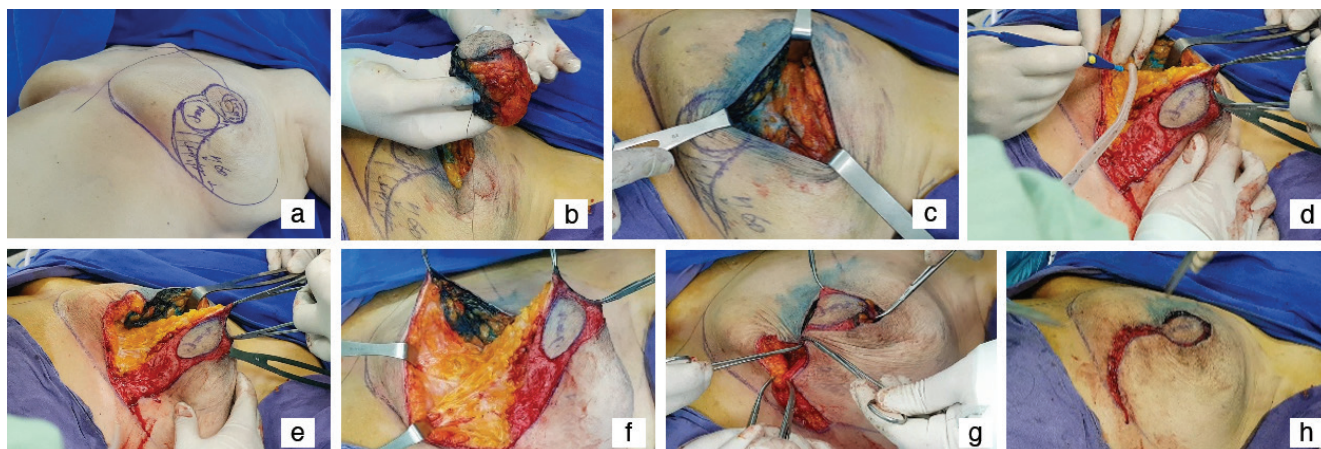


Figure 8a-h. Grisotti Flap preparation and operation processes a) drawing b-f) excision, de-epithelization and preparation new nipple localization g-h) closing of incision

- o The generated dermoglandular flaps are approximated layer-by-layer using 2-0 or 3-0 absorbable sutures.
- o The length discrepancy between the breast and inframammary fold edges may be overcome using a skin stapler with the redistribution of the short edge along the long edge.
- o The incision to be performed on the inframammary fold may be extended laterally and medially to enable more mobilization to the dermoglandular flap and avoid excessive tension on the breast skin's edges.
- The inframammary fold is closed using multiple layers by approximating the breast's fibrous and glandular tissues with the inframammary fold fibrous tissue.
- Then, the skin closure is completed using a smaller suture material (Figure 10) (4, 13).

Inframammary Resection

Location and indication

This technique is a suitable incision to resection tumors located in the lower and posterior breast regions. The resection is performed from an incision applied to the inframammary fold hidden below the breast. The inframammary approach is not recommended for removing the superficially located breast cancers to decrease the positive surgical border risk because the skin corresponding to the lesion is preserved. The surgeon must have the opportunity to perform marking using multiple wires or intraoperative ultrasonography to ensure that the malignancy is resected with an adequate surgical border while performing the resection using the indirect or "back door" approach.

Technique

- The incision is performed on the inframammary fold in the inframammary approach and maintains through the subcutaneous and fibrous layers toward the thoracic wall.

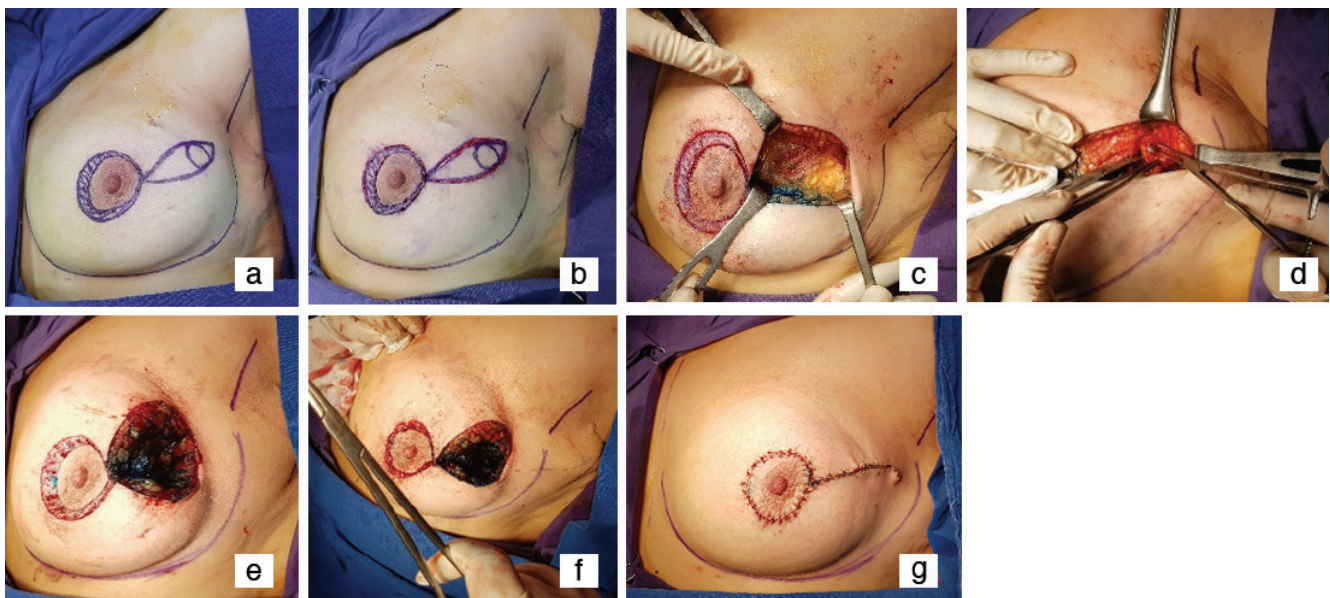
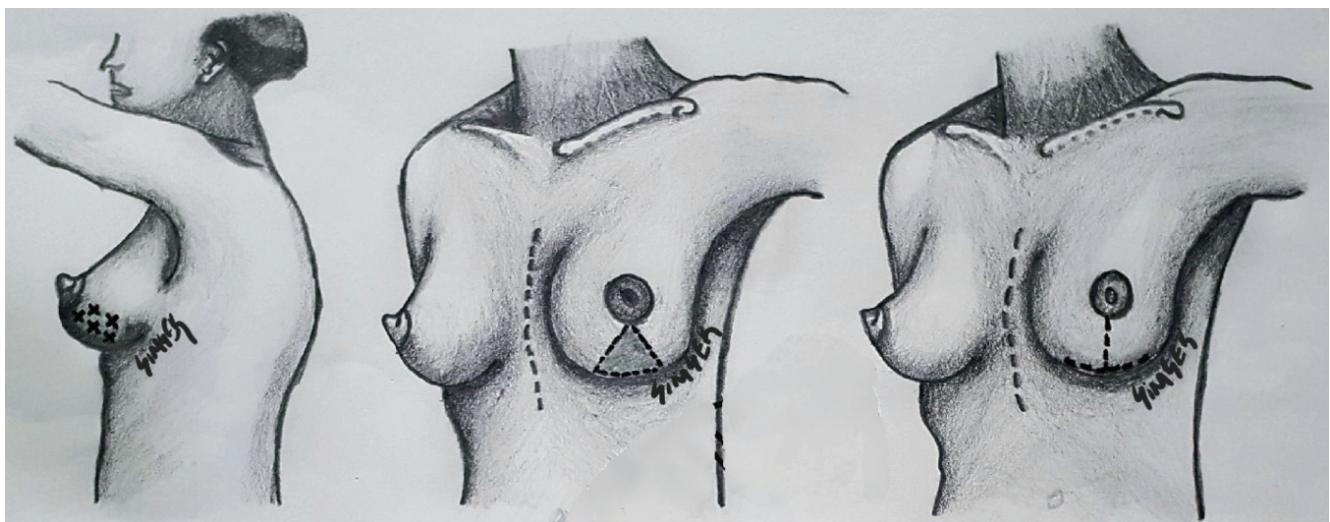


Figure 9a-g. Rocket Mammoplasty a, b) drawing c-f) excision and de-epithelization g) closing of incision



o The incision length depends partially on the lesion size, location, the mobilization required to access the lesion and close the surgical cavity.

♣ The larger lesions located in the upper parts will require a longer incision to access the breast's upper sides.

♣ The smaller and more distally located lesions may be accessed using a shorter incision on the medial, central, and lateral inframammary folds.

♣ The incision is made on the breast's posterior on the lesion perimetry and is extended toward the anterior for a broader resection of the tumor with possible superficial borders.

• The dissection is performed toward the retro-mammary fatty plane at least 3 cm above the tumor. The bimanual examination identifies the position, skin markings, wire markings, ultrasound, or the combination of all methods.

o The anterior of the lesion is more easily cleaned with the wires placed just above the lesion.

o The wire must be placed inside the gland when wire marking is used.

o The end of the wire must show the breast's posterior surface in the surgical cavity.

• The muscle fascia must also be resected with the surrounding tissues for deeper lesions.

• The wound closure is initiated with the approximation of the surgical borders to the cavity for decreasing or preventing skin retraction. This step is performed relatively more easily on breasts which are mobilized significantly wider from the chest wall. However, if additional mobilization is required, the dissection of the retro-mammary fatty plane or subcutaneous tissue plane may be performed to accomplish cavity closure.

• Finally, wound closure is completed with the approximation of the inframammary tissues using 2-0 or 3-0 absorbable sutures following the layered closure with smaller absorbable sutures (Figure 11) (13).

J-Mammoplasty

Location and indications

When the tumor is located in the lower inner or outer breast quadrants, the inverted T mammoplasty is not always appropriate.

Filling of the excision cavity with glandular flap in these locations is not comfortable with this technique. A tumor at the 4–5 o'clock position for the left breast is optimally managed with J-mammoplasty. A J-mammoplasty provides a chance to avoid lateral breast retraction and NAC deviation due to classical breast-conserving surgery. This technique is recommended for large, lower, outer quadrant tumors and tumors with extensive ductal carcinoma *in situ* and/or multifocality.

Technique

Two circular lines around NAC are prepared. The first line is located at the border of NAC, and the other is situated 1–2 cm away from it. The skin in between the two lines must be de-epithelized so that the tumor with its surrounding glandular tissue is excised with the skin, subcutaneous tissue, and pectoralis fascia. The incision patterns should be J-shaped for the left breast and reverse J-shaped for the right breast. After excision, the medial and lateral glandular tissue from the pectoralis muscle without skin undermining is necessary for closing the defect. It is necessary to monitor the tension during these procedures. After placing four to six marking clips, the skin is reapproximated with interrupted absorbable sutures. Rarely seen complications include hematomas, infections, skin necrosis, and wound dehiscence (Figure 12) (24, 25).

V-Mammoplasty

Location and indications

Breast conservation in the lower inner quadrant is a challenge and usually requires level II OPS to prevent deformities and poor outcomes. A V mammoplasty can be recommended as a solution for a lower inner quadrant tumor instead of the Wise pattern reduction mammoplasty or, else, a mastectomy. This technique is suitable for medium- or large-sized breasts with a broad base.

Technique

Breast mobilization and extensive posterior undermining of the lower gland can be performed through an inframammary incision. The tumor and surrounding breast tissue are removed en bloc with the overlying skin down to the pectoralis fascia. It is pyramidally excised with the apex located at the areola and its base in the inframammary fold's medial portion. Surgical clips are placed to

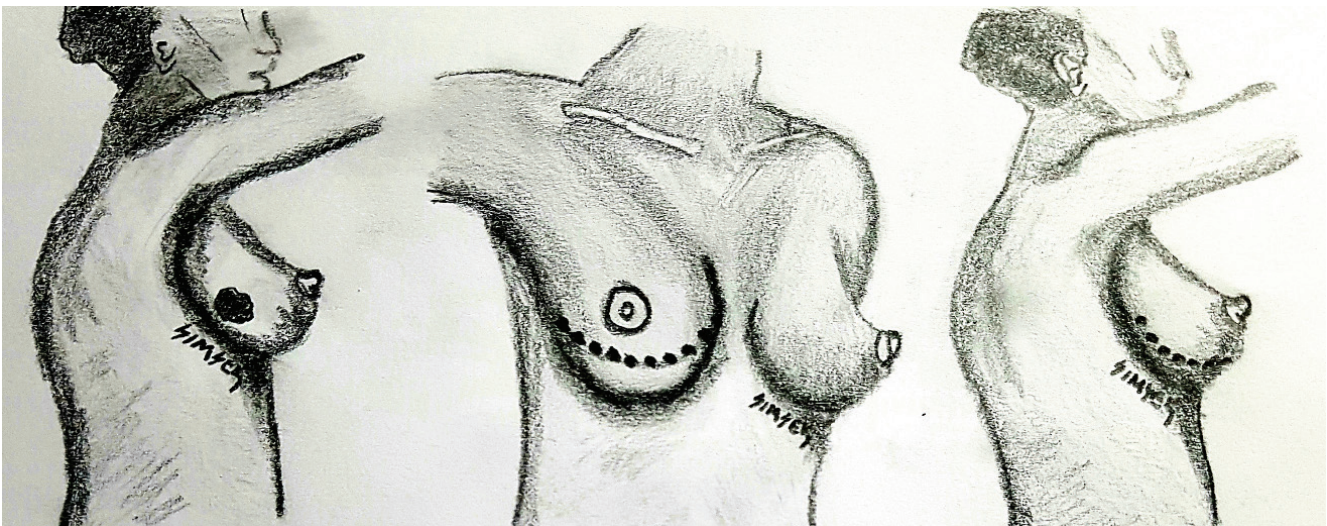


Figure 11. Inframammary resection (Drew by Turgay Şimşek)

mark the tumor as usual. The inframammary fold incision's lateral limit should be extended to at least 4 o'clock for the left breast. For selected cases, it can be extended to 3 or 2 o'clock in the lateral fold. So, you can mobilize more breast tissue medially and prevent tension on the incision without doing any additional skin undermining. Then, the NAC can be repositioned with the patient placed in the sitting position for an accurate comparative evaluation of the breast and the NAC symmetry. The NAC is recentralized directly opposite the initial tumor position by de-epithelizing the upper outer periareolar skin (26) (Figure 13).

S-Mammoplasty

Location and indications

This technique is recommended to young patients with plump breasts with mild to moderate ptosis and hypertrophy and lesions located in the lower quadrant. It is contraindicated for older patients with flaccid skin, Breast Imaging-Reporting and Data System I glandular tissue density, severe ptosis, large breasts, and tumors located in the NAC or upper quadrant.

Technique

After obtaining written informed consent and performing preoperative imaging, the midclavicular, midsternal, and inframammary lines are marked and drawn in the standing and sitting positions.

- Mark the midsternal and then the midclavicular point and draw the lines from top to bottom.

- Prepare a new site for the NAC at 18–22 cm on the breast meridian from the midclavicular point and 9–11 cm away from the midsternal line.

- Delineate the original NAC by marking A, B, C, and D at 12, 3, 9, and 6 o'clock around it.

- Draw the upper part of the new NAC parallel to the original one through points A1, B1, and C1.

- Mark, each of the new NAC points D1 and D2 with a 7–8 cm distance to point D, making the new NAC 4 cm above the inframammary fold and 18–21 cm lateral to the sternal notch along the nipple line. Mark point E on the inframammary line.

- The distance between A1-B1, A1-C1, and D2-E should be equal to those of B1-D2, C1-D1, and D1-E, respectively.

- De-epithelize the area between A, B, C, and A1, B1, and C1.

- A tumor located under the old NAC can be resected with the surrounding normal breast tissue. The wedge resection of the expected volume of lower breast tissue is made, and removal of more than the whole hemisphere is achieved.

- First, approximate the bilateral glandular tissues and suspend them to the fifth rib periosteum transversely above the inframammary fold with three large nonabsorbable sutures through the pectoralis muscle.

- Then, the new NAC can be approximated with a purse-string suture. The excess skin flap is minimal and well-tailored (Figure 14).

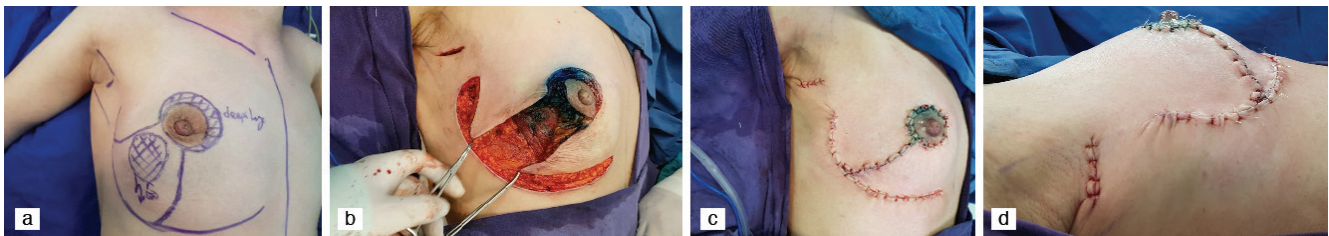


Figure 12a-d. J Mammoplasty a) drawing b) excision and c-d) closing of incision

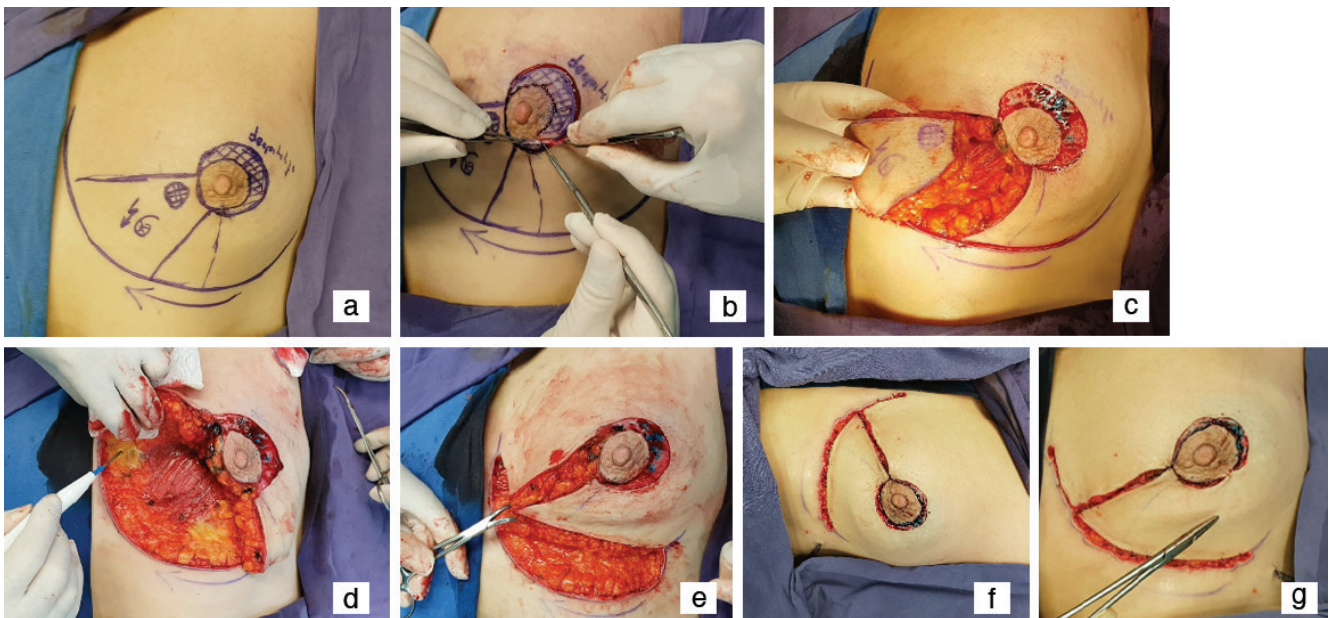


Figure 13a-g. V mammoplasty a) drawing b) de-epithelization, c, d) excision and e-g) closing of incision

A mild comprehensive dressing is recommended for about three days, and a post-mammoplasty garment and gentle massage are warranted for at least six months (27, 28).

Reduction Mammoplasty (RM)

Resection with reduction mammoplasty (RM) is a procedure that combines performing reduction mammoplasty and wide local tumor excision in a patient who requires breast reduction. RM resection, one of the more complex oncoplastic breast preserving procedures, should not be performed by surgeons who have inadequate plastic or OPS training. The reason for mentioning this issue is to provide an overview of the wide range of possibilities for surgeons who received or who will receive their training in OPS. Resection with RM may be accomplished by preserving or not preserving the nipple by the tumor region. When the NAC is maintained, the new nipple location is completed with the dislocation of the NAC to a more anterior and superior region.

The advantages of RM include:

1. Enabling the resection of larger masses with a wider local excision compared with the standard lumpectomy,
2. Enabling breast reconstruction, hiding more comprehensive segmental defects and providing aesthetic breast concavity. This approach also enables the resection of lesions, particularly at 4–8 o'clock level, in addition to retro-areolar or supra-areolar lesions.

The main goal of reduction techniques is to preserve the NAC's vascular nutrition and the residual breast.

1. The first technical issue in RM is incision planning. Although the conventional approach is a "Wise pattern" incision, the vertical reduction has become increasingly popular.

- "Wise pattern" is closed in the shape of the classic inverted T and generates the inferior dermoglandular pedicle base.

- The central skin incision forms the shape of the inverted V after the resection of the NAC. The apex reaches the NAC. Generally, the apex of the V is formed in the intersection of the two lines, one of which is the intersection line of inner and medial one-third of the clavicle with the nipple, and the second transverse line drawn in the level of inframammary fold suitable with the superior breast skin in sitting position. The apex of V is at an 18–20 cm distance to the suprasternal notch. The intersection point is the superior of the areola. V's legs from the superior areolar point extend from both sides of the NAC with approximately 10 cm length with 3–5 cm plus 5 cm or more length. The lines extend horizontally in the medial and lateral directions from this point to reach both sides of the inframammary fold. Skin marking is performed in a sitting or standing position.

- The mass preserves the NAC. As described above, the first marking is performed with the reversed U on the apex, and the reversed U incision is replaced instead of a V-shaped incision. After the wound closure on the breast, the vertical lines extend to the inframammary fold from the inferior areolar point. The horizontal lines form the superior skin borders of the new inframammary fold. The modifications of the standard inferior, medial, or lateral incisions were developed for utilizing breast preserving surgery and included correcting the incision suitable for the resection region.

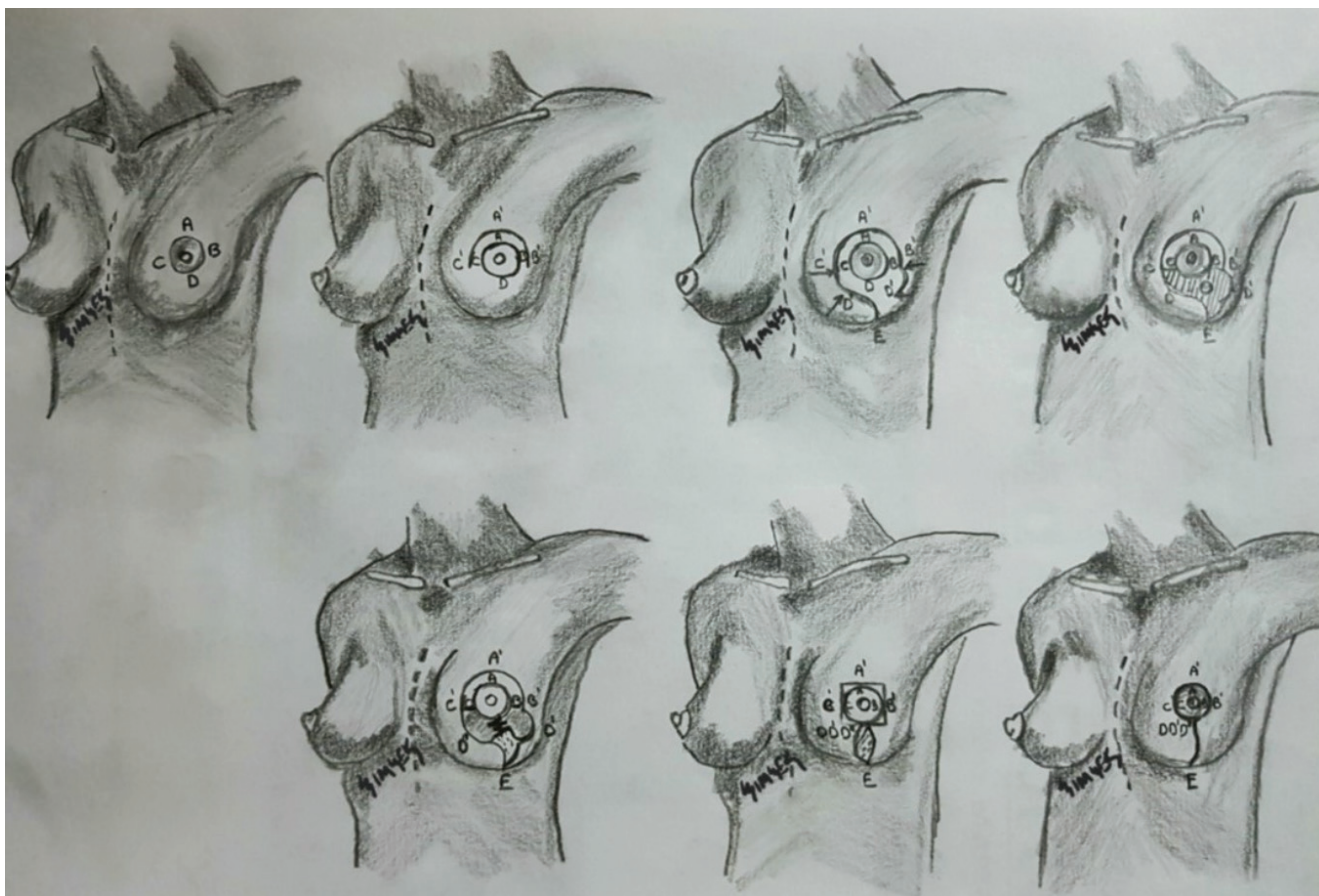


Figure 14. S Mammoplasty from drawing to closing of incision (Drew by Turgay Şimşek)

2. After planning the incision on the skin, the breast tumor resection, incision of the inframammary fold, the glandular parts on the affected skin toward the chest wall, and the dissection plane to the skin surface toward the right side are maintained. In cases where preserving the nipple and areola are planned, surgeons must try their best to provide the NAC's vascularity by avoiding the NAC's ignorance of the parenchyma's pedicle and preserving the residual dermis at least through two-thirds of the areolar circle. Besides, the region's epithelization between the residual areolar border and new superior skin border may increase the perfusion and enable the NAC's innervation. The surgeon may resect a larger portion medially or laterally in the glandular resection to obtain sufficiently healthy tissues in the neighboring region of the tumor in eccentrically located lesions (3–4 clock, or 7–8 clock positions). The dermoglandular flap where the residual breast tissue is used may be utilized to fill the defect after the tumor's complete removal.

3. The wound closure is initiated with the approximation with several staples, mainly performed in the inferior, medial, and lateral incisions.

- The nipple may be placed in between with the placing of the de-epithelized tissue below the incision if the drawn line on the apex of the Wise pattern (U shaped) is symmetrical. A cookie-cutter is used to generate a new superior incision after the reversed T incision is closed to obtain a better NAC. The removal of the additional skin tissue is accomplished with de-epithelization.
- A transverse or vertical closure may be used in accordance with the skin reduction type after the removal of the NAC.

4. The layered closure of the parenchyma, dermis, and skin enables forming the breast's final shape (Figures 15, 16).

Skin and fat necrosis are the most frequently detected complications, particularly in smokers and obese patients. Nipple-areola necrosis is detected in approximately 3% of patients (4).

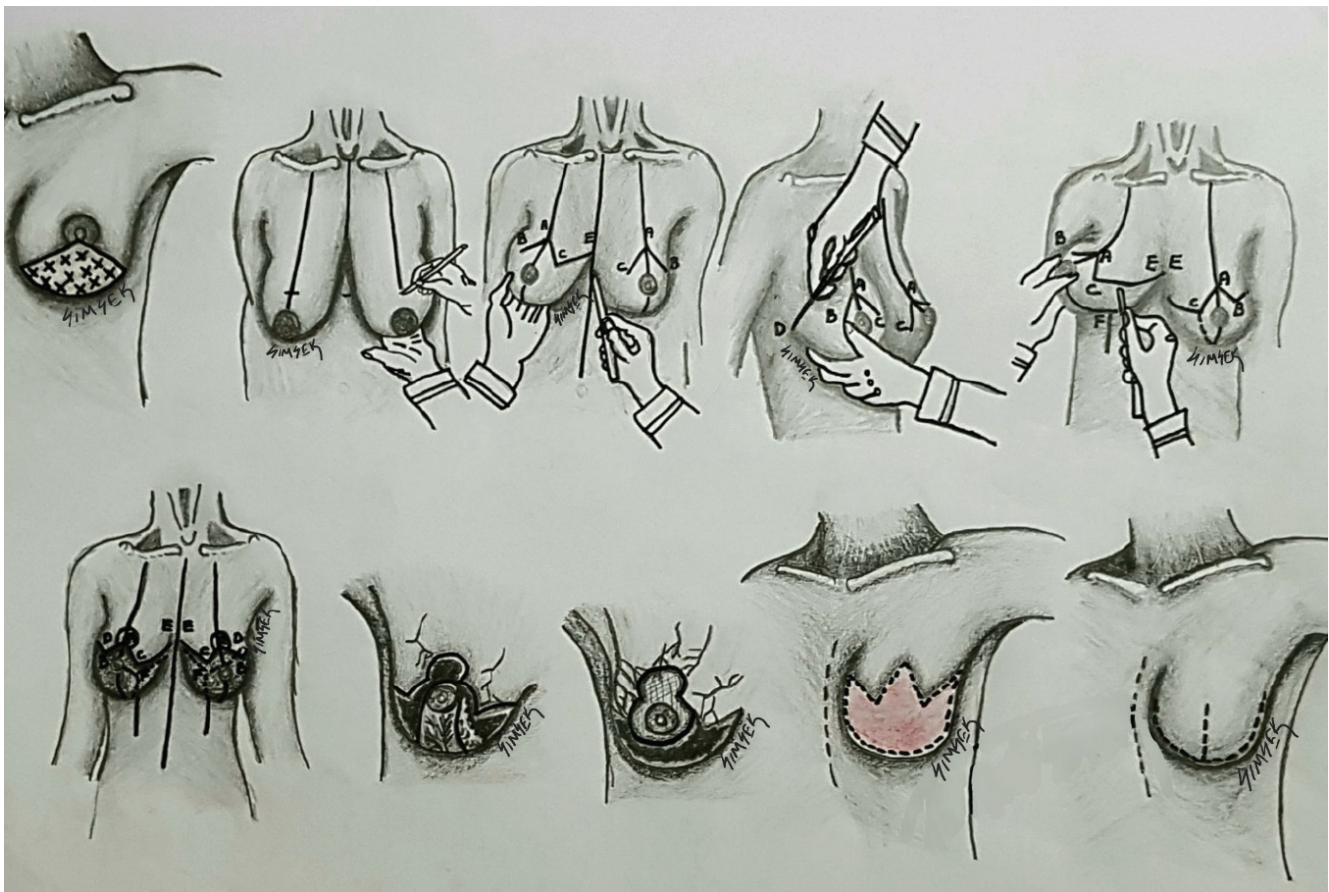
Inferior Pedicle Reduction

Location and indication

It is performed depending on one or more factors: the physical, psychological, medical, and social factors. This technique is particularly suitable for lesions located just above the nipple or lower inner or outer quadrants. This technique may be used in patients with various breast dimensions from smaller to larger breasts, including macromastia and breasts with significant ptosis.

Technique

The inferior pedicle's blood supply is enabled toward the axial region by the external branch of the internal mammarian artery and the fifth intercostal and lateral thoracic artery. The branches of the third, fourth, and fifth intercostal regions that extend to the skin are preserved in this technique and patients with macromastia. The pedicle consists of breast tissue with the dermis or only breast tissue without the dermis. The preservation of the dermis decreases the possibility of nipple necrosis because it preserves the subdermal vascular plexus. However, the de-epithelized dermis located in the pedicle is not necessarily required for the pedicle's or nipple's viability. The pedicle attaches to the muscle with an 8–10 cm thickness structure. Maintaining such



230 **Figure 15.** Step by step reduction mammoplasty with wise pattern (Drew by Turgay Şimşek)

a connection is required for adequate vascularization to preserve the required vessels and intact nerves, generate a better contour and enable sensation.

- Draw a line from the midclavicular point to pass through the nipple and inframammary fold.
- The point on the line will be the ideal point for the new nipple when you put your hand on the inframammary fold and hold the breast with your thumb.
- The new nipple corresponds to the intersection of a line of 19–21 cm extending from the midclavicular line and sternal notch, or to the junction of the line drawn from the intersection point of 2/3 below of humerus.
- Two lines of 7–8 cm length are drawn from this point with degrees of 90° and 140°. These points are named A and B.
- A new line is drawn from the points A and B to correspond to the inframammary fold with 90° and 110° degrees.
- The diameter of the new areola will be 3.5–4 cm.
- The Figure shown here is called the “Wise pattern” (Figure 15).
- An incision is made on the lower half of the areola, and the lower inframammary fold on the pedicle only on the epidermis level. A small triangular region is reserved in the middle point to facilitate the closure.
- The skin on the pedicle is de-epithelized to preserve the intradermal vascular pedicle.
- The parenchyma is dissected toward the chest wall. This dermoglandular pedicle supports the nipple with approximately a

10 cm base and 3 cm deepness. The length should not exceed 15–20 cm. Otherwise, it cannot provide enough vascular supply, and the reduction specimen is disunited from the breast.

- A temporary approximation of the incisions is performed using staples on the breast.
- The nipple is first embedded in the subcutaneous region and is removed at a later stage. The NAC's standard distance to the inframammary fold is approximately 5 cm; however, space is longer in more considerable reductions.
- A tangential dissection must be performed for prominent breast concavity to avoid skin thinning. The pedicle's excessive mobilization and traction must be avoided to protect the perforating vessels from damage (Figure 16).
- The NAC should not be elevated too high. In the suspicion of an incident, lifting down the NAC may be preferred by distancing from the part described as the “no man's land.”
- Enabling a triangular connection on the mammarian fold will prevent potential tension at the T's intersection point.

The limitations of this technique

- Though infrequent, the length of the horizontal scar may cause a problem.
- Pseudoptosis is the extension of the majority of the breast below the inframammary fold. However, the nipple is located at this level or slightly below this location. This is mainly a problem in obese patients with pendulous breasts. This is due to the shrinkage of the vertical portion of the inframammary scar, which is associated with the reconstruction of the nipple redundantly above (29-34).

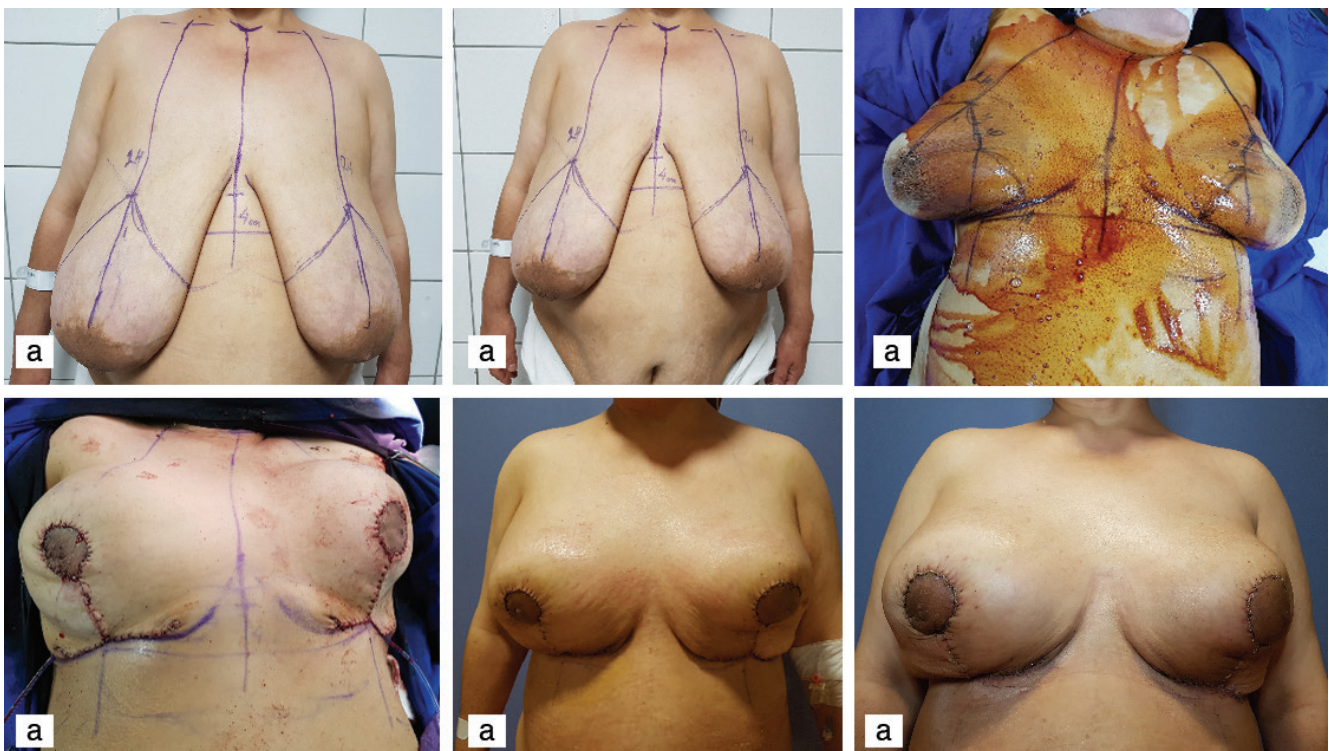


Figure 16a-f. Reduction Mastopexy **a-c)** Drawing (wise pattern), **d)** peroperative result and **e, f)** early postoperative pictures

Superior Pedicle Reduction

Location and indication

This technique is particularly suitable for the situations where the wide resection of the lesions on 5, 6, and 7 o'clock level. "Comma-shaped mammoplasty" is particularly recommended for the small or medium-size breasts for the lesions at the 6 o'clock position. This technique and inferior pedicle RM may also be used to maintain symmetry with the contralateral breast.

Technique

Mastopexy and RM may be accomplished with these techniques with the small part of the parenchyma's excision.

1. Median sternal and the inframammary line is drawn for the Wise pattern mammoplasty. The line is extended from the midclavicular point to the inframammary line of the nipple. Two legs of the Wise pattern region are drawn to provide a mean diameter of 5 cm.

2. The vertical line is drawn to the inframammary line with the "comma-shaped mammoplasty." The broader breast tissue will be resected by the distance in this type of mammoplasty. The line is drawn to intersect the inframammary line from the end of the oblique/vertical line. The diameter of the areola must be approximately 3.5–4.5 cm. The possibility of a deformity such as an inferior nipple retraction may develop due to a conventional wide resection may be decreased using this type of mammoplasty (4, 34).

Outcome and Safety of Level I and Level II OPS

Resection margin and re-excision rates

OPS for breast cancer allows broader tissue resection. Oncoplastic surgeons still argue that the reduction positive margin rate and the re-excision rate with wider resections are lower than standard breast-conserving surgery. However, wider negative margins are not associated with lower recurrence rates. In addition, eight of 13 comparative studies showed better positive margins, re-excisions, and mastectomy conversion rates following oncoplastic breast cancer surgery (35-38).

Local recurrence and oncological outcome

The studies highlight the importance of local control following breast cancer surgery regarding patient survival. Most studies demonstrated no significant difference between OPS and control arms, including breast-conserving surgery and mastectomy. Still, Carter et al. (36) showed that the OPS arm in their most extensive comparative study had a better recurrence rate than the mastectomy arm. Mansell et al. (39), in 2017, also confirmed the same result when radiation treatment was added to mastectomy (35, 36, 39, 40).

Complications and Cosmetic Outcome

Complications following OPS include liponecrosis, skin necrosis, hematoma, seroma, delayed wound healing, nipple necrosis, and/or infection. Most studies that compared OPS and breast-conserving surgery showed no difference in surgical complications (35, 36).

Conclusion

OPS is a fundamental tool for breast cancer treatment. A large amount of breast tissue can be safely excised without poor cosmetic outcomes while ensuring oncological safety and potentially reducing the number

of re-excisions and mastectomy. Although patient satisfaction rates seem high with breast-conserving surgery, it is recommended to select the appropriate OPS technique based on each patient's characteristics and tumor location.

Peer-review: Externally peer-reviewed.

Author Contributions

Conception: N.Z.C., T.Ş., S.Ö.G.; Design: N.Z.C., T.Ş., S.Ö.G.; Literature Search: N.Z.C., T.Ş., S.Ö.G.; Writing: N.Z.C., T.Ş., S.Ö.G. Drawings: T.Ş.

Conflict of Interest: No conflict of interest was declared by the authors.

Financial Disclosure: The authors declared that this study has received no financial support.

References

1. Bildham A, Bisjop H, Boland G, Dalglish M, Davies L, Fatah F, et al. Oncoplastic breast surgery- a guide to good practice. *Eur J Surg Oncol* 2007; 33(Suppl 1): S1-23. doi: 10.1016/j.ejso.2007.04.014 (PMID: 17604938) [[Crossref](#)]
2. Association of Breast Surgery at BASO. Surgical guidelines for the management of breast cancer. *Eur J Surg Oncol* 2009; 35(Suppl 1): 1-22. (PMID: 19299100) [[Crossref](#)]
3. Emiroğlu M, Kuru B, Soybir G. *Onkoplastik meme cerrahisi atlası*. İzmir: Birleşik Matbaacılık; 2015. [[Crossref](#)]
4. Holmes DR, Schooler W, Smith R. Oncoplastic approach to breast conservation. *Int J Breast Cancer* 2011;303879:1-16. [[Crossref](#)]
5. Shiffman MA. Preoperative consultation. Shiffman MA (ed.) *Mastopexy and breast reduction: Principles and practice*. Berlin: Heidelberg Springer-Verlag; 2019. p. 11-12.
6. Macmillan RD, McCulley SJ. Variations of classical reduction patterns for oncoplastic purposes. Rovere GQ, Benson JR, Nava M (eds.) *Oncoplastic and re constructive surgery of the breast*. London: Informa; 2011. p.155-160.
7. Clough KB, Benyahi D, Nos C, Charles C, Sarfati I. Oncoplastic surgery: pushing the limits of breast-conserving surgery. *Breast J* 2015; 21: 140-146. (PMID: 25676776) [[Crossref](#)]
8. Clough KB, Kaufman GJ, Nos C, Buccimazza I, Sarfati IM. Improving breast cancer surgery: a classification and quadrant per quadrant atlas for oncoplastic surgery. *Ann Surg Oncol* 2010; 17: 1375-1390. (PMID: 20140531) [[Crossref](#)]
9. Kraissl CJ. The selection appropriate lines for elective surgical incisions. *Plast Reconstr Surg* 1951; 8: 1-28. (PMID: 14864071) [[Crossref](#)]
10. Schlenz I, Rigel S, Schemper M, Kuzbari R. Alteration of nipple and areola sensitivity by reduction mammoplasty: a prospective comparison of five techniques. *Plast Reconstr Surg* 2005; 115: 743-751. (PMID: 15731673) [[Crossref](#)]
11. Petit JY, De Lorenzi F, Rietjens M, Intra M, Martella S, Garusi C, et al. Technical tricks to improve the cosmetic results of breast conserving treatment. *Breast* 2007; 16: 13-16. (PMID: 17070051) [[Crossref](#)]
12. O'Dey D, Prescher A, Pallua N. Vascular reability of nipple areola complex-bearing pedicles. An anatomical microdissection study. *Plast Reconstr Surg* 2007; 119: 1167-1177. (PMID: 17496587) [[Crossref](#)]
13. Nahabedian MY. *Oncoplastic surgery of the breast*. 2nd ed. China: Elsevier; 2009.
14. Anderson BO, Masetti R, Silverstein MJ. Oncoplastic approaches to partial mastectomy: an overview of volume displacement techniques. *Lancet Oncol* 2005; 6: 145-157. (PMID: 15737831) [[Crossref](#)]

15. Masetti R, Pirulli PG, Magno S, Franceschini G, Chiesa F, Antinori A. Oncoplastic techniques in the conservative surgical treatment of breast cancer. *Breast Cancer* 2000; 7: 276-280. (PMID: 11114849) [\[Crossref\]](#)
16. Amanti C, Moscaroli A, Lo Russo M, Papaspyropoulos V, Luzzatto L, Catracchia V, et al. Periareolar subcutaneous quadrenectomy: a new approach in breast cancer surgery. *G Chir* 2002; 23: 445-449. (PMID: 12652922) [\[Crossref\]](#)
17. Amanti C, Regolo L, Moscaroli A, Lo Russo M, Catracchia V. [Total periareolar approach in breast conserving surgery.] *Tumori* 2003; 89(Suppl 4): 169-172. (PMID: 12903581) [\[Crossref\]](#)
18. Wagner E, Schrenk P, Huemer GM, Sir A, Schreiner M, Wayand W. Central quadrenectomy with resection of the nipple-areola complex compared with mastectomy in patients retroareolar breast cancer. *The Breast J* 2007; 13: 557-563. (PMID: 17983395) [\[Crossref\]](#)
19. Naguib SE. Oncoplastic resection of retroareolar breast cancer: central quadrenectomy and reconstruction by local skin-glandular flap. *J Egypt Natl Canc Inst* 2006; 18: 334-347. (PMID: 18301457) [\[Crossref\]](#)
20. Regnault P. Reduction mammoplasty by the "B" technique. *Plast Reconstr Surg* 1974; 53: 19-24. (PMID: 4588595) [\[Crossref\]](#)
21. Grisotti A. Immediate reconstruction after partial mastectomy. *Op Technique Plast Reconstr Surg* 1994; 1: 1-12. [\[Crossref\]](#)
22. Clough KB, Ihrai T, Oden S, Kaufman G, Massey E, Nos C. Oncoplastic surgery for breast cancer based on tumor location and a quadrant-per-quadrant atlas. *Br J Surg* 2012; 99: 1389-1395. (PMID: 22961518) [\[Crossref\]](#)
23. Yang JD, Lee JW, Cho YK, Kim WW, Hwang SO, Jung JH, et al. Surgical techniques for personalized oncoplastic surgery in breast cancer patients with small- to moderate-sized breasts (part 1): volume displacement. *J Breast Cancer* 2012; 15: 7-14. (PMID: 22493623) [\[Crossref\]](#)
24. Gesperoni C, Salgarello M, Gasperoni P. A personal technique: mammoplasty with J scar. *Ann Plast Surg* 2002; 48: 124-130. (PMID: 11910216) [\[Crossref\]](#)
25. Elbaz JS. [Technic of mammoplasty by a J cicatrix.] *Ann Chir Plast* 1975; 20: 101-111. (PMID: 1103701) [\[Crossref\]](#)
26. Clough KB, Oden S, Ihrai T, Massey E, Nos C, Serfati I. Level 2 oncoplastic surgery for lower inner quadrant breast cancers: the LIQ-V-Mammoplasty. *Ann Surg Oncol* 2013; 20: 3847-3854. (PMID: 23838910) [\[Crossref\]](#)
27. Sanidas EE. S-mammoplasty no man's land. Fitzal F, Schrenk P (eds). *Oncoplastic breast surgery*. 2nd ed. New York: Springer; 2015. p.45-48. [\[Crossref\]](#)
28. Chen TH, Wei FC. Evolution of the vertical reduction mammoplasty: the S Approach. *Aesth Plast Surg* 1997; 21: 97-104. (PMID: 9143424) [\[Crossref\]](#)
29. Georgiade NG, Serafin D, Morris R, Georgiade G. Reduction mammoplasty utilizing an inferior pedicle nipple areolar flap. *Ann of Plast Surg* 1979; 3: 211-218. (PMID: 543656) [\[Crossref\]](#)
30. Wise RJ. A preliminary report on a method of planning mammoplasty. *Plast Reconstr Surg* (1946) 1956; 17: 367-375. (PMID: 13335513) [\[Crossref\]](#)
31. Lejour M, Abboud M, Declety A, Kertesz P. Reduction des cicatrices de plastimammaire de L'ancre courte a la verticale. *Annales de Chirurgie Plastique Esthétique* 1990; 35: 369-379. [\[Crossref\]](#)
32. Mathes S. *Plastic Surgery*. St. Louis, US: Quality Medical Publishing; 2006.
33. Hudson DA. A modified excision for combined reduction mammoplasty and breast conservation therapy in the treatment of breast cancer. *Aesthetic Plastic Surg* 2007; 31: 71-75. (PMID: 17235466) [\[Crossref\]](#)
34. Munhoz AM, Montag E, Arruda EG, Claudia Aldrighi, Rolf Gemperli, José Mendes Aldrighi JM, et al. Critical analysis of reduction mammoplasty techniques in combination with conservative breast surgery for early breast cancer treatment. *Plast Reconstr Surg* 2006; 117: 1091-1111. (PMID: 16582770) [\[Crossref\]](#)
35. Campbell EJ, Romics L. Oncological safety and cosmetic outcomes in oncoplastic breast conservation surgery, a review of the best level of evidence literature. *Breast Cancer (Dove Med Press)* 2017; 9: 521-530. (PMID: 28831273) [\[Crossref\]](#)
36. Carter SA, Lyons GR, Kuerer HM, Bassett Jr RL, Oates S, Thompson A, et al. Operative and oncological outcomes in 9861 patients with operable breast cancer single-institution analysis of breast conservation with oncoplastic reconstruction. *Ann Surg Oncol* 2016; 23: 3190-3198. (PMID: 27406093) [\[Crossref\]](#)
37. Haloua MH, Krekel Nm, Winters HA, Rietveld DHE, Meijer S, Bloemers FW, et al. A systemic review of oncoplastic breast conserving surgery: current weakness and future prospects. *Ann Surg* 2013; 257:609-620. (PMID: 23470508) [\[Crossref\]](#)
38. Jeevan R, Cromwell DA, Trivella M, Lawrence G, Kearins O, Pereira J, et al. Reoperation rates after breast conserving surgery for breast cancer among women in England: retrospective study of hospital episode statistics. *BMJ* 2012; 345: e4505. doi: 10.1136/bmj.e4505 (PMID: 22791786) [\[Crossref\]](#)
39. Mansell J, Weiler-Mithoff E, Martin J, Khan A, Stallard S, Doughty JC, et al. How to compare the oncological safety oncoplastic breast conservation surgery-to wide local excision or mastectomy? *Breast* 2015; 24: 497-501. (PMID: 26009307) [\[Crossref\]](#)
40. Mansell J, Weiler-Mithoff E, Stallard S, Doughty JC, Mallon E, Romics L. Oncoplastic breast conservation surgery is oncologically safe when compared to wide local excision and mastectomy. *Breast*. 2017; 32: 179-185. (PMID: 28214785) [\[Crossref\]](#)