

INVASIVE CYSTIC HYPERSECRETORY DUCTAL CARCINOMA of THE BREAST

Erdiñç Kamer¹, Haluk Recai Ünal¹, Taner Akgüner¹, Seyran Yiđit², Mehmet Ali Önal¹

¹İzmir Atatürk Eđitim ve Arařtırma Hastanesi, 4.Genel Cerrahi, İzmir, Türkiye

²İzmir Atatürk Eđitim ve Arařtırma Hastanesi, Patoloji Kliniđi, İzmir, Türkiye

ABSTRACT

The cystic hypersecretory ductal carcinoma of the breast are rare. These lesions of the breast are usually low-graded, but also can be observed as high-graded or invasive carcinomas. A 40-year-old woman admitted with a 3-month history of a mass in her left breast. Examination revealed a 2 cm mobile, painless, soft palpable lump mass in the upper inner quadrant of her left breast. Mammography and ultrasonographic findings were in accordance with fibroadenoma. The cytologic examination of the fine needle aspiration biopsy of the mass was reported to be non-diagnostic. An excisional biopsy of left breast was performed. Histopathologic examination revealed invasive cystic hypersecretory ductal carcinoma. The patient refused the modified radical mastectomy and underwent quadrantectomy and axillary dissection. No residual tumor was observed in the quadrantectomy material. Lymph nodes were 0/11. No complication was observed during the postoperative period and underwent adjuvant radiotherapy. Local recurrences or metastasis was not observed in the patient during 18 months follow-up after the radiotherapy.

Key words: invasive, cystic hypersecretory, breast, carcinoma

MEMENİN İNVAZİV KİSTİK HİPERSEKRETUAR DUKTAL KARSİNOMU

ÖZET

Memenin kistik hipersekratuar duktal karsinomu oldukça nadirdir. Mememin bu lezyonları genellikle düşük derecelidir fakat yüksek dereceli yada invaziv karsinom da olabilir. 40 yaşında bayan hasta 3 aylık sol memesinde kitle hikayesiyle başvurdu. Fizik muayenede sol meme üst iç kadranda 2 cm lik hareketli, ağrısız, yumuşak kitle mevcuttu. Mamografi ve meme ultrasonu sonucu fibroadenom ile uyumlu idi. İnce iğne aspirasyon biyopsi sonucu tanısal değildi. Eksizyonel biyopsi uygulandı. Histopatolojik inceleme sonucu invaziv kistik hipersekratuar duktal karsinom olarak geldi. Modifiye radikal mastektomiyi kabul etmeyen hastaya sol kadrantektomi ve aksiler disseksiyon uygulandı. Kadrantektomi materyalinde ve 11 aksiller lenf nodunun tamamında tümör saptanmadı. Postoperatif dönemde komplikasyon gelişmedi. Hastaya adjuvant radyoterapi uygulandı. Radyoterapi sonrası 18 aydır takipte olan hasta da tekrarlama saptanmadı.

Anahtar sözcükler: invaziv, kistik hipersekratuar, meme, karsinom

Cystic hypersecretory lesions of the breast are distinct, rare form of ductal carcinoma in situ of the breast, with less than 40 cases describe up to now, mostly as case reports (1). The cystic hypersecretory ductal carcinoma (CHDC) first described by Rosen and Scott in 1984 (2). These lesions are characterized by the presence of dilated ducts and cysts containing glistening, gelatinous material and focal areas of micropapillary carcinoma in the epithelium lining the cysts. An invasive component has been reported in approximately 20% of CHDC cases and tends to be poorly differentiated ductal carcinoma with a solid growth pattern and no secretory features (1,3). We aimed to present a new case with invasive CHDC to the literature.

Case history

A 40-year-old woman presented with a palpable mass in her left breast, noticed a month ago. Physical examination revealed a

painless, mobile, soft, 2×2×1 cm diameters and palpable mass in the upper inner quadrant of the left breast. There was no retraction of the nipple or lymphadenopathy. The patient had no history of benign breast disease previously or family history of the breast cancer. Mammography and ultrasonographic findings were in accordance with fibroadenoma. The cytologic examination of the fine needle aspiration biopsy (FNAB) of the mass was reported to be non-diagnostic. At this, an excisional biopsy of left breast was performed , revealing a 3×2×1 cm mass. Specimen showed a tumour 2 cm diameter that was firm in consistency with a glossy surface. The initial diagnosis established in frozen sections was fibrocystic change with focal apocrine metaplasia. Microscopically the following features were apperant back to back cysts lined by columnar pseudostratified epithelium and focal papillary projections. The lumen of multiple cysts contained dense eosinophilic material resembling thyroid colloid (Figure 1). Thyroglobulin immunohistochemistry was negative. This insitu hypersecretory

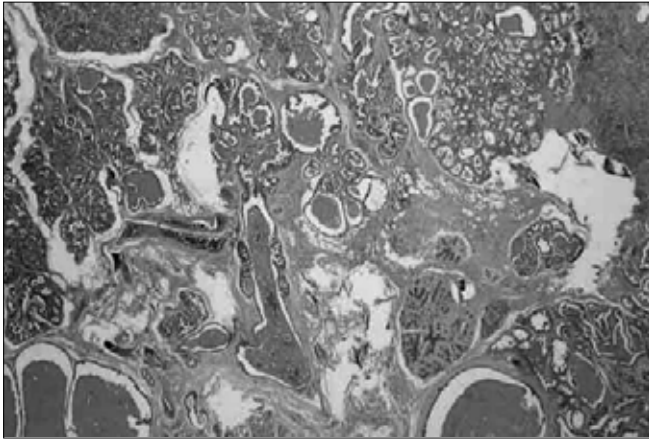


Figure 1. Figure reveals the presence of cyst and ducts containing a colloid-like secretion. The epithelium shows a micropapillary pattern. HE x 22.

components was accompanied by an invasive component solid pattern of moderately to poorly differentiated ductal carcinoma cells (Figure 2). The estrogen and progesteron receptors were negative.

The patient subsequently underwent quadrantectomy and axillary dissection as the patient refuse the modified radical mastectomy. No residual tumor was observed in the quadrantectomy material. Axillary lymph nodes were 0/11. No complication was observed during the postoperative period and radiotherapy underwent to the patient. During 18 months follow-up, no local recurrence or metastasis was developed.

Discussion

Cystic hypersecretory lesions of the breast are rare, with less than 40 cases describe up to now, mostly as case reports (1). The differential diagnosis of CHDC from the other malign and benign lesions of the breast is very important. It can be mixed with the fibrocystic changes along with the microcystic formation of the breast. The absence of colloid-like secretions or micropapillary formations within the cyst and the presence of benign epithelial lining and apocrine metaplasia is helpful in the differential diagnosis of the fibrocystic disease and CHDC. Juvenile papillomatosis, sclerosing adenosis, papillary hyperplasia and ductal papillomatosis called "swiss cheese" in adolescents differs from CHDC with atypia in various degrees. However, especially the differential diagnosis of CHDC among younger patients by, fine needle aspiration biopsy could be difficult. Though being rare, mucocel like lesions could imitate CHDC when examined by low power microscope and when the lesion is accompanied by papillary hyperplasia. The mucinous content formed by the extravasation of the mucin within the stoma could be helpful in the differential diagnosis of this disease from CHDC. Metastatic thyroid cancer could be differentiated by clinical history and the positivity of the immune painting for thyroglobuline (4-6).

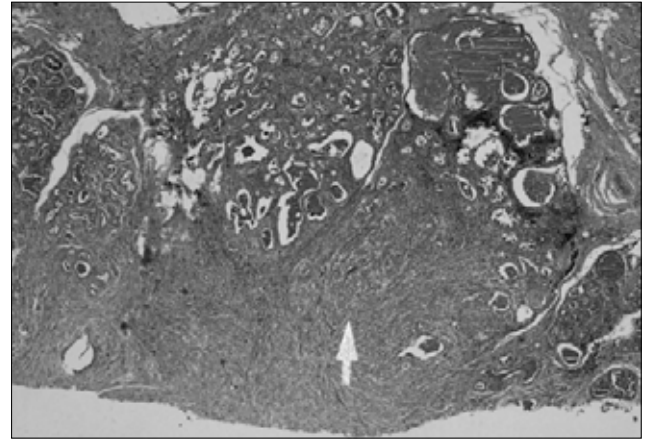


Figure 2. Typical features of invasive cystic hypersecretory carcinoma of breast with invasive pattern. HE x 22.

Although invasive carcinomas are usually low-graded, higher graded or invasive carcinoma could be seen rarely. The characteristic finding in invasive CHC are dilatation of the ductal formations and dilated ducts filled with eosinophilic materials like colloid in their lumens along with invasive carcinoma foci. Invasive CHC must be differentiated from secretory carcinoma, mucinous carcinoma, malign tumors resembling mucocele and metastatic thyroid carcinoma (2,4).

The usual clinical presentation of CHDC is a palpable abnormality with localized pain and, rarely, nipple discharge. Differential diagnosis of invasive CHC from other breast disease is impossible clinically because of these non-specific symptoms. Likewise, there is no specific radiological finding in the establishment of the invasive CHC diagnosis. Mammography typically shows a single, irregular spiculated mass that occasionally contains calcifications. Sonography reveals a hypoechoic mass with internal hyperechoic foci, microcysts, and dilated ducts (6-8). For this reason, the definite diagnosis can only be established with the histopathological examination of the biopsy material.

FNAB may not always be helpful in the establishment of the malignity diagnosis, but a more definitive diagnosis should be obtained through a core biopsy (6,9). Usually, this is because of the sampling errors as also been observed in our case. Excisional biopsy must be performed when the FNAB is not enough for the diagnosis of CHC.

Although locoregional and distant metastases from the secretory carcinoma are extremely rare, they are nevertheless possible. For the correct staging of the disease, therefore, it is necessary to verify the possible presence of sytemic and/or axillary lymph node metastases. There is still considerable discussion about the indications for a complete axillary lymph node dissection. Since the secretory carcinoma has a low metastatic capacity, it is obvious that a total axillary lymphadenectomy performed on principle would be in fact a form of over-treatment for this

particular disease stage. The frequently-reported post-operative complications of axillary dissection such as pain, parasthesia, seroma, difficulty of shoulder movements and lymphedema of the upper arm are all further valid reasons for a cautious approach towards this therapeutic choice. In the last few years, in order to avoid where possible the complete dissection of the axillary fossa in ductal and lobular breast cancer, a biopsy of the sentinel lymph node is usually performed (10). We have not equipment to detect sentinel lymph node and we had to perform axillary

lymph node dissection to the patient. At the end of the follow-up period of 18 months no local recurrence or metastasis was observed.

In summary, secretory carcinoma of the breast is a rare but histologically distinct variant of invasive ductal carcinoma that has a slow growth pattern and a good prognosis. There are no specific imaging characteristics, FNAB and frozen. Excisional biopsy must be performed for the diagnosis of CHC.

Kaynaklar

1. Skalova A, Ryska A, Kajo K, Di Palma S, Kinkor Z, Michal M. Cystic hypersecretory carcinoma: rare and poorly recognized variant of intraductal carcinoma of the breast. Report of five cases. *Histopathology* 2005; 46:43-9. (PMID: 15656885)
2. Rosen PP, Scott M. Cystic hypersecretory duct carcinoma of the breast. *Am J Surg Pathol* 1984; 8:31-41. (PMID: 6320685)
3. Herrmann ME, McClatchey KD, Siziopikou KP. Invasive cystic hypersecretory ductal carcinoma of breast: a case report and review of the literature. *Arch Pathol Lab Med* 1999; 123:1108-10. (PMID: 10539918)
4. Lee JS, Lee YJ. Invasive cystic hypersecretory carcinoma of the breast: a case report. *J Korean Med Sci* 2004; 19:149-51. (PMID: 14966360)
5. Shin SJ, Rosen PP. Carcinoma arising from preexisting pregnancy-like and cystic hypersecretory hyperplasia lesions of the breast: a clinicopathologic study of 9 patients. *Am J Surg Pathol* 2004; 28:789-93. (PMID: 15166671)
6. Resetkova E, Padula A, Albarraccin CT, Sneige N. Pathologic quiz case: a large, ill-defined cystic breast mass. Invasive cystic hypersecretory duct carcinoma. *Arch Pathol Lab Med* 2005; 129:e79-80 (PMID: 15737055)
7. Colandrea JM, Shmookler BM, O'Dowd GJ, Cohen MH. Cystic hypersecretory duct carcinoma of the breast. Report of a case with fine-needle aspiration. *Arch Pathol Lab Med* 1988; 112:560-3. (PMID: 2833875)
8. Park C, Jung JI, Lee AW, Cheon HM, Hahn ST, Lee JM. Sonographic findings in a patient with cystic hypersecretory duct carcinoma of the breast. *J Clin Ultrasound* 2004; 32:29-32. (PMID: 14705175)
9. Schmitt F, Tani E. Cytological findings in cystic hypersecretory ductal carcinoma of the breast: a potential pitfall in mammary cytology. *Cytopathology* 2000; 11:513-9. (PMID: 11194083)
10. Vieni S, Cabibi D, Cipolla C, Fricano S, Graceffa G, Latteri MA. Secretory breast carcinoma with metastatic sentinel lymph node. *World J Surg Oncol* 2006; 6:88. (PMID: 17150092)

İletişim

Erdoğan Kamer
Tel : +90 232 244 44 44
Faks : +90 232 243 48 48
E-Posta : erdinc.kamer@gmail.com