

EXTRAMAMMARY PAGET'S DISEASE OF THE AXILLA

Erdinc Kamer¹, Mustafa Peskersoy¹, Haluk Unalp¹, Murat Ermete², Mehmet Ali Onal¹

¹Izmir Ataturk Training and Research Hospital, Department of Surgery, Izmir, Turkey

²Izmir Ataturk Training and Research Hospital, Department of Pathology, Izmir, Turkey

ABSTRACT

Extramammary Paget's disease is a very rare disease, often involving the skin of the genital or perianal regions. Axillary Paget's disease, however, is very rare with few cases reported in the literature. We reported a case of an extramammary Paget's disease of the axilla in a 72-year-old female.

Key words: Extramammary Paget's disease, axilla, case report

AKSILLANIN MEME DIŐI PAGET HASTALIĐI

ÖZET

Meme dıŐı Paget hastalıđı nadir görölür ve sıklıkla genital ya da perianal bölgenin derisinde rastlanır. Aksillar Paget hastalıđı ile ilgili literatürde oldukça az olgu sunulmuŐtur. Biz aksillanın meme dıŐı Paget hastalıklı 72 yaŐında bayan bir olguyu sunduk.

Anahtar sözcükler: Meme dıŐı Paget hastalıđı, aksilla, olgu sunumu

Extramammary Paget's disease (EMPD), first described by Crocker in 1889, is a rare heterogeneous group of cutaneous tumors (1,2). Therefore, common locations include the vulva, penis, scrotum, anus, anal margin, and perianal region (3). Extramammary Paget's disease of the axilla, however, is very rare with few cases reported in the literature (4).

The typical clinical presentation is usually a pruritic, slowly enlarging, eczematous plaque. Histologically, it is characterized by intraepidermal proliferation of adenocarcinoma cells that are identical to those of classic mammary Paget's disease (5). We reported a case of an extramammary Paget's disease of the axilla in a 72-year-old female.

Case

A 72-year-old female presented with a 6-months history of an enlarging pink plaque on the right axilla. The patient denied any associated symptoms. She had no medical and family history. On physical examination, a 4 × 5 cm poorly circumscribed, erythematous patch on the right axilla was noted. The breasts were symmetrical bilaterally, with no nodules in either breast and no evidence of any nipple inversion, excoriation or discharge. There was no evidence of any lymphadenopathy. Mammography and breast ultrasonography were negative for malignancy. A punch biopsy revealed pagetoid infiltration of the epidermis by atypical cells that displayed hyperchromatic nuclei and moderately abundant

cytoplasm (Figure 1). Tumor cells stained positive for Alcian blue (AB) (Figure 2), cytokeratine-7 (CK-7) (Figure 3), carcinoembryonic antijen (CEA), epithelial membrane antigen (EMA), gross cystic disease fluid protein-15 (GCDFP-15) (Figure 4) and negative for S-100 and cytokeratine 20 (CK-20). These findings led to the diagnosis of EMPD of the axilla. Given that EMPD may be associated with invasive disease, wide local excision of the lesion was performed. The pathology confirmed the diagnosis of EMPD of the axilla. The immunohistochemical profile was similar to the previously performed punch biopsy. No tumor was identified in dermal or subcutaneous tissue, and no vascular invasion was found. The patient did not receive any further adjuvant therapy. She is currently alive and well, with no evidence of disease 6 months postoperatively.

Discussion

Extramammary Paget's disease, first reported by Crocker, (1,2) is a rare disease primarily found in sites with a high density of apocrine glands (3). There is no consensus on the true etiology of this neoplasm (6). Extramammary Paget's disease of the axilla, however, is very rare with few cases reported in the literature (4).

Extramammary Paget's disease affects extramammary Paget's disease of the axilla with slight female predominance (6). The mean age at diagnosis was 74 and 72 years for invasive and non-invasive EMPD, respectively (7). Extramammary Paget's disease of the generally present as an eczematous plaque that may become pruritic. The

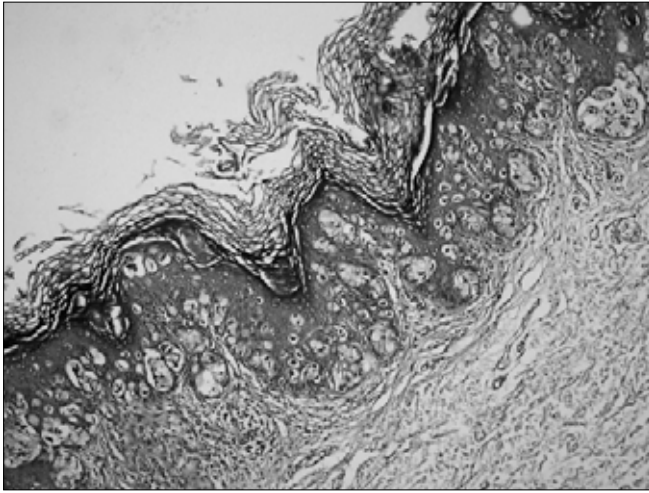


Figure 1. High power photomicrograph of H & E stained slide demonstrating Paget's cells (120 ×).

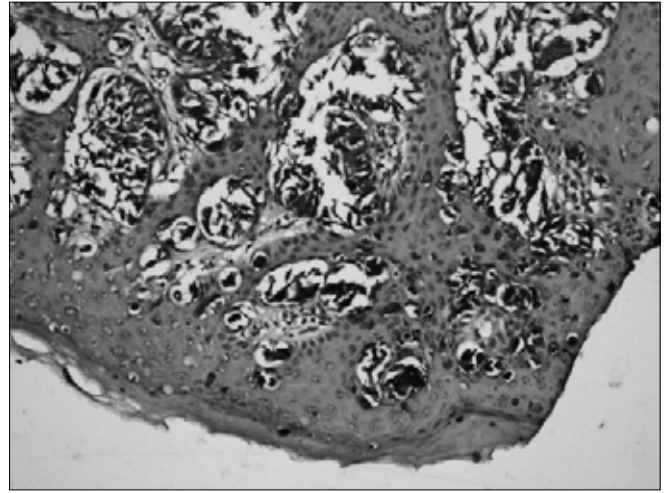


Figure 3. The Paget's cells were positive for CK-7 (×240).

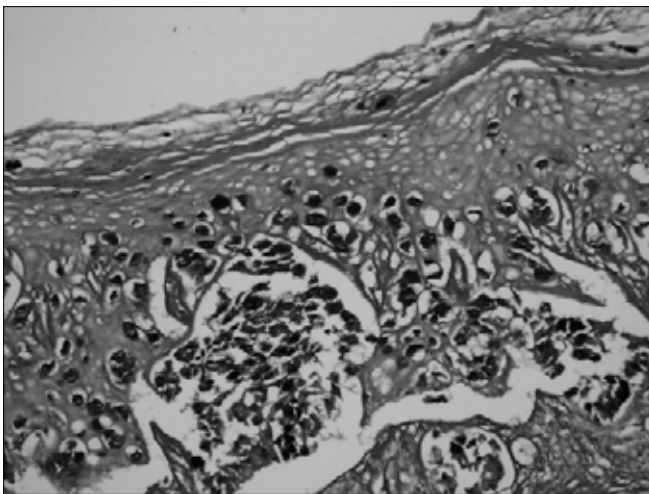


Figure 2. The Paget's cells were positive for AB (×240).

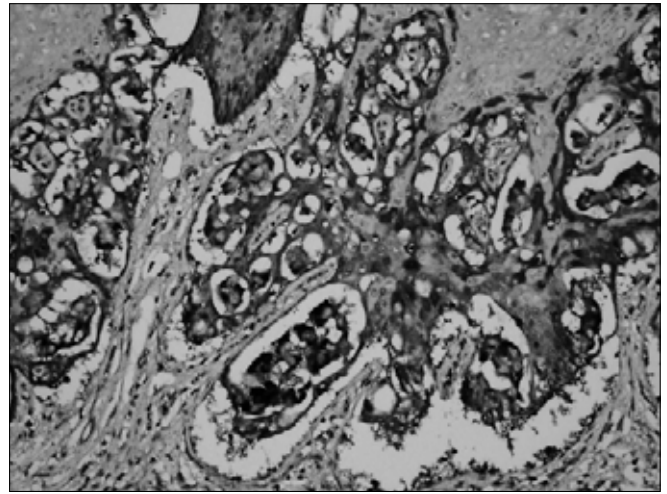


Figure 4. The Paget's cells were positive for GCDFP-15 (×240).

plaque may be either hyper- or hypopigmented. It may be associated with a palpable mass, but is often limited to the skin alone (4).

The diagnosis of EMPD is made with a skin biopsy demonstrating a thickened epidermis with large cells with abundant fine granular cytoplasm and a large centrally situated nucleus with nuclear atypia. The differential diagnosis includes superficial spreading malignant melanoma, Bowen's disease, mycosis fungoides, Langerhans cell histiocytosis and Spitz nevus (4,8). Thus, special stains and immunohistochemistry may be necessary in establishing the diagnosis. Immunohistochemical techniques can also identify Paget's cells. An immunohistochemical panel such as CEA, low-molecular-weight cytokeratin, high-molecular-weight cytokeratin, EMA and S-100 protein is useful in differentiating Paget's disease from melanoma and pagetoid Bowen's disease (1,6). Histologic evaluation is critical in establishing the diagnosis. Tumor cells have abundant pale cytoplasm, large pleomorphic nuclei and occasionally prominent nucleoli. Cells may also have eccentric nuclei and the appearance

of a signed ring. An important consideration in patients with EMPD is the incidence of concurrent secondary malignancies, such as adnexal carcinoma and internal malignancy (9).

Both surgical and non-surgical treatments have been described. EMPD is generally treated with wide excision, and the prognosis is generally favorable (10). Non-surgical therapies include topical 5-fluorouracil, topical bleomycin, radiotherapy and laser. These treatments all have varying degrees of success.

In conclusion, extramammary Paget's disease is a very rare disease entity and the risk of associated malignancy is not well characterized. Thus, as with EMPD, a thorough physical examination including rectal, pelvic, and breast exam, as well as palpation of lymph nodes should be performed. EMPD is generally treated with wide excision, and the prognosis is generally favorable.

References

1. Cohen MA, Hanly A, Poulos E, Goldstein GD. Extramammary Paget's disease presenting on the face. *Dermatol Surg* 2004; 30:1361-3. (PMID: 15458537)
2. Crocker HR. Paget's disease affecting the scrotum and penis. *Trans Pathol Soc London* 1889;40:187-91.
3. Heymann WR. Extramammary Paget's disease. *Clin Dermatol* 1993;11:83-7. (PMID: 8393362)
4. Chagpar AB, Heim K, Carron KR, Sewell C. Extramammary Paget's disease of the axilla: an unusual case. *Breast J* 2007;13:291-3. (PMID: 8393362)
5. Chen S, Moroi Y, Urabe K, Takeuchi S, Kido M, Hayashida S, Uchi H, Uenotsuchi T, Tu Y, Furue M. Differential expression of two new members of the p53 family, p63 and p73, in extramammary Paget's disease. *Clin Exp Dermatol* 2008;33:634-640. (PMID: 18627398)
6. Iwenofu OH, Samie FH, Ralston J, Cheney RT, Zeitouni NC. Extramammary Paget's disease presenting as alopecia neoplastica. *J Cutan Pathol* 2008;35:761-4. (PMID: 18422977)
7. Siesling S, Elferink MA, van Dijck JA, Pierie JP, Blokk WA. Epidemiology and treatment of extramammary Paget disease in the Netherlands. *Eur J Surg Oncol* 2007;33:951-5. (PMID: 17215101)
8. Lloyd J, Flanagan AM. Mammary and extramammary Paget's disease. *J Clin Pathol* 2000;53:742-9. (PMID: 11064666)
9. Chanda JJ. Extramammary Paget's disease: prognosis and relationship to internal malignancy. *J Am Acad Dermatol* 1985;13:1009. (PMID: 11064666)
10. Pierie JP, Choudry U, Muzikansky A, Finkelstein DM, Ott MJ. Prognosis and management of extramammary Paget's disease and the association with secondary malignancies. *J Am Coll Surg* 2003;196:45-50. (PMID: 12517548)

İletişim

Erdiñç Kamer
Tel : 0(232) 2444444
E-Posta : erdinc.kamer@gmail.com