

## CONVENTIONAL LIPOSUCTION FOR GYNECOMASTIA TREATMENT IN SELECTED PATIENTS

**Yakup Çil**

*Eskişehir Asker Hastanesi, Plastik Cerrahi, Eskişehir, Türkiye*

### ABSTRACT

**Objective:** Perfect surgical technique for gynecomastia treatment has not been established although several method have been described. Liposuction is very useful method however skin excess remains as a challenge for gynecomastic breast treatment.

**Materials and Methods:** Prospectively; 9 selected patients (6 bilateral, 3 unilateral breasts) who were operated for gynecomastia with conventional liposuction between 2005 and 2007 years period were included in this study. Patients' mean age were 22 (19-28). All surgeries were performed under general anaesthesia. The breast tissue was infiltrated, with a single stab incision throughout the medial inframammary crease, following a superwet/tumescent technique.

**Results:** The mean infiltration volume per breast taken with the suction assisted liposuction was 250 ml (150-400 ml) and mean aspiration volume per breast was 280 ml (175-480 ml). The mean application time per breast for liposuction was 13 minutes (10-18 min). Following the procedure; the patient was instructed to wear a pressure garment during day and night for 6 weeks. The mean follow-up time for each case was 1 year.

**Conclusion:** The conventional liposuction for gynecomastia treatment is very effective for patients with soft breast tissue enlargement.

**Key words:** Gynecomastia, liposuction, conventional technique

### SEÇİLMİŞ HASTALARDA KLASİK YAĞ EMME YÖNTEMİ İLE JİNEKOMASTİ TEDAVİSİ

#### ÖZET

**Amaç:** Jinekomasti tedavisi için deđişik cerrahi yöntemler tarif edilmesine rağmen; tedavide kullanılabilecek mükemmel bir cerrahi teknik tarif edilmemiştir. Jinekomastik memedeki cilt fazlalığı sorununa rağmen tedavide yağ emme yönteminin kullanılması faydalı gözükmektedir.

**Gereç ve Yöntem:** Çalışmada prospektif olarak; 2005-2007 yılları arasında jinekomasti nedeniyle klasik yağ emme yöntemi uygulanan 9 seçilmiş hastaya (6 iki taraflı, 3 tek taraflı jinekomasti) ait tecrübelerimiz aktarıldı. Hastaların ortalama yaşı 22 (19-28) olup; tüm hastalarda yağ emme işlemi genel anestezi altında uygulandı. Superwet/Tumesan tekniğine uygun olarak hazırlanan yağ emme solüsyonu meme altı kıvrımı medialinden yapılan kesi ile meme dokusu içine verildi.

**Bulgular:** Verilen ortalama yağ emme solüsyonu miktarı 250 ml (150-400 ml); alınan aspirasyon materyeli ortalama 280 ml (175-480 ml) olarak bulundu. Her meme için ortalama yağ emme süresi 13 dakika (10-18 dakika) olarak bulundu. Hastalara ameliyattan sonra 6 hafta gece ve gündüz göğüs bölgesine bası yapacak giysi giymesi öğretilti. Hastalar ortalama 1 yıl (8-15 ay) takip edildi.

**Sonuç:** Klasik yağ emme yöntemi; geniş yumuşak meme dokusuna sahip jinekomastili hastaların tedavisinde oldukça etkilidir.

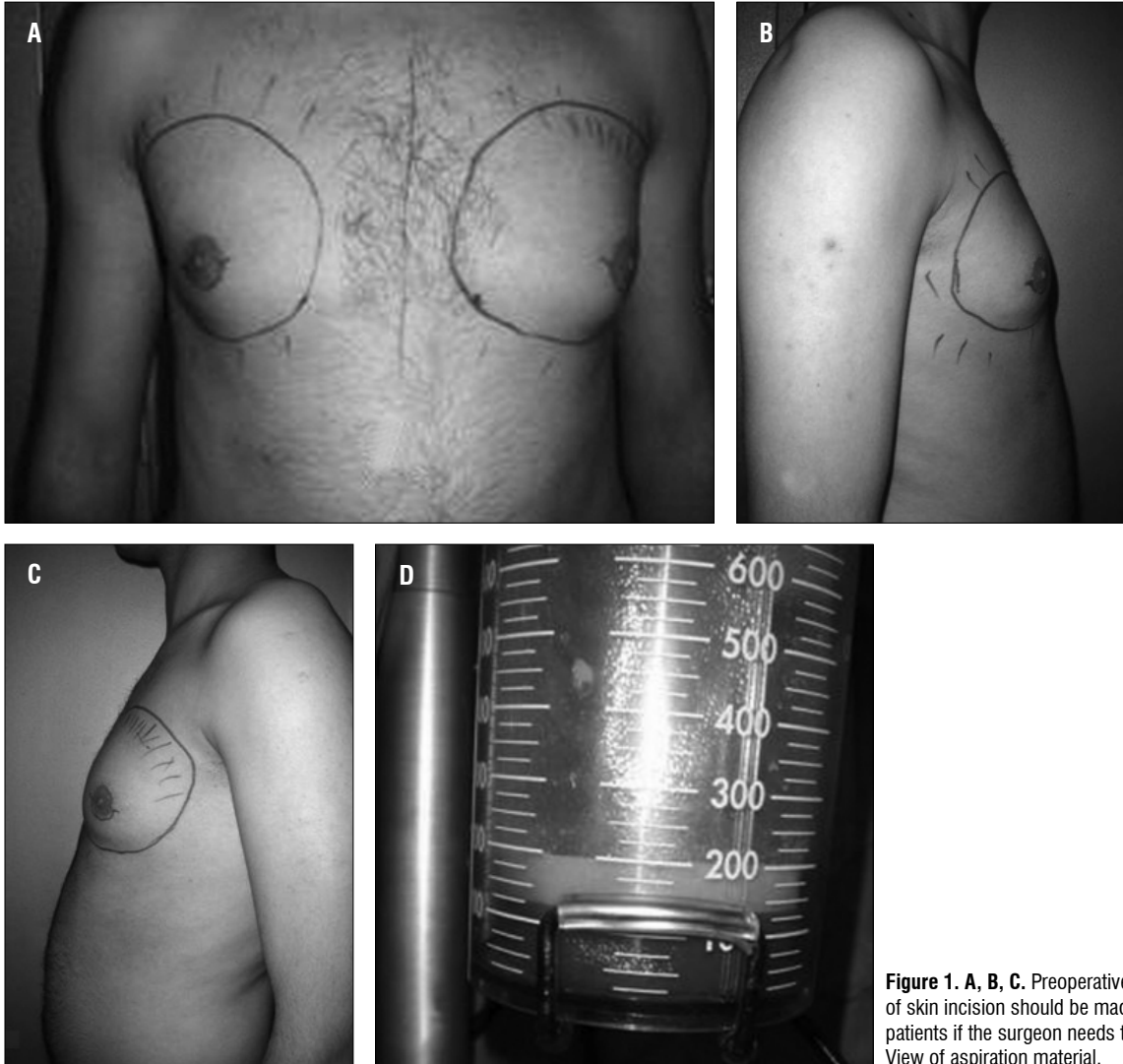
**Anahtar sözcükler:** Jinekomasti, yağ emme, klasik yöntem

The first reported surgical treatment of gynecomastia belonged to Paulus Aegineta (625-690 AD), who used a lunate incision below the breast for large breasts, two converting lunate incisions to enable to excise the excess skin (1). Webster; later in 1946, described an operation with a semicircular intra-areolar incision (1), which has become the standard operation for excision of gynecomastia. Later on another method has been introduced the skin is removed as an ellipse, and the nipple is transposed on a pedicle (2,3). Recently; Illouz in the late 1970s (4) described the suction-assisted liposuction and this technique has gained widely acceptance for many conditions (5,6). Liposuction

is very useful method, although skin excess remains a challenge. 9 patients (15 breasts) who were operated on for gynecomastia management with conventional liposuction technique are presented here.

### Materials and methods

9 selected patients who were operated for gynecomastia between 2005 and 2007 were included in this study. Patients' mean age were 22 (19-28). The grade of gynecomastia was assessed from the patients' preoperative photographs and case notes. Accord-



**Figure 1. A, B, C.** Preoperative surgical plan, marking of skin incision should be made preoperatively in all patients if the surgeon needs to alternate operation **D.** View of aspiration material.

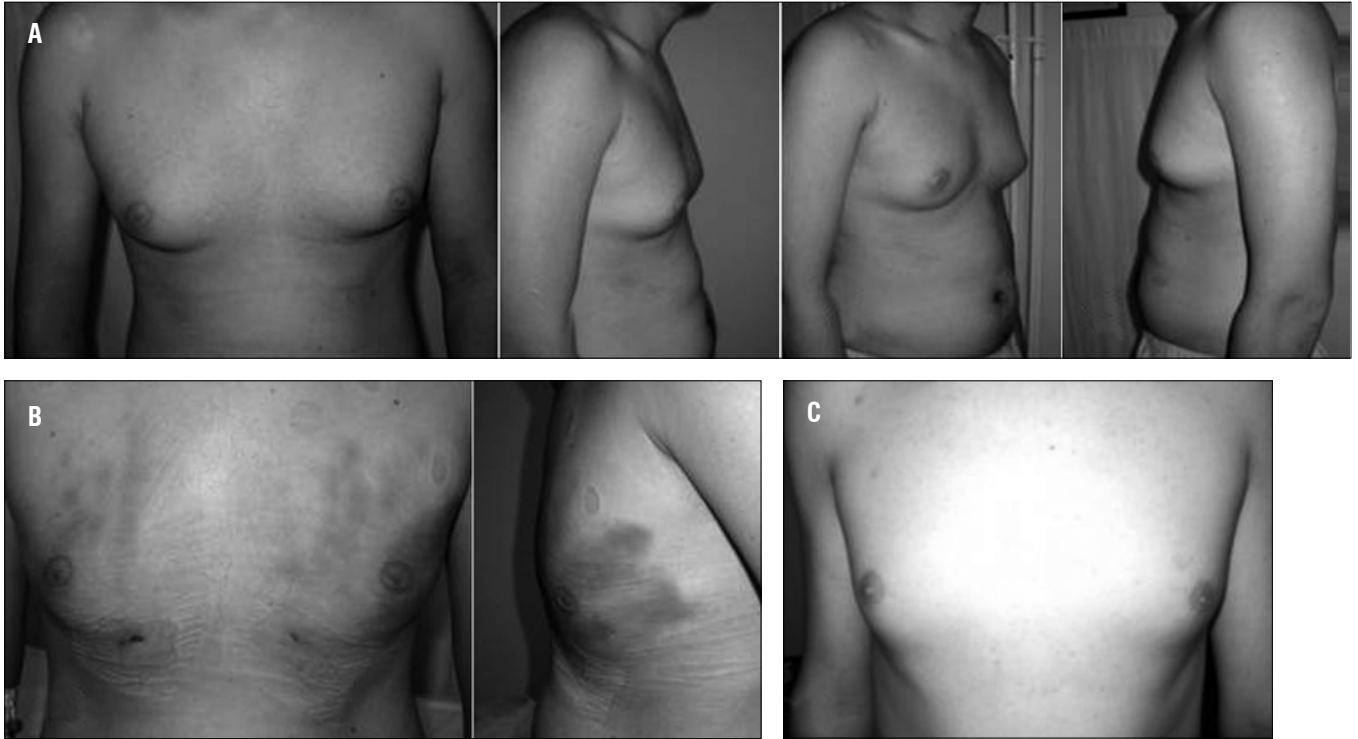
ing to Simon classification (7); 12 breasts had moderate-to-large and, 3 breasts had small-to-moderate size degree gynecomastia. All patients were examined by an internal medicine specialist for endocrin status. Patients who had endocrin problems were not included in this study. Only the young-age patients who had soft enlargement of breast were included in the study. Following surgery, patients were checked on outpatient basis. All patients were examined by the same surgeon, preoperative and postoperatively and, photographs were taken.

**Operative techniques:** Preoperatively breast of all patients were marked in the upright sitting position (Figure 1). All surgeries were performed under general anaesthesia. The breast tissue was infiltrated with a single stab incision in the medial inframammary crease, with a solution of Ringer's lactate, 1 litre of which contained 30 ml of %1 lidocaine and 1 ml of 1:1000 adrenaline, using a superwet/tumescent technique. After infiltration, a suction cannula was inserted through the medial inframammary crease. A

5.2 mm Mercedes cannula was used for the initial suction by the palm down and pinch techniques (Figure 1). The final contouring was performed with a 3.7 mm Mercedes cannula. During suction, contour changes were constantly assessed by direct observation. A close watch was also kept on the colour and volume of the aspirate. Once a satisfactory contour was obtained, the surrounding fat was aspirated to avoid a significant saucer deformity and, the inframammary fold was disrupted. Intraoperatively, the patient received one dose of intravenous broad-spectrum antibiotic, which was continued twice a day orally for 5 days. Following the procedure, a pressure dressing was applied on the chest. The patient was instructed to wear a pressure garment during day and night for 6 weeks.

## Results

9 patients underwent conventional liposuction surgery for gynecomastia over the 24 months period. Their age ranged from 19 years to 28 years (mean: 22 years). 6 patients presented with bi-



**Figure 2.** A. Preoperative view of a 19-year-old patient treated with conventional liposuction for bilateral gynecomastia B. early postoperative view C. late postoperative view.

lateral and 3 patients with unilateral gynecomastia. In total 15 breasts were treated with conventional liposuction (Figure 2,3,4) (Table 1).

The mean infiltration volume per breast with suction assisted liposuction was 250 ml (range: 150-400 ml) and mean aspiration volume per breast was 280 ml (range: 175-480 ml). The mean application time per breast for liposuction was 13 min (range: 10-18 min). The mean follow-up time was 1 year (range: 8-15 months) (Table 2).

There was no hematoma, seroma, infection or other kind of early postoperative complications. We found that 7 patients (% 77) were very satisfied with their cosmetic outcome. Two patients were not satisfied (1 unilateral, 1 bilateral gynecomastia). Therefore, these patients were reoperated with open excision method.

**Table 1.** Degree of gynecomastia. \* According to Simon classification.

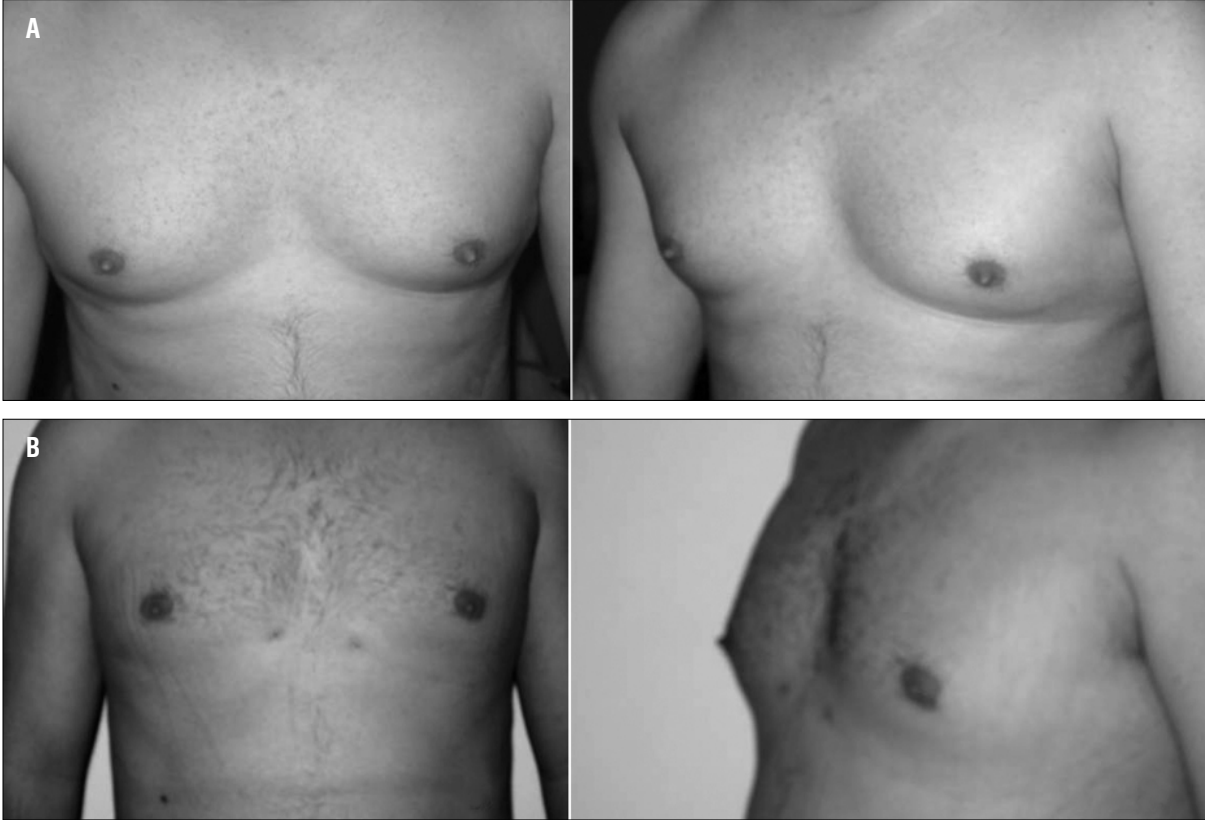Degree of gynaecomastia	Number of breasts
small-to-moderate	3
moderate-to-large	12
total	15

## Discussion

Gynecomastia is a common condition, with a prevalence in young patient as high as 38 % (8). It may be caused by estrogen-testosterone ratio imbalance (9). Treatment of any underlying cause is important, but may fail to stop the breast enlargement, especially if it has been present for long time (10). There are many surgical techniques currently available in the literature. Webster; later in 1946, described an operation with semicircular intra-areolar incision (1) which has become the standard surgical operation for excision of gynecomastia till now. Over the following years, numerous approaches to resect the excess skin were described. Skin has been removed as an ellipse, and the nipple transposed on a pedicle (2,3) or repositioned as a full-thickness graft (11). Redundant skin has also been excised concentrically around the nipple

**Table 2.** Results of gynecomastia treatment with conventional liposuction.

	Minimum	Maximum	Mean
Infiltration tumescan fluid volume	150 ml	400 ml	250 ml
Aspiration volume	175 ml	480 ml	280 ml
Follow-up	8 months	15 months	1 year
Operation time (Each breast)	10 minutes	18 minutes	13 minutes



**Figure 3.** A. Preoperative view of a 21-year-old patient treated with conventional liposuction for bilateral gynecomastia B. postoperative view.

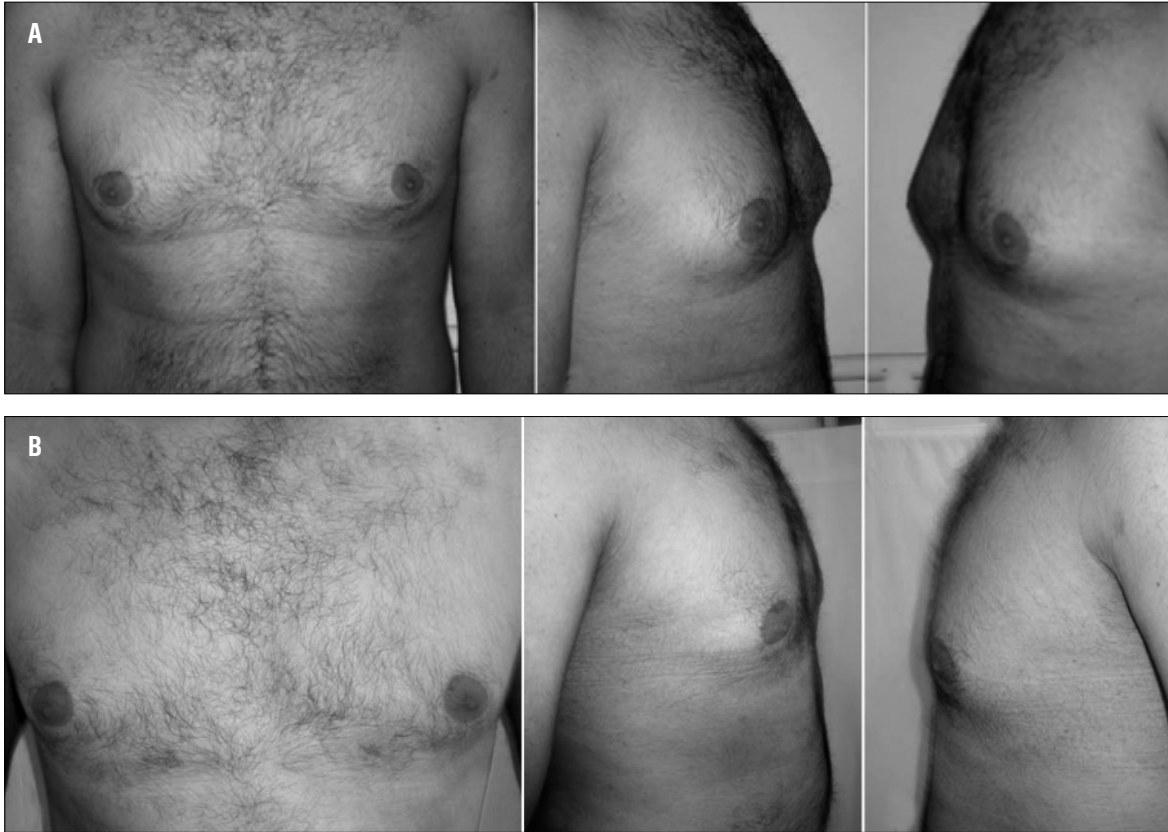to avoid extra-areolar scar; keeping it on superior (12,13) or central (14) pedicle. The surgeon faced with a wide range of excisional procedures, but no single technique is suitable for all forms of gynecomastia.

Illouz in the late 1970s (4) described the suction assisted liposuction (conventional liposuction). This method has gained wide acceptance and popularity for many advantages (5,6). This method was appreciated useful in gynecomastia treatment. However, all types of gynecomastia can not be treated with conventional liposuction. In the late 1980s Zocchi developed ultrasound-assisted liposuction, a technique that allows selective destruction of adipose tissue (15). Ultrasound-assisted liposuction is a relatively new technique. In this technique, electrical energy is transmitted from the power console to a hand piece containing a piezoelectric crystal which transformed into mechanical vibrations, by a metal probe to the tissue (15). Although several theories have been introduced to describe the mechanism of ultrasound assisted liposuction, no general agreement has been reached on it (16). However; Ultrasound-assisted liposuction reduces the surgeon's mechanical effort. Fodor and Watson performed a prospective study comparing conventional and ultrasound-assisted liposuction, and found no difference in patient satisfaction, postoperative ecchymosis, swelling, complication rate or skin contracture (17).

Liposuction alone is not suitable for gynecomastia treatment many authors. For this reason; conventional liposuction combined with open excision was described by Teimourian and Perlman in 1983 (18). This combination has been a widely accepted, because of the frequent difficulty of removing breast parenchyma by suction alone (19-22). Rosenberg treated gynecomastia with 2.3 mm liposuction's cannula (22,23). We also agree with his preferred method. If the surgeon uses large caliber cannula while liposuction is performed; cannula could not obliterate breast paranchimal tissue. We also think that large cannula destroys more breast tissue despite giving the opportunity for easy suction.

Many authors have used special cutting gynecomastia cannulas, such as the cutting cannula with a sharp opening or a biopsy punch (24). We do not prefer this method; since these cannulas are more likely traumatic, and make damages to blood vessels and nerves. This method's clear advantage over open excision is doubtful. We generally prefer to convert operation to open excision when liposuction was not effective.

Simon et al. classified gynecomastia according to the size of the breast and the amount of redundant skin (7). They defined four categories: small enlargement with no skin redundancy, moderate enlargement with no skin redundancy, moderate enlargement with skin redundancy and marked enlargement with marked skin



**Figure 4. A.** Preoperative view of a 23-year-old patient treated with conventional liposuction for bilateral gynecomastia **B.** postoperative view.

redundancy. Majority of our patients were classified as moderate enlargement with skin redundancy. We thought that marked enlargement with marked skin redundancy was not suitable for conventional liposuction. Open techniques or combination methods are more useful for marked enlargement with marked skin redundancy.

We preferred to use liposuction for young patients. According to our past experience classical liposuction is not effective in older age patients since the relatively less their paranchimal tissues are more firm. Younger patient's breast paranchyme also are softer due to fibrous paranchimal tissues. Marking of skin to excise should be made preoperatively in all patients if the surgeon needs to convert the operation.

#### References

1. Fruhstorfer BH, Malata CM. A systematic approach to the surgical treatment of gynecomastia. *Br J Plast Surg.* 2003;56(3):237-46. (PMID: 12859919)
2. Letterman G, Schurter M. Surgical correction of massive gynecomastia. *Plast Reconstr Surg.* 1972;49(3):259-62. (PMID: 5060315)
3. Brenner P, Berger A, Schneider W, Axmann HD. Male reduction mammoplasty in serious gynecomastias. *Aesthetic Plast Surg* 1992;16:325-30. (PMID: 1414657)

In our cases, we have seen that after the classical liposuction for gynecomastia treatment; edema takes more time to resolve than other body areas treated with liposuction. We advice that the patient should use special compressive garment for long time postoperatively. Following the procedure, our patients were instructed to wear a pressure garment whole day and night for 6 weeks.

#### Conclusion

Gynecomastia treatment with liposuction technique yielded satisfactory outcomes causing only small skin scar. However, it should be kept in mind that all types of gynecomastia can not be treated with conventional liposuction. The conventional liposuction for gynecomastia treatment is especially very effective in young patients with soft breast tissue enlargement.

4. Illouz Y-G. Body contouring by lipolysis: a 5-year experience with over 3000 cases. *Plast Reconstr Surg.* 1983;72(5):591-7. (PMID: 6622564)
5. Babovic S, Bite U, Karnes PS, Babovic-Vuksanovic D. Liposuction: a less invasive surgical method of debulking plexiform neurofibromas. *Dermatol Surg.* 2003;29(7):785-7. (PMID: 12828709)
6. Dhami LD, Agarwal M. Safe total corporal contouring with large-volume liposuction for the obese patient. *Aesthetic Plast Surg.* 2006;30(5):574-88. (PMID: 16977358)

7. Simon BE, Hoffman S, Kahn S. Classification and surgical correction of gynecomastia. *Plast Reconstr Surg.* 1973;51(1):48-52. (PMID: 4687568)
8. Nuttall FQ. Gynecomastia as a physical finding in normal men. *J Clin Endocrinol Metab.* 1979;48(2):338-40. (PMID: 429488)
9. Mathur R, Braunstein GD. Gynecomastia: pathomechanisms and treatment strategies. *Horm Res.* 1997;48(3):95-102. (PMID: 11546925)
10. Hands LJ, Greenall MJ. Gynaecomastia. *Br J Surg* 1991;78:907-11. (PMID: 1913103)
11. Wray RC, Hoopes JE, Davis GM. Correction of extreme gynaecomastia *Br J Plast Surg* 1974;27:39-41. (PMID: 4817146)
12. Davidson BA. Concentric circle operation for massive gynecomastia to excise the redundant skin. *Plast Reconstr Surg.* 1979;63(3):350-4. (PMID: 419211)
13. Persichetti P, Berloco M, Casadei RM, Marangi GF, Di Lella F, Nobili AM. Gynecomastia and the complete circumareolar approach in the surgical management of skin redundancy. *Plast Reconstr Surg.* 2001;107:948-54. (PMID: 11252087)
14. Huang TT, Hidalgo JE, Lewis SR. A circumareolar approach in surgical management of gynaecomastia. *Plast Reconstr Surg.* 1982;69:35-40. (PMID: 7053509)
15. Zocchi M. Ultrasonic liposculpturing. *Aesthetic Plast Surg.* 1992;16(4):287-98. (PMID: 1414652)
16. Young VL, Schorr MW. Report from the conference on ultrasound-assisted liposuction safety and effects. *Clin Plast Surg.* 1999;26(3):481-524. (PMID: 10549445)
17. Fodor PB, Watson J. Personal experience with ultrasound-assisted lipoplasty: a pilot study comparing ultrasound-assisted lipoplasty with traditional lipoplasty. *Plast Reconstr Surg.* 1998;101(4):1103-16. (PMID: 9514348)
18. Teimourian B, Perlman R. Surgery for gynecomastia. *Aesthetic Plast Surg* 1983;7:155-7. (PMID: 6637655)
19. Lewis CM. Lipoplasty: treatment for gynecomastia. *Aesthetic Plast Surg* 1985;9(4):287-92. (PMID: 4091085)
20. Courtiss EH. Gynecomastia: analysis of 159 patients and current recommendations for treatment. *Plast Reconstr Surg.* 1987;79(5):740-53. (PMID: 3575519)
21. Samdal F, Kleppe G, Amland PF, Abyholm F. Surgical treatment of gynaecomastia. Five years' experience with liposuction. *Scand J Plast Reconstr Hand Surg* 1994;28:123-30. (PMID: 8079119)
22. Gasperoni C, Salgarello M, Gasperoni P. Technical refinements in the surgical treatment of gynecomastia. *Ann Plast Surg.* 2000;44(4):455-8. (PMID: 10783108)
23. Rosenberg GJ. A new cannula for suction removal of parenchymal tissue of gynecomastia. *Plast Reconstr Surg.* 1994;94(3):548-51. (PMID: 8047610)
24. Luckey RC. Modified technique for correction of gynecomastia. *Plast Reconstr Surg.* 1992;89(4):767. (PMID: 1546102)

---

#### İletişim

Yakup Çil  
Tel : 0(222) 2204219  
Faks : 0(222) 2303433  
E-Posta : yakupcil@yahoo.com