

# NURSING CARE OF PATIENTS WITH RECONSTRUCTIVE BREAST SURGERY USING TRANSVERSE RECTUS ABDOMINIS MYOCUTANEOUS FLAP

Sevil Güler Demir, Hülya Bulut

Gazi Üniversitesi Sađlık Bilimleri Fakültesi Hemşirelik Bölümü, Ankara Türkiye

Bu çalışma, 28 Mayıs – 1 Haziran 2008 tarihleri arasında Antalya’da düzenlenen Ulusal Cerrahi Kongresi’nde poster bildiri olarak sunulmuştur.

## ABSTRACT

Mastectomy due to breast cancer is one of the most severe traumas a woman can experience in her lifetime. Women perceive themselves as “mutilated, incomplete, diseased, and unsightly” following a mastectomy; experience emotions of depression, despair, despondency, and anger; concern for the future; and undergo adaptation problems in their relations with family members and in their sex lives. In other words, breast cancer has the devastating effect of a “living nightmare” for many women.

Breast reconstruction surgery aims to reduce the nightmarish impact of breast cancer. The objective of breast reconstruction is to alleviate the woman’s feelings of being an “incomplete and crippled” person in the face of losing a sexual organ, despite the disease she has suffered.

Reconstructive breast surgery can be performed simultaneously with mastectomy, or at a later stage. One intervention often preferred today is a transverse rectus abdominis myocutaneous (TRAM) flap. The primary advantages of the TRAM flap are its ability to provide a permanent, natural breast contour, removal of excess fat in the lower abdomen (tummy-tuck), and tightening of the abdominal wall. However, prolonged recovery following a TRAM flap, loss of flap, abdominal weakness, difficulty in performing daily, routine activities, and the possible need for further plastic surgery to ensure symmetry with the other breast are among the disadvantages of the TRAM flap technique. All of these factors require careful selection and care of patients who will undergo reconstruction through TRAM flap.

Nursing care to be provided to patients with TRAM flaps involves flap monitoring, pain management, drain monitoring, prevention of possible complications, and home-care training of the patient.

**Keywords:** breast cancer, breast reconstruction, transverse rectus abdominis musculocutaneous flap, nursing care

## TRANSVERS REKTUS ABDOMİNİS MİYOKUTANÖZ FLEP İLE MEME REKONSTRÜKSİYONU UYGULANAN HASTALARDA HEMŞİRELİK BAKIMI

### ÖZET

Meme kanseri nedeniyle yapılan mastektomi ameliyatları, kadınların hayatı boyunca yaşayabilecekleri en büyük travmalardan biridir. Mastektomi sonrası kadınlar kendilerini “yarım, eksik, hastalıklı ve çirkin” olarak algılamakta, depresyon, çaresizlik, ümitsizlik, öfke duyguları yaşamakta, gelecek kaygısı duymakta, aile ilişkilerinde ve cinsel yaşamlarında uyum sorunları yaşamaktadır. Diğer bir deyimle meme kanseri bir çok kadın için “kabus” özelliđi taşımaktadır.

Meme kanserinin kabus olma özelliđi meme rekonstrüksiyonu ameliyatları ile büyük ölçüde azaltılmaya çalışılmaktadır. Meme rekonstrüksiyonunda amaç, bir cinsel organını kaybeden kadının yakalandığı hastalığa rağmen, kendisini “yarım ve sakat” bir insan olarak görmesine engel olmaktır.

Meme rekonstrüksiyonu ameliyatları mastektomi ile eş zamanlı veya daha geç dönemde yapılabilmektedir. Bu ameliyatlar arasında günümüzde sıklıkla tercih edilen yöntemlerden biri Transvers Rektus Abdominis Miyokutanöz (TRAM) kas – deri flebi kullanımıdır. TRAM flebin en önemli avantajı implant gerektirmeden kalıcı doğal bir meme kontürünün sağlanması, karın alt bölümündeki fazla yağların alınması ve karın duvarının gerginleştirilmesidir. Ancak TRAM flep kullanımı sonrası iyileşmenin uzun sürmesi, flep kaybı, abdominal zayıflık, günlük yaşam aktivitelerini gerçekleştirmede güçlük, diğer meme ile simetrisinin sağlanabilmesi için yeniden ameliyat olma gibi dezavantajlar görülebilmektedir. Tüm bunlar TRAM flep ile rekonstrüksiyon uygulanan hastaların özenle seçilmesini ve bakımını gerektirmektedir.

TRAM flep uygulanan hastalara verilecek hemşirelik bakımı, flep monitorizasyonunu, ağrı yönetimini, dren takibini, gelişebilecek komplikasyonların önlenmesini ve hastanın evde bakımına yönelik eğitimini içermektedir.

**Anahtar sözcükler:** meme kanseri, meme rekonstrüksiyonu, transvers rektus abdominis miyokutanöz flep, hemşirelik bakımı

## Breast cancer and breast reconstruction

Mastectomy operations performed as a result of breast cancer are one of the heaviest traumas women can encounter during their lifetime. In addition to losing one of their breasts after a mastectomy, women are compelled to live with a life-threatening disease.

Further, breast cancer threatens the patients’ self-confidence and impacts negatively on sexual function, self-perception, and consequently, their sense of womanhood (1). Women perceive themselves as “mutilated, incomplete, diseased, and ugly;” undergo emotions of depression, despair, despondency, hopelessness, an-

ger, anxiety, etc.; fear the future, and experience adaptation problems in their family relations and sex lives (2).

Breast reconstruction surgery aims to reduce these negative traits of breast cancer to a considerable extent. Breast reconstruction is a process in which a new breast is made by using implants, transplanting autologous tissue (muscle, skin, etc.) from other parts of the body, or a combination of these methods (3,4). Here, the objective is to prevent a woman who has lost a sex organ from regarding herself as "mutilated and crippled", despite being diagnosed with breast cancer. In this aspect, breast reconstruction emerges as a surgical intervention that affects the quality of living (5). It is thus possible to restore the normal appearance of patients and minimize the unpleasant feelings they experience (3).

In breast reconstruction surgery, synthetic implants (silicone prostheses), autologous tissue harvested from elsewhere on the body (latissimus dorsi muscle-skin flap, transverse rectus abdominis flap), or a combination of these methods can be used (6). These operations can be done simultaneously with mastectomy or at a later time (7).

Immediate breast reconstruction is preferred especially in cases of ductile carcinoma in situ, early-stage invasive breast cancers, or mastectomies done for risk reduction, and is performed during the same session as the mastectomy (8,9,10). Reconstructive surgery accompanying mastectomy has the advantage of a single intervention for both procedures, and therefore, a lower cost. Additional benefits include preservation of the breast skin and inframammary layers, use of scar-free skin flaps that have not been exposed to radiotherapy, and a reduced need for further interventions to adjust the size and shape of the breast (11). Patients feel the loss of a breast to a lesser degree and are happier about the esthetic outcome (10,12). However, this procedure also carries the disadvantages of having a limited time to decide about the operation, prolonged surgery, difficulty of ensuring coordination between two surgical teams, and the need to postpone, or inability to predict, adjunctive treatments (11).

Delayed reconstructive surgery is usually preferred in inflammatory cancers with widespread tumors, locally rooted, advanced-stage breast tumors, or in patients who will receive intensive post-operative chemotherapy and radiotherapy. Reconstruction is delayed until after completion of adjunctive therapy (8,9). Delayed breast reconstruction operations are advantageous in preventing the negative effects of radiotherapy and chemotherapy on the reconstruction. However, the need for expansive breast tissue for reconstruction, and the fragile, scarred nature of flap tissue after being subjected to radiotherapy lead to less satisfactory esthetic outcomes, prolonged hospitalization, and increased cost (10,11).

Today, breast reconstruction in the "delayed-immediate" stage is also considered a viable option. In delayed-immediate reconstructive surgery, a tissue expander is placed in the patient's breast in

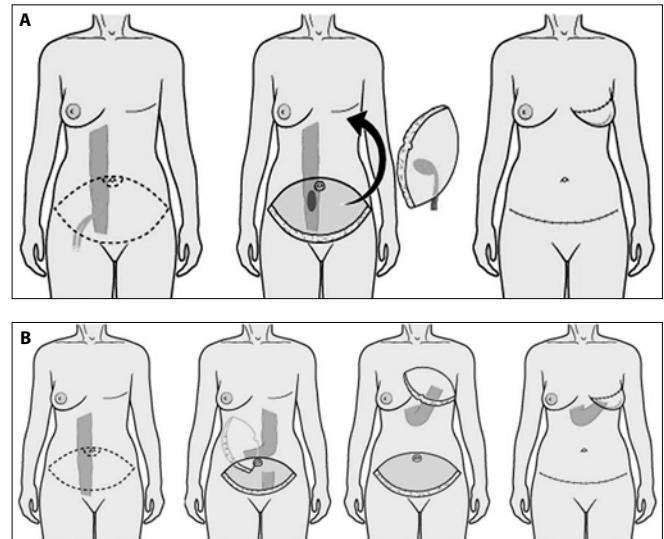


Figure 1. TRAM Flap A) Free TRAM Flap (16) B) Pedicled TRAM flap (16)

order to preserve the pocket formed by mastectomy. Preserving the expanse of breast skin in this manner ensures better esthetic results. Reconstructive surgery is performed in the early stage, depending on the patient's pathology results. If the patient is to receive radiotherapy, reconstructive surgery is delayed until after completion of therapy (10).

Correct timing and method selection of breast reconstruction are ensured through a multidisciplinary team approach involving the patient, the attending oncologist, the breast surgeon, and the plastic surgeon, and through good communication and coordination among the members of the healthcare team (10). Where the patient has multiple disorders and is not well suited for surgery, reconstruction is not recommended (11).

One of the methods often preferred in breast reconstruction surgery is the use of a transverse rectus abdominis myocutaneous (TRAM) muscle-skin flap (13). In the reconstructive technique with a TRAM flap; skin, subcutaneous tissue, fat, and muscle from the abdominal area are transferred to the chest wall to form a new breast. The flap can be moved to the chest wall with a pedicle attached, or as a free flap (7,14,15). In free TRAM flap, the blood vessels that feed the flap are completely severed from the donor area and are anastomosed to the site where the breast will be reconstructed. In the case of a pedicle TRAM flap, the skin, the subcutaneous fat layer, and the rectus abdominis muscle remain attached to their original location through blood vessels, but are slid to the site of breast reconstruction through a subcutaneous tunnel (Figure 1) (16).

The most important advantage of a TRAM flap is obtaining a permanent, natural breast contour without the need for an implant. Removal of excess fat in the lower abdomen (abdominoplasty) and tightening of the abdominal wall is another benefit (15). Besides

these advantages, the opportunity to harvest the exact amount of flap tissue desired, few problems associated with the flap donor site, and the lack of problems encountered with implant materials increase the desirability of this flap (13,17). However, there are also the disadvantages of a prolonged healing process, flap loss, abdominal swelling, development of weakness or hernias, difficulty in performing daily activities, and the possible need for a second operation because of lack of complete symmetry with the other breast (1-3,14).

### **Nursing care of patients with a tram flap**

As mentioned earlier, patients who undergo a mastectomy face problems of losing a breast, decreased perception of womanhood, lack of self-confidence, loss of libido, and depression, as of the time that cancer is diagnosed. In addition, the adverse side effects of postoperative chemotherapy and radiotherapy create a need for specialized nursing care. The care provided to these patients is not limited to the physical; it entails psychological support and education as well (18). The nursing care provided to patients who have had a TRAM flap transplant will be addressed under two headings.

#### **a) Preoperative Nursing Care of TRAM Flap Patients**

The preoperative nursing care of patients who are scheduled for a TRAM flap transplant entails physiological and psychological preparation of the patient for surgery. Establishing communication with the patient, counseling her, giving her the information she needs, and offering emotional support in this period helps alleviate preoperative anxiety. Further, the continuity of the care and education of the patient builds a climate of trust and is consequently effective in helping the patient take control of her emotions (19).

#### **b) Postoperative Nursing Care of Patients With a TRAM Flap**

Nursing care of patients who have had breast reconstruction using a TRAM flap differs from care following other operations, in that it involves the additional aspects of flap monitoring, pain management, drainage follow-up, prevention of potential complications, and home-care of the patient (14). The nursing care provided during the postoperative period is crucial for the success of breast reconstruction with a TRAM flap. Fournier and Shafer (2001) state that the first 24 hours after surgery is vitally important and that careful monitoring of the flap during this time is critical. A fold or a clot that may form in the blood vessels feeding the flap can affect its vitality. While early detection of such a condition can ensure saving the flap, delays may lead to necrosis and consequent loss of part or all of the flap tissue. Patients who have had TRAM flaps are therefore kept in intensive care units where they can be closely monitored for the first 24-48 hours postsurgically (19).

*During the early postoperative stage,* the patient should be kept in a semi-fowler position in her bed. The literature states that the temperature in the patient's room during the first day after surgery should be 24°-31°C, that this is important for increasing

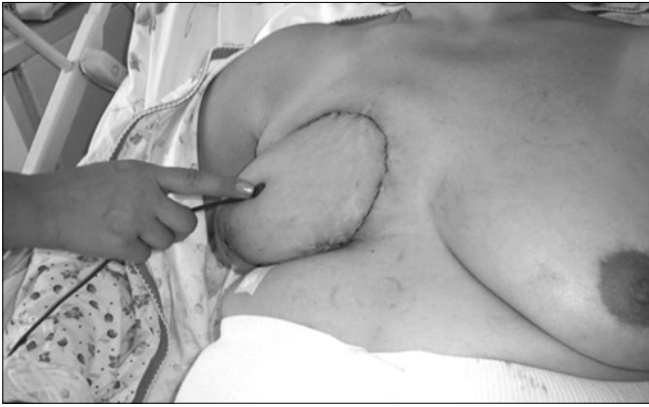blood flow, that the patient should be given topical or systemic drugs with vasodilator effects to increase perfusion, and that the flap should be monitored regularly (13,19).

*Flap Follow-up:* Following a TRAM flap operation, monitoring the flap is crucial. Flap follow-up must begin in the early postoperative period in the recovery room, and continue through the patient's hospital stay. The flap should be monitored every 15 minutes at the recovery unit, at hourly intervals during the first 48 hours after the patient is moved to the clinic, and every four hours for the next 48-hour period (14). This monitoring must be maintained until the patient is discharged. The nurse should evaluate the flap area for temperature, blood flow, color, and capillary refill (19,20). Nurses should take care to use definitive terms that will convey the same meaning to their colleagues and a clear language in describing the color and appearance of the breast to avoid differences in interpretation (13). For example, definitive expressions like light pink, ivory, red, or purple may be used when describing the color of the flap tissue.

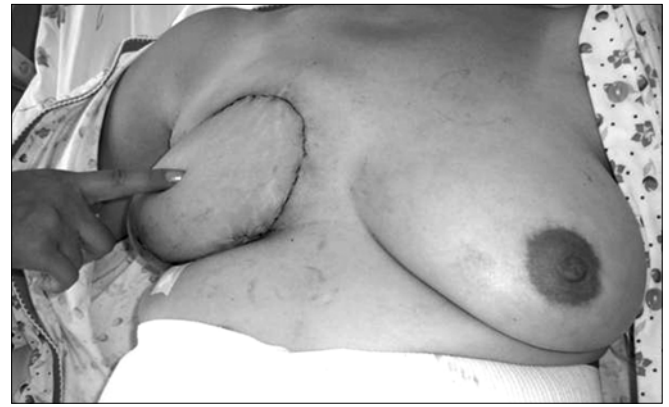In our observations of the follow-up of patients who had a TRAM flap operation in our hospital, we determined that monitoring took place even more frequently than that recommended in the literature. The patients who had undergone a TRAM flap operation in our hospital were being monitored hourly during the first 24 hours following surgery, every two hours during the second 24 hours, every four hours during the third 24 hours, and at six-to eight-hour intervals during the fourth 24-hour period. We also observed that the clinic staff used a "Flap Follow-up Form" for monitoring, which they had developed with standard definitive terminology in order to ensure consistency of records made by different staff members.

*The flap tissue must be evaluated for color.* It is normal for the flap's color to be light pink at the early stage. A dark red coloration of the flap suggests accumulation of blood or obstruction by a clot in donor site veins, leading to collection of blood in the tissues. Petechia in the reconstructed breast indicates reduced venous return and may require addition of fresh veins (13). Spotting of the flap with a dotted or bruised appearance is an unwanted condition (19). An ivory colored (pale) or mottled breast is indication of inadequate or reduced arterial perfusion. In such cases, the volume of intravenous fluid must be increased, and the surgeon needs to be notified immediately so that the patient can be evaluated for further surgery. Nevertheless, the appearance of the newly constructed breast (flap) should also be compared with the color of the donor site (the abdomen) skin. It should be remembered that the color and texture of the reconstructed breast in unilateral mastectomy patients will not exactly match those of the contralateral breast. Bruising or injury in the periphery of the flap can be disregarded (13).

*The temperature of the flap* should be evaluated by touching the flap area with the index finger or the back of the hand (13). The



Picture 1. Evaluation of flap temperature



Picture 2. Evaluation of capillary refill

flap should also be evaluated for oversensitivity or edema at this time. The expected outcome here is for the flap to be warm, not cool (19). Warmth helps dilate veins and increases circulation. For this reason the patient's room should be kept at a temperature of between 24°C and 31°C with the door closed, and the patient should be covered with warm, air-circulating blankets during transport from the recovery unit to the clinic (13,19). With recent technological developments, it is now possible to assess the temperature of the flap with monitors that measure skin temperature with a probe (Picture 1). Another point that requires care while measuring the temperature of the flap is to compare the flap's temperature with the patient's body temperature. There should be an average difference of 2°C-3°C between the body temperature and the flap's. Where the flap is cooler, development of arterial insufficiency should be considered. A lower flap temperature must be reported to the surgeon immediately (20).

*Capillary refill of the flap* is evaluated by applying light pressure to the flap area with the index finger or a blunt object (Picture 2). Care should be taken not to apply pressure for longer than one second (13). Color should return within 1-3 seconds. A faster return indicates venous congestion, and return in more than three seconds indicates reduced arterial flow (13,19).

*Perfusion of flap tissues* is assessed with the aid of a device called Doppler. To monitor flap perfusion with Doppler, a small amount of gel is applied to the tip of the probe, which is moved over the reconstructed breast (flap) without applying pressure. Blood flow in the flap area is thus monitored with sound (19). This device shows any decline in tissue perfusion before visible color changes can be observed in the flap, and emits a warning signal when perfusion is reduced. When the Doppler device signals a decrease in tissue perfusion, the patient's tissue perfusion should be reassessed and the surgeon should be advised immediately to administer intravenous fluids if needed. However, using too little gel during Doppler monitoring, a malfunctioning probe, failure to keep the patient warm, and bathing of the patient can sometimes cause temporary disruption of blood flow. Therefore, the nurse should first rule out these conditions when the device sounds an alarm for decrease in

perfusion, before notifying the doctor. Perfusion assessment by Doppler is especially important in the case of patients with dark skin, where color changes are not clearly visible (13). If inadequate perfusion of the flap is observed, the surgeon must be alerted immediately (20).

Flap assessment in our hospital was observed to include the patients' body temperature; warmth, perfusion, capillary refill, color, and turgor of the flap; and bleeding. Nurses assess the color as pink, cyanotic, or white; flap turgor, as normal or distended; capillary refill, as normal (1-3 seconds), slow (more than 3 seconds), or fast (less than 1 second). The temperature of the flap tissue is measured using monitor probes for skin temperature, a value between 31°C and 36°C is considered normal, and the flap temperature is compared to the patient's body temperature. Perfusion of the flap areas is assessed using a Doppler device for the presence of audible pulsation, and the strength of weakness of the pulsation.

*During flap monitoring*, the patient's incisions in the breast and abdomen must also be evaluated. Drainage from the incision must be minimal, and the edges of the wound should be contiguous. The incision site should be evaluated for increased erythema and warmth. It should be remembered that it is normal for the flap to be minimally edematous in the early postoperative phase; however, the flap should be checked regularly to detect any possible increase in edema (13,19).

*Respiration:* Patients who have had a TRAM flap operation are at risk of pulmonary problems in the postoperative period. In order to accelerate flap perfusion and wound healing, and to prevent development of atelectasis, it is important to have the patient do deep breathing exercises with a spirometer, especially during the first two postoperative days. If deemed necessary by the doctor, oxygen therapy may be given to the patient to ascertain oxygenation of the flap site (20,21).

*Pain:* The severity of the patient's pain should be evaluated periodically and measures should be taken to relieve it. According to the literature, during the two post-surgical days, patient-con-

trolled pain relief, and during the following days, oral analgesics are administered (13). In the case of the plastic and reconstructive surgery clinic of our university, patient-controlled pain relief is used during the first postoperative 24 hours, followed by intravenous or intramuscular non-narcotic pain medication for 2-3 days, and oral analgesics on the following days. The need to educate patients who will receive strong, patient-controlled analgesic medication about the use of the device and the length of analgesic effect is emphasized in the literature. Following patient-controlled analgesia, the patient should be given oral pain relievers regularly until discharge (14,20,22). The dosage of oral analgesics should be reduced as the patient's pain lessens and she feels more comfortable (21). In order to relieve the tightness caused by the abdominal incision, the patient's head should be elevated 30° to a semi-fowler' position, and her knees should be drawn toward her abdomen (20).

**Nutrition and Excretion:** It is important to ensure that the patient does not receive any fluids or food orally until her bowel functions are restored. When bowel function returns to normal, diet should be advanced in stages (13). Narcotic analgesics given with patient-controlled analgesia in the postoperative period create a risk of constipation. Development of abdominal distension as a result of constipation interferes with proper healing of the abdominal incision. Onset of constipation during the postoperative period therefore needs to be prevented. The patient should receive plenty of fluids, a high-fiber diet should be ensured, and medication with laxative effect should be provided as necessary. In case of continued risk of constipation, use of stool softening drugs (suppository, oral laxative) may be sustained after the patient's discharge (approximately 1 month) (21).

**Fluid-Electrolyte Balance:** Fluid intake-output and drainage should be monitored after surgery. Patients are usually given 5% dextrose and Ringer lactate as fluids, and potassium as an electrolyte (19,21). A Foley catheter is inserted in order to assess the patient's urine output and to reduce bladder distension in the early postoperative period. Urine output is expected to exceed 35 ml/hour. A urine volume of less than 35 ml/hour is often associated with hypovolemia and requires attention. If the urine output decreases, the patient's blood pressure as well as the flap's condition (for decreased blood flow) must be evaluated. Urine volume measurements under 35 ml/hour at two consecutive hours are an indication for additional fluid replacement. Fluid replacement is continued until the patient's blood pressure rises and the flap's perfusion increases (21). During fluid replacement, patients should also be assessed for hydration.

**Activity:** On postoperative day one, the patient should be allowed to walk to the extent she can tolerate. The patient should sit on the bed for some time before standing. Because of the abdominal incision, patients usually bend forward while walking, and feel a need to support their abdomen with a pillow during the first postoperative week. The nurse should support the patient's back to ensure a straight posture, give her information, and encourage

standing straight. The patient's caregivers must also be informed about the need for good posture during ambulation and should be observed to ensure correct understanding (19,20).

The patient should be encouraged to exercise her ankles post-surgically. These exercises and elastic wraps or pneumatic hosiery reduce the risk of post-surgical deep vein thrombosis (13).

**Complications:** The patient must be followed up for early-stage complications associated with anesthesia and surgery (bleeding in the transplantation site or insufficient perfusion; hypovolemia, nausea-vomiting, impaired electrolytic balance, etc.) (2,20).

A complication rate of 23.7%-26.0% is reported in the literature for patients receiving breast reconstruction surgery with a TRAM flap (17,19). Possible complications in the post-surgical stage include weakness of the abdominal wall, herniation, infection of the incision site, hematomas, necrosis, flap loss, and chronic pain. In addition, some patients may develop deep vein thrombosis, pulmonary embolism, pneumonia, loss of epidermal thickness to varying degrees, muscle spasms, a pulling sensation, change in sensitivity, and slight loss of sense in the abdominal area. Presence of chronic disorders like obesity, hypertension, and diabetes mellitus increases the risk of development of complications. Further, patients who have received radiotherapy in their chest area carry a high risk of complications, and their prospects of getting satisfactory esthetic results from the surgery are reduced. The literature reports observations of prolonged wound healing in patients receiving chemotherapy after mastectomy (11,17,19,20,22). Patients must be followed up for signs and symptoms of these complications.

**Psychological Support:** Establishing good communication with the patient, giving her psychological support, and ensuring her comfort are important in the postoperative period. It should be kept in mind that the patient may give conflicting reactions during the post-surgical stage, needs a sensitive approach, and must be treated with empathy. The patient should be given the opportunity to ask questions and to express her feelings. She may ask questions related to the appearance of her new breast. It should be explained to her that a newly constructed breast will be edematous in the first stages, that the edema will slowly dissipate, that bruising may be present in the early phase, and that sometimes the two breasts may not be symmetrical, which may necessitate a second surgery (13). The nurse should inform the patient about all procedures that have been done to the patient, results of her evaluations, and the outline of the care she is receiving. The patient must be encouraged to share her emotions.

The patient should be asked whether visitors and incoming calls fatigue her and whether she needs to rest, and if necessary, the phone may be unplugged and visitation restricted to ensure proper rest. Care should be taken to ascertain that the patient is in a semi-fowler position while resting and to avoid excessive

flexing (abduction). The patient should be assessed for pain in the parts of her body that are susceptible to pressure, such as her back and neck, and a gentle massage should be applied as necessary. It must be remembered that gently massaging the patient's back and neck will help her relax and rest more comfortably. If the patient's room is so warm as to cause her to perspire, her face and neck may be wiped with a cool washcloth (13).

*Patient Discharge and Home Care:* Patients are discharged according to the following criteria after surgery: (19)

- Urine output of more than 30 cc per hour, lack of urine retention
- Correct performance of the drainage process by both the patient and her caregivers
- A level of pain adequately controllable with oral analgesics
- Lack of nausea and vomiting and good nutrition capability
- Patient's ability to leave her bed and ambulate with the aid of her caregivers
- Educating the patient about her care at home, and where she has no one to help with her care, ensuring that she receives this service

As of the early postoperative period, both the patient and her family must be extensively educated about the patient's care (13,19). The importance of taking the prescribed medications regularly and properly must be stressed. The significance of proper nutrition in accelerating the healing process of her wound, the importance of avoiding weight gain, which might increase the fat tissue and cause enlargement of the reconstructed breast, must be explained.

If the patient is being discharged with a drain in place, it should be explained to her that the amount and nature of drainage must be evaluated daily, that drainage will gradually abate. The patient should be told that the surgeon will remove the drain when drainage in a 24-hour period falls to 25 ml or below, which happens approximately after the first or second postoperative week. After removal of the drain, the patient should be instructed to cover the drain site with a clean dressing, without using an adhesive bandage as the support bra (the bra should be soft, cupped for support, and free of underwires) will keep the dressing in place (13). The patient and her caregiver must be instructed to continue to care for the drain and to measure the amount of drainage daily. It should be explained to them that bloody or purulent drainage, fever of over 38°C, increase in pain, discharge from the incision or wound, or wound dehiscence are conditions that require contacting the doctor. The patient must be informed that the stitches will be removed in 7-10 days, and that she must check the incision site daily for any increase in redness, discharge, swelling, or dehiscence. The patient must be warned to keep the incision area free from pressure. She may shower 24 hours after the removal of the drains, subject to the doctor's advice (19). The patient should be informed that her wounds will heal completely in 1-2 years' time, that

the scar tissue will diminish in time and its color will fade, but it will not disappear altogether. The patient should be warned that because the reconstructed breast is devoid of sensation, she needs to avoid exposure to the sun and use a sun protection product (minimum SPF15) before going outdoors (22-24).

The patient should be informed that her recovery will take 3-6 weeks. She should be warned against smoking, as this will interfere with the recovery of the flap site and will cause a larger scar (25). The literature reports that in patients who quit smoking at least four weeks before surgery, postoperative complications of TRAM flap surgery are considerably reduced, with fewer occurrences of flap necrosis and herniation (13). The patient should be advised about the simple shoulder exercises she can do. She must be warned against lifting the arm on the operated side above shoulder level until the drain comes out. She should also avoid leaning on her arms to straighten her body, lifting heavy objects, or lying in a supine position (19). She should be cautioned to exercise care in activities that are likely to cause pain, such as sitting down on or getting up from a straight chair, and lifting her shoulders or arms, and to wear a binder to support her abdomen (13,25).

The patient should be warned to refrain from lifting or pushing objects heavier than 2 kg., to avoid bending forward or flexing, performing heavy or tiring tasks, and to get plenty of rest during the first month or month-and-a-half. She should restrict shoulder movements such as lifting her shoulders as these may cause excessive pain for the first two weeks, but should begin the recommended arm and stomach exercises after this time. She should be advised to take walks once or twice a day and to gradually increase the time and distance of the walks. She should be cautioned to avoid activities like driving, swimming, playing tennis, etc., which may overtax her, for at least six weeks (20,23,24).

If the patient's axillary lymph nodes were dissected due to a diagnosis of breast cancer, she should be cautioned about taking good care of her hand and arm on the operated side to avoid development of lymphedema. She should also take precautions against infections. Further, the patient should be warned not to have her blood pressure taken or have any injections on the arm on the axillary dissection side, protect her hand and arm from traumas and burns, use a hand cream, and to use an electric shaver or depilatory cream to remove underarm hair (24).

The patient should not use a bra during the first weeks following surgery, until the doctor advises her it is safe to do so. The bra should not be tight, but firm, soft, cupped for support, and free of underwires (19,26). The patient should be informed that she can resume her sex life in 3-6 weeks and that she will not be able to nurse for the rest of her life. It should be explained that reconstruction does not restore the breast's sensitivity; however, a return of some feeling is possible over time (13). It should also be pointed out that the reconstructed breast may seem harder, rounder, and flatter than the other breast, may not have the same

size as before mastectomy, and that there may be a slight asymmetry of the two breasts. The patient should be counseled that she will become used to the new appearance of her breast over time, and that this is a normal process (20,22). Sexuality-related problems are frequent after reconstruction. The nurse must allow the patient and her partner to share their problems with their sexuality. The patient and her partner may have questions about when and how the nipple and areola can be reconstructed. They should be advised that this reconstructive surgery can be done at least three months after breast reconstruction and when the surgeon deems appropriate, however, the edema of the reconstructed breast needs to drain and healing must be complete (13).

The patient should be counseled to continue her medical follow-up (oncology and plastic surgery), to examine her intact breast and the remaining portions of her reconstructed breast monthly

as taught and demonstrated, and to have a mammography every year. A great majority of patients entertain fears of recurrence of breast cancer and inability to detect a recurrence early because of the breast reconstruction. These patients should be counseled that breast reconstruction does not affect early detection of breast cancer or mammography results (13).

In conclusion, TRAM flap operations play an important role in improving the quality of living of breast cancer patients and helping them deal with the difficult emotions they experience. The surgical team and nurses, as indispensable members of this team, contribute considerably to the success of TRAM flap operations. With professional nursing care, patients who have had TRAM flap surgery recover quicker, have fewer complications, gain an improved physical self-image, and are empowered to fight against and defeat the "nightmare" of breast cancer.

## References

1. Wolf L. Bir Kadının Bakış Açısından Meme Rekonstrüksiyonu: Bir Meme Bakım Hemşiresinin Deneyimi, İçinde: Querci della Rovere G, Benson JR, Breach N, Nava M (Ed), Koçak S, Özbaş S (Çev. Ed) Onkoplastik ve Rekonstrüktif Meme Cerrahisi, London: Taylor & Francis Group, 2005:181-186.
2. Hart D. The psychological outcome of breast reconstruction. *Plastic Surgery Nursing* 1996; 16(3):167-171. (PMID: 9060756)
3. The Royal Marsden NHS Foundation. A national audit of provision and outcomes of mastectomy and breast reconstruction surgery for women in England and Wales, The Royal Marsden NHS Foundation First Annual Report of the National Mastectomy and Breast Reconstruction Audit 2008, [http://www.ic.nhs.uk/webfiles/Services/NCASP/Cancer/new%20web%20documents%20\(MBR\)/New%20web%20documents/163447%20IC%20MBR%20Audit%20Final.pdf](http://www.ic.nhs.uk/webfiles/Services/NCASP/Cancer/new%20web%20documents%20(MBR)/New%20web%20documents/163447%20IC%20MBR%20Audit%20Final.pdf), Erişim Tarihi: 9.02.2009.
4. Meme Kanseri Onkoplastik Cerrahi, I.Ulusal Meme Kanseri Konsensusu (15-19 Kasım 2006), Haydarođlu A (Ed), İzmir: Kongre Basımevi Matbaası, 2007: 63-67. [http://www.mhdf.org.tr/pdf/938umkk\\_kitap-2006%5B1%5D.pdf](http://www.mhdf.org.tr/pdf/938umkk_kitap-2006%5B1%5D.pdf), Erişim Tarihi: 9.02.2009.
5. South and West Regional Health Authority, Immediate Breast Reconstruction Following Mastectomy for Cancer of the Breast. Development Evaluation Committee Report no. 41. Wessex Institute of Public Health, Wessex, 1995.
6. Susan G. Komen for the Cure. Reconstruction Often Not Discussed Before Breast Cancer Surgery, <http://www5.komen.org/ExternalNewsArticle.aspx?newsID=41046>, Erişim Tarihi: 25.05.2009.
7. Yücel A, Kurul S. Mastektomi sonrası meme rekonstrüksiyonu, İçinde: Topuz E, Aydın A, Diñçer M (Ed), Meme Kanseri, 1. Baskı. İstanbul: Nobel Tıp Kitabevleri, 2003: 532-546.
8. Shons AR, Mosiello G. Postmastectomy Breast reconstruction: current techniques. *Cancer Control* 2001; 8(5): 419-426. (PMID: 11579338)
9. Koçak S. Meme kanseri cerrahisinde rekonstrüksiyon. [www.mdck.org/swf/32.ppt](http://www.mdck.org/swf/32.ppt), Erişim Tarihi: 22.05.2008.
10. Djohan R, Gage E, Bernard S. Breast reconstruction options following mastectomy. *Cleveland Clinic Journal Of Medicine*, 2008; 75(1): 17-23. (PMID: 18457193)
11. Association of Breast Surgery at BASO; Association of Breast Surgery at BAPRAS; Training Interface Group in Breast Surgery, Baildam A, Bishop H, Boland G, Dalglis M, Davies L, Fatah F, Gooch H, Harcourt D, Martin L, Rainsbury D, Rayter Z, Sheppard C, Smith J, Weiler-Mithoff E, Winstanley J. Oncoplastic breast surgery - a guide to good practice, *Eur J Surg Oncol* 2007; 33(1):S1-S23. (PMID: 17604938)
12. Al-Ghazal SK, Sully L, Fallowfield L, Blamey RW. The psychological impact of immediate rather than delayed breast reconstruction. *Eur J Surg Oncol* 2000; 26: 17-19. (PMID: 10718173)
13. Sandau KE. Free TRAM flap breast reconstruction. *Am J Nurs* 2002; 102(4): 36-43. (PMID: 11943921)
14. Clayton BJ, Waller AL. The TRAM flap in breast reconstruction. *Plastic Surgery Nursing* 1996; 16(3):133-138. (PMID: 9060752)
15. Aydın Y. Mastektomi sonrası rekonstrüktif cerrahi. İçinde: Meme Kanseri, İstanbul Ünivewrsitesi Cerrahpaşa Tıp Fakültesi Sürekli Tıp Eğitimi Etkinlikleri Sempozyum Dizisi No: 54, 2006: 127 - 142.
16. The University of Texas MD Anderson Cancer Center. The Well-Informed Patient's Guide to Breast Reconstruction: Breast Reconstruction with a TRAM Flap. <http://www.mdanderson.org/diseases/BreastCancer/reconstruction/display.cfm?id=44A5F1F2-AB79-4AA7-9537BFA7CDB64626&method=displayFull&pn=B2D4F06F-5F39-4BB3-9084F56F6B6E3CDE>, Erişim Tarihi: 22.05.2008.
17. Balkan M, Görgülü S, Öztürk E, Zor F, Arslan İ, Şengezer M, Tufan T. Transvers rektus abdominis miyokutanöz (TRAM) flep ile meme rekonstrüksiyonu: 10 yıllık sonuçlarımız. *Meme Sađlığı Dergisi* 2008; 4(1): 21-24.
18. Hill O, White K. Exploring women's experiences of tram flap breast reconstruction after mastectomy for breast cancer. *Oncology Nursing Forum* 2008; 35 (1): 81-88. (PMID: 18192156)
19. Fournier J, Schafer SL. TRAM flap surgery: vigilant care promotes healing and is cost-effective. *American Journal of Nursing* 2001; 101(4): 16-18.
20. Gross RE. Assessment and Management of Patients With Breast Disorders. In: Brunner LS, Suddarth DS, Smeltzer SC, Bare BG, ed. *Brunner & Suddarth's Textbook Of Medical-Surgical Nursing*, 10th ed. New York: Lippincott Williams & Wilkins, 2004:1445-1484.
21. Kroll, SS. *Breast Reconstructon With Authogous Tissue Art and Artistry*, Texas: Springer, 2000: 143-159.

22. Andrade WN, Baxter N, Semple JL. Clinical determinants of patient satisfaction with breast reconstruction. *Plastic&Reconstructive Surgery* 2001; 107(1): 46-54. (PMID: 11176600)
23. Baron R, Vazırı N. Reconstructive Surgery. In: Dow KH, ed. *Contemporary Issues in Breast Cancer: a Nursing Perspective*, 2nd ed. Sudbury: Jones & Bartlett Publishers, 2004: 90-109.
24. The University of Pittsburgh Medical Center Information for Patients, TRAM Breast Reconstruction: After Your Surgery. <http://www.upmc.com/HealthAtoZ/patienteducation/Documents/TramBreastReconstruction.pdf>, Eriřim Tarihi: 25.05.2009.
25. Dell DD. Pain and the TRAM flap surgery. [www.fccc.edu/docs/publications/PRN/PRN-news-summer2002-pg4.pdf](http://www.fccc.edu/docs/publications/PRN/PRN-news-summer2002-pg4.pdf), Eriřim Tarihi: 23.05.2008.
26. Dartmouth-Hitchcock Medical Center, TRAM flap procedure preoperative and postoperative care instructions. [http://www.dhmc.org/dhmc-internet-upload/file\\_collection/tram\\_flap\\_procedure.pdf](http://www.dhmc.org/dhmc-internet-upload/file_collection/tram_flap_procedure.pdf), Eriřim Tarihi: 23.05.2008.

---

**Corresponding**

Sevil Gler Demir  
E-mail : [sevilgulerdemir@yahoo.com](mailto:sevilgulerdemir@yahoo.com)  
Tel : 0 (312) 216 26 54