

METASTATIC MALIGNANT MELANOMA OF THE BREAST: A CASE REPORT

Olca Ak Nalbant¹, Safiye Vural¹, M. Celalettin Keleş², Erdem Nalbant³, Ali Rıza Kandilođlu⁴

¹Manisa Devlet Hastanesi, Patoloji Lab, Manisa, Türkiye

²Manisa Devlet Hastanesi, Genel Cerrahi Kliniđi, Manisa, Türkiye

³Merkez Efendi Devlet Hastanesi, Genel Cerrahi Kliniđi, Manisa, Türkiye

⁴Celal Bayar Üniversitesi Tıp Fakóltesi, Patoloji AD, Manisa, Türkiye

MEMENİN METASTATİK MALİGN MELANOMU: OLGU SUNUMU

ÖZET

Memeye malign melanom veya başka herhangi bir tümörün metastazı nadir olarak görülür. Yetmiş yaşında bayan hasta, sağ memesinde kitle yakınmasıyla meme kliniđine başvurdu. Olgunun bilinen bir malignite öyküsü yoktu. Önce insizyonel biyopsi alındı, ardından sağ modifiye radikal mastektomi ve aksiller lenf nodu diseksiyonu yapıldı. Mastektomi materyalinin kesit yüzünde en büyük çapı 8 cm olan, sarı pembe renkli, solid, iyi sınırlı tümöral lezyon görüldü. Histopatolojik ve immunohistokimyasal özellikleriyle olgu, meme ve aksiller lenf nodlarında metastatik malign melanom olarak değerlendirildi. Bu olgu, metastatik tümörlerin histolojik tanısı primer meme kanserlerinden daha zor olabildiđi ve memeye malign melanom metastazı nadir görüldüğünden sunulmaya değer bulunmuştur.

Anahtar sözcükler: meme, malign melanom, metastatik

ABSTRACT

Metastasis of a malignant melanoma or any other type of tumour to the breast is rarely seen. A 70-year-old female patient came to the breast clinic due to a mass in her right breast. The case did not have any known history of malignancy. After the initial incisional biopsy, a right modified radical mastectomy and axillary lymph node dissection were performed. On the cut surface, a yellow to pink, solid and well-circumscribed tumoural lesion with a maximum diameter of 8 cm was observed. Given its histopathological and immunohistochemical attributes, the case was diagnosed as metastatic malign melanoma involving breast and ipsilateral axillary lymph nodes. This case was determined to be worthy of presentation due to the fact that the histological diagnosis of metastatic tumours can be more difficult than of primary breast cancers and that metastasis of malignant melanoma to breast is rarely seen.

Key words: breast, malign melanoma, metastatic

Introduction

Metastasis of primary tumours of extramammary tissues and organs to the breast is quite rare (1-3). When compared to primary tumours of the breast, the incidence of metastatic breast tumour is reported to be 0.3% (4), 0.78 (3) and 1.5% (5). Among tumours with breast metastasis, malign melanoma has a predominant incidence (1,2, 6-8). This case is presented due to the rare incidence of metastasis of malign melanoma to the breast and for the purpose of stating the difficulties encountered in the course of diagnosis.

Case Report

The visually-impaired, 70-year-old, female patient came to our hospital due to the presence of a rapidly growing mass in her right breast noticed by her three months ago. The physical examination of the patient identified a hard palpable tumoural lesion in the upper external quadrant of the right breast with a visual swelling on the skin and lymph nodes in the axilla as discovered via physical examination. First, an incisional biopsy was performed.

In the microscopic evaluation of the incisional biopsy material, the characteristics of the tumour were observed to be oval-round cells creating solid islands and nest with mostly eosinophilic and sometimes clear cytoplasm, pleomorphic vesiculated nuclei and coarse eosinophilic nucleoli (Figure 1). Due to the occasional presence of cells with clear cytoplasm observed in the case, PAS-dPAS (Biooptica) was applied for the differential diagnosis of clear cell-type (glycogen rich) carcinoma and as a result, the histochemical dye was observed to be negative. From the immunohistochemical dyes, oestrogen (Novacastra) and progesterone receptors (Novacastra) were also found to be negative. The case was diagnosed as a malignant breast tumour on the basis of the aforementioned findings.

Due to the fact that the extremely large tumour is located quite close to the skin surface and due to the presence of axillary lymph nodes considered to be clinically involved, right modified radical mastectomy and axillary lymph node dissection was performed.

In the macroscopic evaluation of the mastectomy specimen, a tumour with a maximum diameter of 8 cm was observed in the upper external quadrant. No pigmented lesion was observed on the

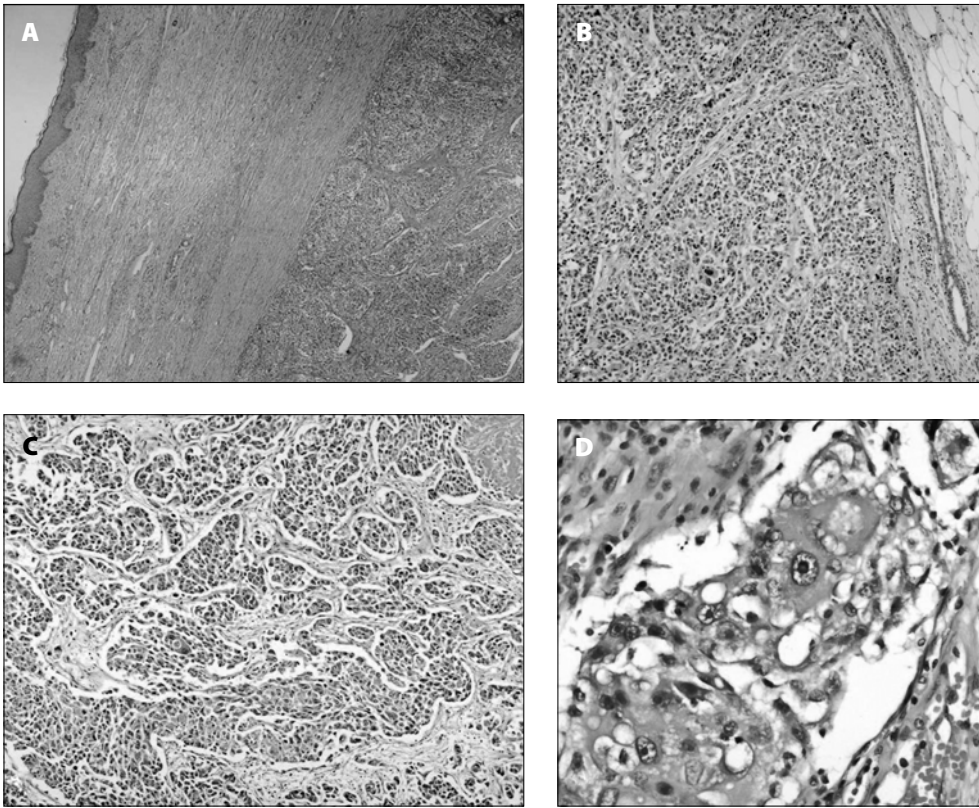


Figure 1. Regular skin and tumour on surface, HE x40 (A); regular surrounding breast tissue and tumour, HE x100 (B); tumour forming islands-nests and the necrotic area at the right upper corner, HE x100 (C); tumoural cells with coarse, eosinophilic nucleoli, HE x400 (D).

breast skin. On the cut surface of the material, the tumour that was located right under the skin was observed to be well-circumscribed, solid, yellow to pink and necrotic in patches. In addition to the findings observed in the incisional biopsy material, widespread lymphatic tumour emboli were observed. Metastasis was identified in three of the twenty lymph nodes removed from the axilla.

The presence of a metastatic tumour was suspected in the mastectomy specimen due to the fact that the tumour was well-circumscribed at macroscopically, there were many radial extensions into the fat tissue, no *in situ* carcinoma focus or elastosis were identified in any area there were a number of lymphatic invasion foci around the tumour and estrogen and progesterone receptors were negative, although this did not rule out primary breast tumour. Nests created generally by the tumour and the presence of occasional coarse eosinophilic nucleoli in the tumour cells led to the consideration of the malignant melanoma possibility and additional immunohistochemical dyes were applied for this diagnosis. According to the determinations, S-100 (Dako) was strongly positive (Figure 2a); Melan-A (Neomarkers) was focal positive (Figure 2b); HMB-45 (Neomarkers) was negative and Ki-67 (Neomarkers) was 40% positive (Figure 2c). These findings provided for the diagnosis of malignant melanoma.

In the 6th month postoperatively, a recurring tumour was observed in the axillary region and subsequently excised. Rejecting the therapy, the patient died eight months postoperatively.

Discussion

The decision as to whether any mass in the breast is primary or metastatic is of great significance for the subsequent therapy. However, the histological diagnosis of metastatic tumours identified in the breast can be more difficult than that of primary breast cancer (9). Certain histopathological attributes can be used for the differentiation between primary and metastatic breast tumours. Carcinoma *in situ* and elastosis areas are associated only with primary breast cancer (4). In the specimens, ductal carcinoma *in situ* and lobular carcinoma *in situ* areas must be carefully examined (9). In addition, atypia that is more characteristic than expected, tumour in the form of a well-circumscribed mass with a multiple-satellite focus around and the presence of a high number of lymphatic emboli in primary breast tumour are other possible hints in the diagnosis of metastatic tumour (6). Nevertheless, immunohistochemical dyes are necessary for the diagnosis of metastatic tumour or metastatic melanoma (10).

In this case, an initial diagnosis was made from the incisional biopsy monitored with a narrow skin ellipse on the surface, no transmission to the surrounding tissue and made up solely of tumour. Due to the large and clear-type cytoplasm of some cells, PAS-dPAS was performed in order to examine the glycogen content and as a result, it was found to be negative. In immunohistochemical terms, no dyeing was identified in the tumour with estrogen and progesterone receptors. In the subsequently evaluated mastectomy specimen, the well-circumscribed structure of the tumour in

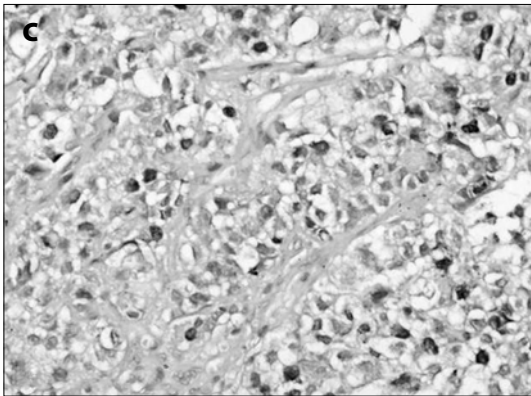
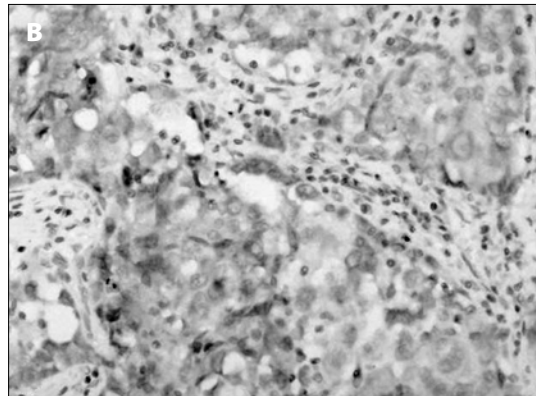
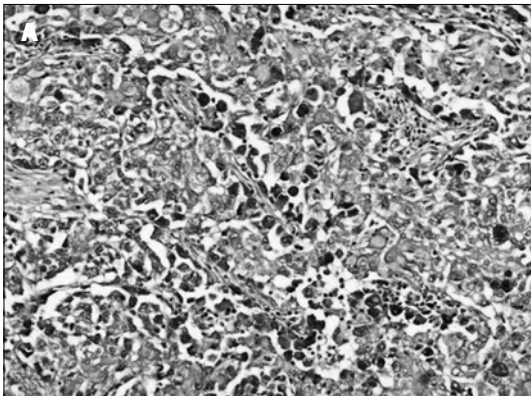


Figure 2. Diffused nuclear and cytoplasmic S-100 positivity, DAB x200 (a); focal cytoplasmic Melan-A positivity, DAB x400 (b); nuclear Ki-67 positivity, DAB x400 (c).

macroscopy, lack of any *in situ* carcinoma focus or elastosis in microscopic evaluation and the presence of a large number of lymphatic invasion focus around the tumour led to the consideration of the possibility of metastatic tumour. In addition to the lack of pigments in any area, the nests created generally by the tumour and the presence of occasional coarse eosinophilic nucleoli in the tumour cells led to the consideration of the malignant melanoma possibility. Therefore, additional immunohistochemical examinations were performed, as a result of which S-100 was found to be diffused positive and Melan-A focal positive, even though HMB-45 was negative. In this case, no pigmented lesion was observed on the breast skin and the observation of a number of specimens showed that the tumour did not involve the skin. Again, no histopathological finding leading to the suspicion of regressing malignant melanoma was found in these specimens. These findings provided for the exclusion of primary malignant melanoma in the breast and the case was diagnosed as metastatic malignant melanoma.

Malignant melanoma of the breast can be divided into two groups, namely primary and metastatic (11). Malignant melanomas observed on the breast skin account for 5% of all malignant melanomas (2, 11). The post-diagnosis physical examination of the patient did not reveal any melanocytic lesions in other parts of the body. The presence of a regressed skin melanoma which the case failed to notice due to her visual impairment was considered.

In this case, similarly to the cases reported in literature, the tumour was observed to be located in the upper external quadrant and with metastatic axillary lymph nodes (12, 13).

Metastatic spreading to the breast can occur via lymphogenic or hematogenic courses. Lymphatic spreading frequently occurs via the spreading of primary breast cancer in the other breast to the lymphatics located in the anterior thoracic wall. The tumour with the most frequent hematogenic metastasis is malignant melanoma, followed by lung cancer, soft-tissue sarcoma and ovary cancer. Other metastatic tumours include such haematological malignancy as gastrointestinal and genitourinary system malignancy and leukaemia and lymphoma (9).

The determination of the metastatic character of a tumour identified in the breast is reported to prevent unnecessary surgical interventions (10). Nevertheless, it is also reported that axillary dissection is possible, if a clinically and pathologically positive axillary lymph node is identified (2). In this case, due to the great size of the tumour and the presence of palpable lymph nodes, mastectomy and axillary lymph node dissection was performed.

The prognosis is rather poor in cases with diagnosed malignant melanoma metastasis to the breast (10). Mean survival is reported to be 10-11 months, although there are also a small number of cases with longer survival (14). This patient did not do well with the treatment and therapy and died in the 8th month postoperatively.

The first finding of a primary malignancy can be breast metastasis (12). Similar cases with the first finding of breast metastasis have been reported (10). In cases where indicators of primary breast tumour cannot be clearly seen in microscopic assessment, the possibility of a metastatic tumour must not be ruled out, the necessary histopathological attributes must be sought and immunohistochemical studies must be performed.

References

1. Cangiarella J, Symmans WF, Cohen JM, Goldenberg A, Shapiro RL, Waisman J. Malignant melanoma metastatic to the breast: a report of seven cases diagnosed by fine-needle aspiration cytology. *Cancer*. 1998 Jun 25; 84(3):160-2. (PMID: 9678730)
2. Kurul S, Taş F, Büyükbabani N, Mudun A, Baykal C, Camlica H. Different manifestations of malignant melanoma in the breast: a report of 12 cases and a review of the literature. *Jpn J Clin Oncol*. 2005 Apr; 35(4):202-6. (PMID: 15845569)
3. Fulciniti F, Losito S, Botti G, Di Mattia D, La Mura A, Pisano C, Pignata S. Metastases to the breast: role of fine needle cytology samples. Our experience with nine cases in 2 years. *Ann Oncol*. 2008 Apr; 19(4):682-7. (PMID: 18048381)
4. Lee AH. The histological diagnosis of metastases to the breast from extramammary malignancies. *J Clin Pathol*. 2007 Dec; 60(12):1333-41. (PMID: 18042689)
5. Handa U, Chhabra S, Mohan H. Aspiration cytology of extramammary tumours metastatic to the breast. *Indian J Pathol Microbiol*. 2007 Oct; 50(4):855-8. (PMID: 18306588)
6. Vergier B, Trojani M, de Mascarel I, Coindre JM, Le Treut A. Metastases to the breast: differential diagnosis from primary breast carcinoma. *J Surg Oncol*. 1991 Oct; 48(2):112-6. (PMID: 1921396)
7. Wood B, Sterrett G, Frost F, Swarbrick N. Diagnosis of extramammary malignancy metastatic to the breast by fine needle biopsy. *Pathology*. 2008 Jun; 40(4):345-51. (PMID: 18446623)
8. Di Bonito L, Luchi M, Giarelli L, Falconieri G, Viehl P. Metastatic tumors to the female breast. An autopsy study of 12 cases. *Pathol Res Pract*. 1991 May; 187(4):432-6. (PMID: 1876525)
9. Chung SY, Oh KK. Imaging findings of metastatic disease to the breast. *Yonsei Med J*. 2001 Oct; 42(5):497-502. (PMID: 11675677)
10. Majeski J. Bilateral breast masses as initial presentation of widely metastatic melanoma. *J Surg Oncol*. 1999 Nov; 72(3):175-7. (PMID: 10562365)
11. Lee YT, Sparks FC, Morton DL. Primary melanoma of skin of the breast region. *Ann Surg*. 1977 Jan; 185(1):17-22. (PMID: 831633)
12. Toombs BD, Kalisher L. Metastatic disease to the breast: clinical, pathologic, and radiographic features. *AJR Am J Roentgenol*. 1977 Oct; 129(4):673-6. (PMID: 409241)
13. Loffeld A, Marsden JR. Management of melanoma metastasis to the breast: case series and review of the literature. *Br J Dermatol*. 2005 Jun; 152(6):1206-10. (PMID: 15948983)
14. Siegelmann-Danieli N, Cohen HI, Ben-Izhack O. Malignant skin lesions. Case 1: nevoid malignant melanoma of the breast presenting as a contralateral breast metastasis. *J Clin Oncol*. 1999 Dec; 17(12):3850-2. (PMID: 10577858)

İletişim

Olcay Ak Nalbant
Tel : 0(236) 02363020
E-Posta : olcayaknalbant@hotmail.com