

## GRANULAR CELL TUMOR OF THE BREAST: A CASE REPORT

Hasan Gökçe<sup>1</sup>, Merih Güray Durak<sup>1</sup>, Mehmet Mustafa Akın<sup>1</sup>, Tülay Canda<sup>1</sup>, Pınar Balcı<sup>2</sup>, Ali İbrahim Sevinç<sup>3</sup>

<sup>1</sup>Dokuz Eylül Üniversitesi Tıp Fakültesi, Patoloji Anabilim Dalı, İzmir, Türkiye

<sup>2</sup>Dokuz Eylül Üniversitesi Tıp Fakültesi, Radyoloji Anabilim Dalı, İzmir, Türkiye

<sup>3</sup>Dokuz Eylül Üniversitesi Tıp Fakültesi, Genel Cerrahi Anabilim Dalı, İzmir, Türkiye

### MEMENİN GRANÜLER HÜCRELİ TÜMÖRÜ: OLGU SUNUMU

#### ÖZET

Granüler hücreli tümör sıklıkla dil, ağız kavitesi ve derialtı yağ dokusunda ortaya çıkan, nadir görülen bir tümördür. Meme, bu tümörün görüldüğü ender lokalizasyonlardan biridir. Granüler hücreli tümör memede genellikle soliter lezyon şeklinde kendini gösterir. Literatürde, çok daha seyrek olarak invaziv ya da in situ duktal karsinomlarla birlikte görülen granüler hücreli tümör olguları bildirilmiştir. Memenin granüler hücreli tümörünün önemi, hem klinik hem de radyolojik bulgularıyla invaziv meme kanserini taklit etmesinden kaynaklanır. Yanlış tanıdan kaçınmak ve gereksiz tedavi yaklaşımlarını önlemek için, ayırıcı tanıda granüler hücreli tümör mutlaka hatırlanmalıdır. Burada, 58 yaşındaki kadın hastamızda görülen granüler hücreli tümör olgusunu, klinik ve radyolojik bulguları ile invaziv meme kanserini taklit etmesi; ayrıca cerrahi sınırdaki tümör pozitifliği nedeniyle yapılan reeksizyon materyalinde rastlantısal hyalinize fibroadenom, yaygın sklerozize adenozis ve şiddetli duktal epitelyal hiperplazi içermesi nedeniyle sunmaya değer bulduk.

**Anahtar sözcükler:** granüler hücreli tümör, meme neoplazmi, fibroadenom, sklerozize adenozis

### ABSTRACT

Granular cell tumor is a rare neoplasm that has been reported in a variety of organs, including the tongue, oral cavity, and subcutaneous tissue. However, breast is an unusual location for this tumor. Most granular cell tumors present as solitary lesions in the breast. There are a few cases of granular cell tumor of the breast, that have been reported, associated with other breast tumors, such as invasive or in situ ductal carcinoma. Because these tumors can mimic invasive breast cancer both with their clinical and radiological findings, they should always be kept in mind in order to avoid misdiagnosis, and prevent unnecessary treatment modalities. Herein, we present a rare case of granular cell tumor of the breast with associated hyalinized fibroadenoma, florid ductal epithelial hyperplasia and sclerosing adenositis, in a 58 year-old female.

**Key words:** granular cell tumor, breast neoplasm, fibroadenoma, sclerosing adenositis

### Introduction

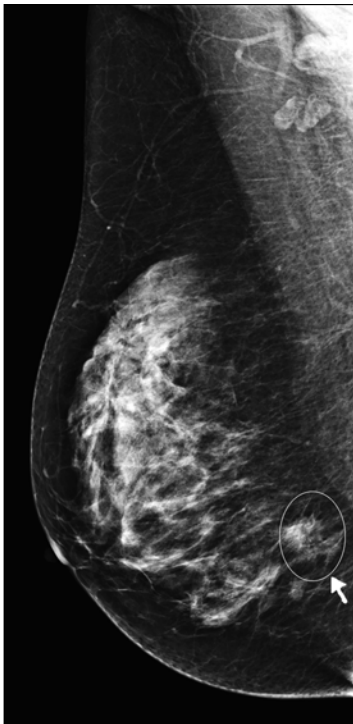
Granular cell tumor (GCT) is a rare neoplasm of putative Schwann cell origin. Although a variety of organs may be affected with this tumor, it usually appears in the tongue, oral cavity, skin and subcutaneous tissue (1-3). Breast is one of the unusual locations for this tumor. Approximately 6% of all cases occur in the breast (4-6). Among all breast cancers, on the other hand, GCT has been reported to occur in 0.1% of cases (2,7).

This entity as a tumor was first described by Abrikossoff (8) in 1926, who attributed its origin to striated muscle cells, and therefore named this tumor as myoblastoma. Subsequently, however, accumulated data from both immunohistochemical and ultrastructural studies have indicated that GCT is derived from peripheral nerve sheath cells (9).

Clinically, GCTs of the breast, because of their firmness and immobility, can easily mimic primary invasive breast cancer. Moreover, on mammography, they can present as ill-defined infiltrative or spiculated lesions, reminiscent of invasive cancer. Therefore, identifying this usually benign tumor and distinguishing it from other malignancies is significant. Herein, we present a rare case of GCT of the breast with associated hyalinized fibroadenoma, florid ductal epithelial hyperplasia and sclerosing adenositis, in a 58 year-old female.

### Case report

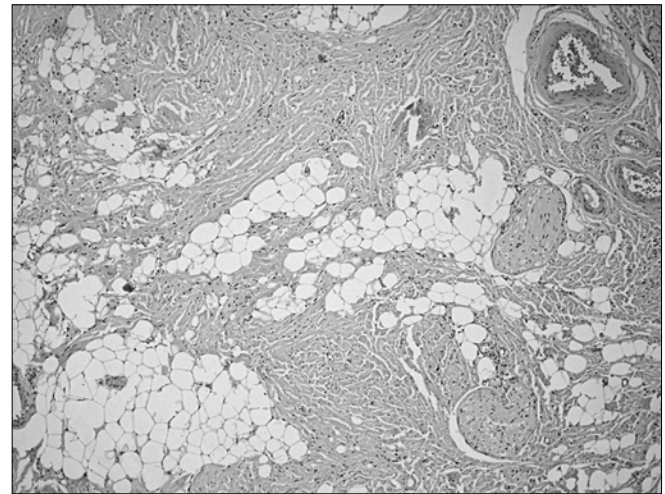
A 58 year-old female presented with a right breast lump. On physical examination, there was a mass in the lower outer quadrant of the right breast. Ultrasonography revealed a hypoechoic, nonhomogeneous mass lesion. Mammography showed a dense shadow



**Figure 1.** Lateral mammogram shows a dense, stellate mass lesion with irregular borders in the lower outer quadrant of the breast (arrow).

with irregular borders and asymmetric smaller densities nearby, suspicious for malignancy (Figure 1). Magnetic resonance imaging (MRI) revealed a mass lesion, 15x10 mm in size, with regular contours, heterogeneous internal structure and intense contrast enhancement.

Wide local excision of the lesion was performed. On gross examination, the excised specimen was 5.5x4.5x2.5 cm in size. Cut surface of the specimen revealed a yellowish-white, solid mass with ill-defined infiltrating borders that was 8x7 mm in size. The lesion was very close to the anteromedial surgical margin. Microscopically, the lesion was composed of nests and cords of large, round or polyhedral cells with granular, eosinophilic cytoplasm and small central or eccentric nuclei. The infiltrative pattern of these cells among thick collagen bundles was prominent (Figure 2). Neither mitotic figures nor pleomorphic cells were observed in the lesion. Immunohistochemical study revealed intense nuclear and cytoplasmic staining for S-100 protein (Figure 3), and cytoplasmic staining for CD68. The tumor cells did not stain with pancytokeratin. On the basis of morphologic and immunohistochemical staining results, the case was diagnosed as benign granular cell tumor of the breast. Due to positivity of the tumor at the anteromedial surgical margin, re-excision of the breast was performed about one month after the first operation. There was no residual tumor in the re-excision specimen. However, extensive sclerosing adenosis, florid epithelial hyperplasia (Figure 4), and an incidental hyalinized fibroadenoma were present. The postoperative period was uneventful, and the patient is well and free of disease after 6 months of operation.

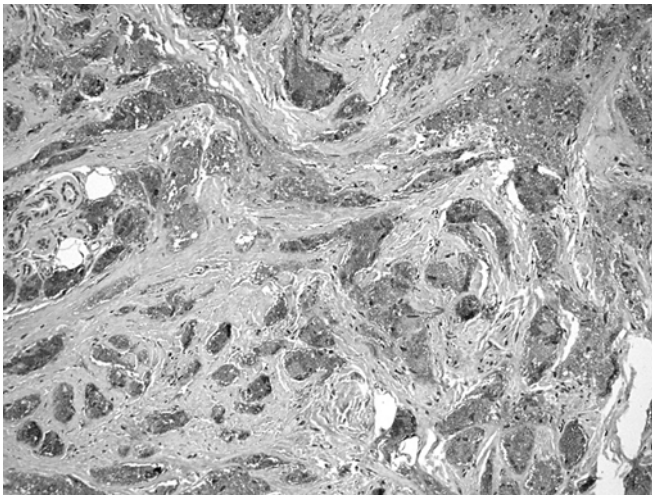


**Figure 2.** Microscopically, the tumor is composed of infiltrative granular cells among thick collagen fibers (H&E, x100).

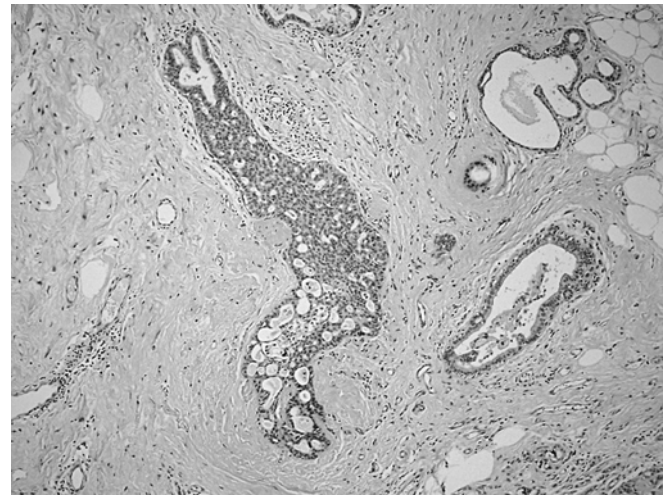
## Discussion

Granular cell tumor is an uncommon, generally benign neoplasm. The most common localization of the tumor is the tongue, that nearly accounts for 30% of all cases, followed by the oral cavity, skin and subcutaneous tissue (1-3). Breast is an unusual site for this tumor, accounting for approximately 6% of all cases (1-3,5,6,9). It occurs predominantly in women between fourth to sixth decades (1,4,9). Its incidence in the breast is estimated to be 0.1% (2,4,7).

Although originally considered a muscle tumor, its close association with nerve and its schwannian features shown both by immunohistochemical staining and electron microscopy, firmly identifies this lesion as a neural tumor (4). GCT predominantly affects the upper inner quadrant and less commonly the lower outer quadrant of the breast, in contrast to invasive breast cancer that is mostly localized to the upper outer quadrant. The cause of this predilection is that, these areas are within the territory of distribution of the cutaneous sensory branches of the supraclavicular nerve (1,4,10). The tumor in our patient was localized in the lower outer quadrant of the breast, similar to case reported by Hoess et al.(2). GCT may mimic invasive breast cancer clinically, radiologically, and even by gross pathologic examination. Clinically, GCT of the breast generally presents as a firm, painless mass that may be partly mobile. Superficial lesions may cause nipple inversion or skin retraction, which makes the differential diagnosis even harder. The ultrasonographic and mammographic features of the tumor can be misleading as well. Radiologic appearance varies from a stellate mass that is difficult to distinguish from a carcinoma to well circumscribed nearly benign appearing mass lesion (10). On gross examination, the lesion is generally more sharply circumscribed than typical invasive carcinoma. However, the hard consistency and somewhat irregular outline of the tumor necessitates microscopic inspection in order to exclude malignancy. It is therefore impossible to establish a definitive diagnosis of GCT of the breast without a biopsy.



**Figure 3.** Immunohistochemical staining of S-100 protein shows nuclear and cytoplasmic positivity in tumor cells (S-100, x200).



**Figure 4.** Some ducts in the nontumoral breast parenchyma in the re-excision specimen showed florid type ductal epithelial hyperplasia (H&E, X40).

Microscopically, the tumor is composed of nests and sheets of large polygonal cells with granular, eosinophilic cytoplasm. The granules, representing phagolysosomes, are strongly PAS positive, diastase resistant. The cell borders are typically well defined. Usually, variable amounts of collagenous stroma is present. Small nerve bundles are occasionally seen within the tumor, or nearby. Even in tumors that seem to be circumscribed grossly, microscopic examination usually shows the infiltrative growth pattern of the tumor.

Association of GCT of the breast with other breast tumors is not common. Tran et al.(9), Mulcare (11) and Gordon et al.(12) have reported cases of invasive breast cancer and GCT in the same breast, developed either synchronously or metachronously. Similarly, Al-Ahmadie et al. (1) have described association of GCT of the breast with invasive and in situ carcinomas of the breast. The case described by Tai et al. (13), on the other hand, was a simultaneous development of invasive breast cancer in one breast and GCT in the contralateral breast.

Malignant GCTs are very rare. They constitute less than 1% of all cases. Currently, histological criteria proposed by Le et al.(14) and Adeniran et al.(15) are being used to discriminate benign from malignant GCT. The presence of necrosis, nuclear pleomorphism, high nuclear/cytoplasmic ratio, vesicular nuclei with large nucleoli, spindling of the cells, and increased mitotic activity (>2 mitoses per 10 HPF at x200 magnification) are evaluated (14, 15). Histologically, when two of these six criteria are present, the case is diagnosed as atypical GCT. If three or more criteria exist, the lesion is more likely to behave in a malignant fashion. In our case, none of these criteria were present.

The differential diagnosis of GCT is diverse, and includes both benign lesions such as inflammatory fat necrosis and sclerosing adenosis; malignant lesions such as apocrine carcinoma, secretory carcinoma; and metastatic lesions. Pleomorphic lobular carcinoma should also be in the differential diagnosis, because it may show apocrine or histiocytoid differentiation (16-18). The most common metastatic tumors that can be confused with GCT are tumors that have oncocytic or clear cell features, such as renal cell carcinoma, malignant melanoma and alveolar soft part sarcoma (4). An immunohistochemical stain for pancytokeratin can be used to highlight the presence of epithelial component in these tumors. Apocrine carcinomas show positive immunostaining with gross cystic disease fluid protein-15 (GCDFP-15) and androgen receptor, as well as epithelial membrane antigen (EMA). Secretory carcinomas, although may show S-100 protein positivity, are also immunoreactive for polyclonal carcinoembryonic antigen (CEA) and  $\alpha$ -lactalbumin. Intense nuclear and cytoplasmic staining for S-100 protein and cytoplasmic staining for CD68, in addition to negative staining, with pancytokeratin, supported our diagnosis of GCT, in our case.

In conclusion, we report a case of GCT of the breast with associated florid epithelial hyperplasia, extensive sclerosing adenosis, and an incidental hyalinized fibroadenoma. GCT of the breast, although seen very rarely compared to invasive breast cancer, should always be kept in mind in an infiltrative lesion composed of cells with eosinophilic granular cytoplasm. Diagnosis of GCT would prevent unnecessary additional treatment modalities.

## References

1. Al-Ahmadie H, Hasselgren PO, Yassin R, Mutema G. Colocalized granular cell tumor and infiltrating ductal carcinoma of the breast: A case report and review of the literature. *Arch Pathol Lab Med* 2002;126:731-733. (PMID:12033967)
2. Hoess C, Freitag K, Kolben M, Allgayer B, Laemmer-Skarke I, Nathrath WBJ, Avril N, Roemer W, Schwaiger M, Graeff H. FDG PET evaluation of granular cell tumor of the breast. *J Nucl Med* 1998;39:1398-1401. (PMID: 9708516)
3. Mariscal A, Perea RJ, Castella E, Rull M. Granular cell tumor of the breast in a male patient. *AJR* 1995;165:63-64. (PMID: 7785634)
4. Filipovski V, Banev S, Janevska V, Dukova B. Granular cell tumor of the breast: A case report and review of literature. *Cases J* 2009;2:8551. (PMID: 19918386)
5. Kim EK, Lee MK, Oh KK. Granular cell tumor of the breast. *Yonsei Med J* 2000;41:673-675. (PMID: 11079631)
6. Scaranelo AM, Bukhanov K, Crystal P, Mulligan AM, O'Malley FP. Granular cell tumor of the breast: MRI findings and review of the literature. *Br J Radiol* 2007;80:970-974. (PMID: 17940129)
7. Ilvan S, Ustundag N, Calay Z, Bukey Y. Benign granular cell tumor of the breast. *Can J Surg* 2005;48:155-156. (PMID: 15887799)
8. Abrikossoff A. Ueber Myome ausgehend von der quergestreiften, willkürlichen Muskulatur. *Virchows Arch (Pathol Anat)* 1926;260:215-233.
9. Tran TA, Kallakury BVS, Carter J, Wolf BC, Ross JS. Coexistence of granular cell tumor and ipsilateral infiltrating ductal carcinoma of the breast. *South Med J* 1997;90:1149-1151. (PMID: 9386062)
10. Patel A, Lefemine V, Yousuf SM, Abou-Samra W. Granular cell tumor of the pectoral muscle mimicking breast cancer. *Cases J* 2008;1:142. (PMID: 18775077)
11. Mulcare R. Granular cell myoblastoma of the breast. *Ann Surg* 1968;168:262-268. (PMID: 4298809)
12. Gordon AB, Fisher C, Palmer B, Greening WP. Granular cell tumor of the breast. *Eur J Surg Oncol* 1985;11:269-273. (PMID: 2993035)
13. Tai G, D'Costa H, Lee D, Watkins RM, Jones P. Case report: coincident granular cell tumor of the breast with invasive ductal carcinoma. *Br J Radiol* 1995;68:1034-1036. (PMID: 7496688)
14. Le BH, Boyer PJ, Lewis JE, Kapadia SB. Granular cell tumor: Immunohistochemical assessment of inhibin-alpha, protein gene product 9.5, S100 protein, CD68, and Ki-67 proliferate index with clinical correlation. *Arch Pathol Lab Med* 2004;128:771-775. (PMID: 15214825)
15. Adeniran A, Al-Ahmadie H, Mahoney MC, Robinson-Smith TM. Granular cell tumor of the breast: a series of 17 cases and review of the literature. *Breast J* 2004;10:528-531. (PMID: 15569210)
16. Özen Ö, Şar A, Demirhan B. Memenin apokrin karsinomunun ayırıcı tanısında morfolojik, histokimyasal ve immünohistokimyasal bulgular. *Meme Sađlığı Dergisi* 2007; 3(2): 69-74.
17. Tavassoli FA, Devilee P. World Health Organization Classification of Tumors. Pathology and Genetics of Tumors of the Breast and Female Genital Organs. Lyon: IARC Press, 2003.
18. Akbulut M, Zekiođlu O, Özdemir N, Yeniay L, Kapkaç M. Memenin histiositoid karsinomu: bir olgu sunumu. *Ege Tıp Dergisi* 2006; 45(3): 195-198.

## Correspondence

Merih Güray Durak

Phone : +90(232) 4123419

E-mail : merih.guray@deu.edu.tr