

ARE ABDOMINAL PAIN AND DISTENTION SYMPTOMS OF BREAST CANCER?

Sadullah Girgin¹, Akın Önder¹, Murat Kapan¹, Uđur Fırat², Zülfü Arıkanođlu¹, Mehmet Küçüköner³

¹Dicle University Faculty of Medicine, Department of General Surgery, Diyarbakır, Türkiye

²Dicle University Faculty of Medicine, Department of Pathology, Diyarbakır, Türkiye

³Dicle University Faculty of Medicine, Department of Medical Oncology, Diyarbakır, Türkiye

KARIN AđRISI VE ŐİŐKİNLİK MEME KANSERİNİN BELİRTİSİ MİDİR?

ÖZET

Meme kanseri genellikle kemik, akciđer, karaciđer ve santral sinir sistemine metastaz yapar. İzole peritoneal meme kanseri metastazı oldukça nadir görülür. Kliniđimize karınađrısı Őikayeti ile bař vuran hastanın sistemik muayenesinde, abdominal distanssiyon, asit ve memede kitle tespit edildi. Memeden alınan bşyopsi invazif duktal karsinom ve laparoskopik peritoneal biyopsi sonucu ise meme kanseri metastazı olarak deđerlendirildi. palyatif kemoterapi plannanan hasta tedaviyi kabul etmedi. Altı ay takip edilen hastada bařka bir metastaz geliřmedi.

Anahtar sözcükler: Karın ađrısı, meme kanseri, peritoneal tümörler, metastaz

ABSTRACT

Breast cancer usually metastasizes to bone, lungs, liver and central nervous system. Rarely, atypical metastases may occur. Isolated peritoneal metastasis of breast cancer is very uncommon. On systemic examination of a 50-year-old woman who presented to our outpatients' clinic with the complaints of abdominal pain and distention, abdominal ascites and a breast mass were found. Biopsy from the breast mass revealed invasive ductal carcinoma and laparoscopic peritoneal biopsy showed peritoneal metastasis of the breast cancer. Palliative chemotherapy was planned. The patient rejected the treatment and has been under follow-up for 6 months does not have any other metastasis now.

Key words: Abdominal pain, breast cancer, peritoneal neoplasms, metastasis

Introduction

Breast cancer is a disease very common among women; it can be diagnosed in early stages with screening efforts and increasing awareness of the population. However, metastases can be recognized at the time of the diagnosis or during follow-up after surgery (1). Breast cancer usually metastasizes to bone, lungs, liver and central nervous system (1). Peritoneal metastasis is a rarely encountered situation in the patients with breast cancer. Herein, we presented a patient with breast cancer who presented with isolated peritoneal metastasis.

Case report

A 50-year-old woman came to our clinic with the complaints of abdominal pain and distention persisting for three months and worsening in the last month; she had a medical history of lung tuberculosis treatment 5 years ago. The patient had come to our clinic 6 months ago because of a mass in her right breast. Core biopsy was offered, but she rejected the intervention. On physical examination, diffuse abdominal ascites, a breast mass with irregular margins 30x20 mm in size in the right upper outer quadrant, and two mobile ipsilateral axillary lymph nodes sized approximately 20x20 mm were found. Laboratory tests revealed hypoalbuminemia, borderline high erythrocyte sedimentation

rate (19 mm/h) and elevated levels of CA15-3 and CA 125 (300 and 516 U/ml, respectively). Ultrasonographic examination showed a lesion sized 15 mm in dimension in the right lobe superior segment of the liver, which was consistent with the liver cyst, and diffuse fluid accumulation in the peritoneal space. Furthermore, there were cystic lesions 3.6 mm in diameter in the uterus and 5 mm in diameter in the cervix, and septated cystic lesions with dense content 37x31 mm in size in the right ovary and 15 mm in diameter in the left ovary. On the computerized abdominal tomography, minimal gastric wall thickness and a hypodense cystic lesion 12x7 mm in size in the segment 7 of the liver were seen. Breast ultrasonography showed a heterogenic hypoechoic lesion with smooth margins 28x13 mm in size in the right breast upper outer quadrant; mammography showed several asymmetric opacities of which the largest one was 10 mm in diameter. Core biopsy was performed to that mass in the breast. The tuberculin skin test (PPD) done to evaluate the reason for abdominal pain and ascites with the recommendations of the clinic of the pulmonary diseases and tuberculosis because of the previous history of tuberculosis of the patient was negative, sputum test did not yield any growth of acid-fast bacilli (AFB). Microbiologic examination of the abdominal fluid did not show any growth of bacilli. The Erlich-Ziehl-Neelsen staining did not show any AFB. Upper and lower gastrointestinal system endoscopies were performed to diagnose

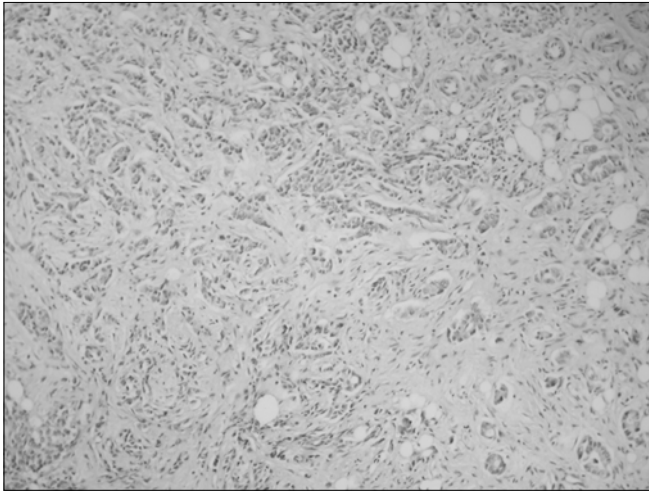


figure 1. Tubular formations was showing at the infiltrating tumor have occurred desmoplastic stroma area. (H&E stain, x100)

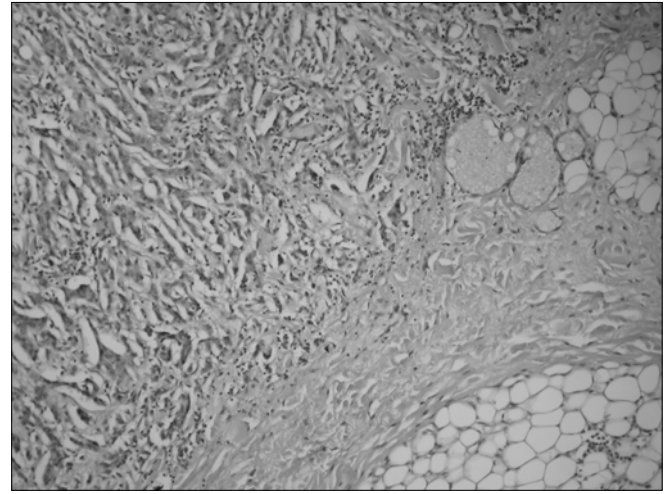


figure 2. Infiltrating tumor cell groups have seen at the peritoneal tissue, was noteworthy (H&E boyama, x100)

the primary tumor since the cytology of the ascites showed malign cells were normal. The clinics of obstetrics and gynecology evaluated the uterine and ovarian lesions; cervical smear result was benign, primary ovarian cancer was not assumed for the ovarian lesion. The result of the breast core biopsy was reported as invasive ductal carcinoma. ¹⁸F¹⁸FDG positron emission tomography was done to identify an additional focus of malignancy and metastasis reported the malign mass in the right breast, abdominal malign ascites, and hyper metabolic lymph nodes in the right axillary area.

The patient had a right modified radical mastectomy and laparoscopic peritoneal biopsy with the initial diagnosis of breast cancer and peritoneal metastasis. She was discharged from the hospital on postoperative day 10 without any problem. Histopathology reported tumor mass in the breast 30x25x13 mm in size as invasive ductal carcinoma (Figure 1), all 17 lymph nodes removed from the axilla as metastatic lymph nodes. Its histologic classification was grade II according to the modified Bloom Richardson classification. In immunohistochemistry studies showed that 20% of the cells were positive for estrogen receptor, 90% was positive for progesterone receptor and Cerb-B₂ was negative. The result of peritoneal biopsy was reported as the metastasis of the invasive ductal carcinoma. immunohistochemistry of peritoneal metastasis studies showed accordance with breast carcinoma (Figure 2). The patient was referred to the department of medical oncology. The palliative treatment protocol was planned for the patient. But she rejected the treatment. The patient has been under follow-up care for 6 months does not have any additional metastasis at present.

Discussion

Peritoneal invasion and ascites in the abdomen are usually associated with metastatic tumors of gastrointestinal and ovarian cancers (2). Another cause is tuberculosis peritonitis that may be confused with primary and metastatic peritoneal malignancies

because of nonspecific clinical symptoms such as fever, abdominal pain, ascites and elevated serum CA 125 level (3). Rarely, the cause is the primary peritoneal tumor originated from the serosal mesothelial cells which may have an aggressive clinical course (4). CA 15-3 may increase in metastatic breast carcinoma as well as in benign breast and liver diseases, ovarian and lung carcinomas (5). In such cases, the diagnosis is made by peritoneal biopsy (3,4). Similar to the literature data, our patient had the complaints of abdominal pain, distention and nausea. There was diffuse ascites in the abdomen and the levels of CA 15-3 and CA 125 were elevated. It was difficult to clinically make differential diagnosis among primary tumor, tuberculosis peritonitis or metastatic tumor. Hence, the diagnosis was achieved by laparoscopic peritoneal biopsy.

Invasive ductal cancers that account for 75% of the breast cancers usually metastasize to the lungs and pleura, whilst lobular invasive cancers mostly metastasize to gastrointestinal system, gynecologic organs, peritoneum and retroperitoneal region. However, it has been reported that ductal type and medullary type breast cancers, although rare, are likely to metastasize to the gastrointestinal system (6). Peritoneal metastases of breast cancers are often recognized years after the initial diagnosis, there are few cases in the literature who show the metastases at the time of the initial diagnosis (7). The presence of peritoneal metastases of breast cancer generally indicates lobular invasive carcinoma, in contrast, our patient was diagnosed with invasive ductal carcinoma. It was noteworthy that our patient was not locally advanced stage with the coexistence of isolated peritoneal metastasis.

The main treatment for peritoneal metastasis of breast cancer involves the intervention for the ascites and palliative chemotherapy (8). After the diagnosis was made, chemotherapy and palliative treatment for the ascites were planned. The patient underwent follow-up for 6 months, and does not have any additional metastasis at present.

In conclusion, although breast cancer is a systemic disease that may spread all the body, peritoneal metastasis develops only in advanced stage. Concurrent isolated peritoneal metastasis of breast cancer is very rare. In the patients presenting with the complaints of abdominal pain and ascites, isolated peritoneal

metastasis of the breast cancer should be considered. It is often originated from lobular carcinoma, however, invasive ductal carcinoma should also be considered. Systemic examination should be done, as in the patient presented here, to avoid neglecting the principal pathology.

References

1. Atalay C, Yılmaz KB, Altınok M. Laryngeal Metastases In Breast Cancer. Meme Sag Der 2006; 2: 139- 140
2. Pentheroudakis G, Pavlidis N. Serous papillary peritoneal carcinoma: Unknown primary tumour, ovarian cancer counterpart or a distinct entity? A systematic review. Crit Rev Oncol Hematol 2009;[Medline]
3. Mihmanlı A, Bilgin S, Özşeker F, Baran A, Güneyliođlu D, Akkaya E. Diagnosis of Tuberculous Peritonitis. Toraks Dergisi 2003;4:21-24
4. Altıntoprak F, Müderris V, Dikicier E, Kahyaođlu Z, Kıvılcım T, Arslan Y, Akbulut G, Dilek O.N. A rare ethiology of intraabdominal mass; malignant mesothelioma. Case report. Journal of Surg Arts 2010;2:18- 21.
5. Serter M, Aktođu S, Erer O.F, Yenisey Ç. Plevral Effüzyonların Ayrımlanmasında CA 125, CA 19,9 ve CA 15,3'ün kullanımı. Deü Tıp Fakültesi dergisi 2004; 2:125-132
6. Kobayashi T, Adachi S, Matsuda Y, Tominaga S. A Case of Metastatic Lobular Breast Carcinoma with Detection of the Primary Tumor after Ten Years. Breast Cancer 2007;14:333-336
7. Law WL, Chu KW. Scirrhus colonic metastasis from ductal carcinoma of the breast: report of a case. Dis Colon Rectum 2003; 46:1424-1427.
8. Deraco M, Casali P, Inglese MG, Baratti D, Pennacchioli E, Bertulli R, et al. Peritoneal mesothelioma treated by induction chemotherapy, cytoreductive surgery, and intraperitoneal hyperthermic perfusion. J Surg Oncol Jul 2003;3:147-153.

Correspondence

Sadullah Girgin
Tel : +90 (412) 248 80 01
E-mail : sadullahgirgin@gmail.com