








Encapsulated Papillary Carcinoma in A Man with Gynecomastia: Ultrasonography, Mammography and Magnetic Resonance Imaging Features with Pathologic Correlation

Ravza Yılmaz¹ , Rana Günöz Cömert¹ , Samil Aliyev¹ , Yücel Toktaş¹ , Semen Önder² , Selman Emirikçi³ ,
Vahit Özmen³ 

¹Department of Radiology, İstanbul University, İstanbul School of Medicine, İstanbul, Turkey

²Department of Pathology, İstanbul University, İstanbul School of Medicine, İstanbul, Turkey

³Department of Surgery, İstanbul University, İstanbul School of Medicine, İstanbul, Turkey

ABSTRACT

Male breast cancer is an uncommon disease that constitutes 1% of all breast cancers and encapsulated papillary carcinoma (EPC) is a rare subtype of malignant male diseases. Gynecomastia is the most common disease of the male breast. We report a 63-year-old male patient with EPC accompanied by gynecomastia that was diagnosed and treated at our breast center. Mammography showed an oval-shaped dense mass with circumscribed margins on the ground of nodular gynecomastia. On ultrasonographic exam, we saw a well-circumscribed complex mass with a solid component which was vascular on Doppler ultrasonography. Magnetic resonance imaging revealed a complex cystic mass containing solid components. Dynamic images showed enhancement of the cystic mass wall and mural components. Tumor stage was evaluated as T2N0. The lesion's histologic examination and immunohistochemical analysis by showing no myoepithelial layer revealed an encapsulated papillary carcinoma. To our knowledge, this is the first case report which describes MR imaging findings of male breast encapsulated papillary cancer.

Keywords: Encapsulated papillary carcinoma, intracystic papillary carcinoma, male, gynecomastia, magnetic resonance imaging

Cite this article as: Yılmaz R, Günöz Cömert R, Aliyev S, Toktaş Y, Önder S, Önder S, Emirikçi S, Özmen V. Encapsulated Papillary Carcinoma in A Man with Gynecomastia: Ultrasonography, Mammography and Magnetic Resonance Imaging Features with Pathologic Correlation. Eur J Breast Health 2018; 14: 127-131.

Introduction

Male breast cancer accounts for 1% of all breast cancers and 0.17% of all male cancers (1). The papillary variant of breast cancer represents 3 to 5% of cases in men, which is more common than women representing 1 to 2% of cases (2). Based on recent immunohistochemical studies, intracystic papillary carcinoma is called encapsulated papillary carcinoma (EPC) (3). Imaging findings of EPC in women have been reported in the literature many times (4-7). Mammography (MG) and ultrasonography (US) findings of male EPC was reported in a few case reports (8-10). However, to our knowledge, magnetic resonance (MR) imaging features of EPC in a male patient has been described in only one case which was an incomplete assessment (11). We report MG, US and MR imaging findings of a 63-year-old male patient with bilateral gynecomastia and a right subareolar palpable mass. This is the second case report of male breast encapsulated papillary cancer that included MR imaging features.

Case Presentation

A 63-year-old male who had a 1.5-year history of a mass located just below his right areolar region. He was admitted to our clinic because the mass has recently grown painless. There were no risk factors of breast cancer in his history. He did not have any systemic illness or drug usage history; routine blood and urine tests were normal. His BMI was 24. On physical examination, a 2 cm mobile mass was palpated in the right subareolar region. No skin abnormality was noted on inspection. Axillary examination was unremarkable. Bilateral craniocaudal and mediolateral oblique MG demonstrated an ellipsoidal nodular density under bilateral areolas considered as gynecomastia. These nodular appearances were evaluated as nodular gynecomastia. The right MG also showed an oval-shaped dense mass with circumscribed margins adjacent to gynecomastia (Figure 1). On US, we found a 23x19 mm well-circumscribed, predominantly cystic mass with solid components that evaluated as complex lesion. Increased blood flow was present within the solid components on Doppler US (Figure 2). Hypochoic area compared to regional fat tissue that represented fibroglandular enlargement compatible with gynecomastia was seen on US in both breasts. MR images revealed a cir-

Address for Correspondence:

Ravza Yılmaz, e-mail: ravzayilmaz@gmail.com

Received: 17.08.2017
Accepted: 28.11.2017

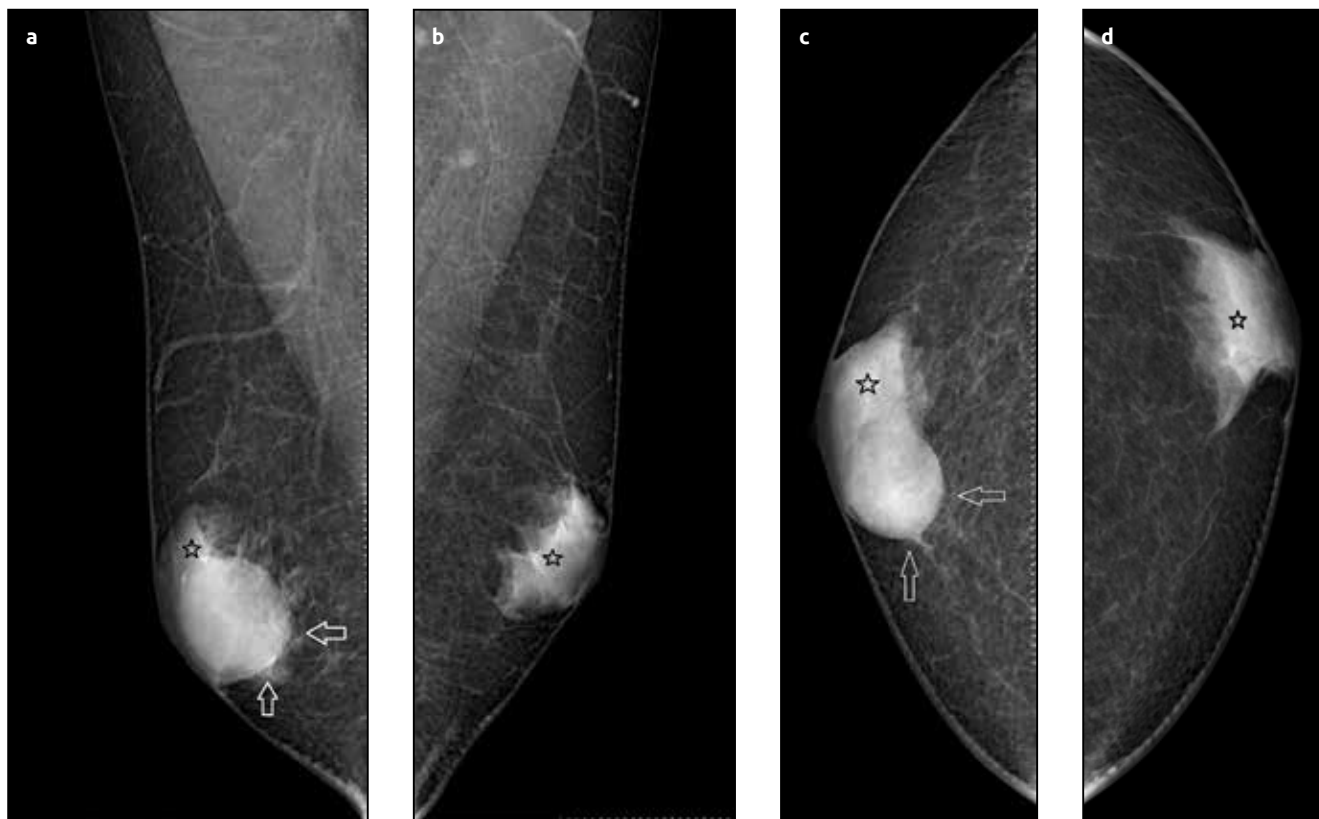

Figure 1. (a-d). Bilateral craniocaudal and mediolateral oblique MG demonstrated nodular gynecomastia (stars). Oval-shaped dense mass with posterior-inferior circumscribed margins adjacent to gynecomastia on the right breast (arrows)

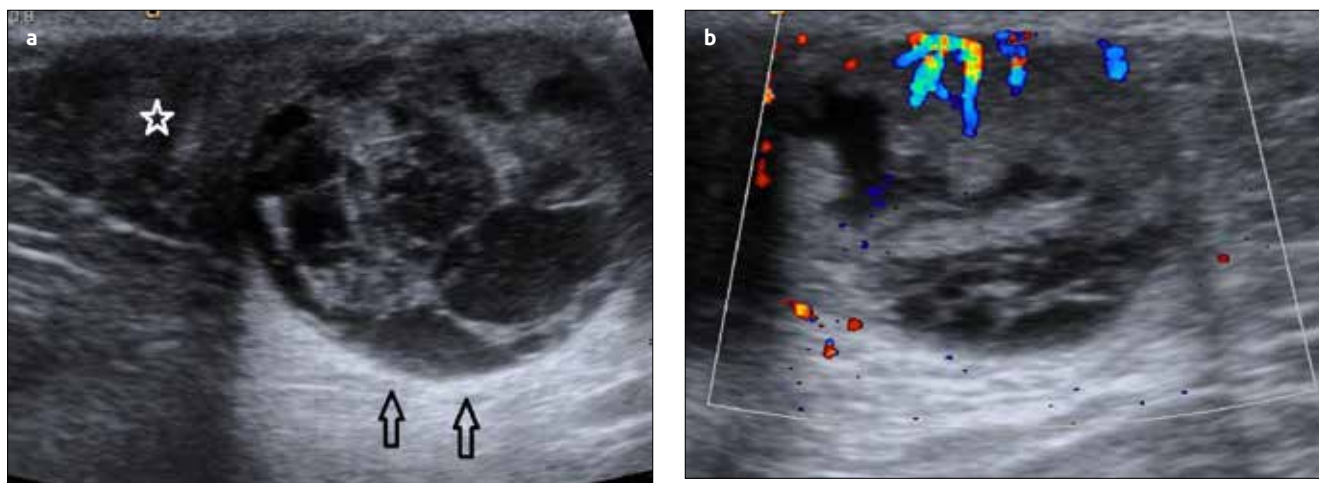


Figure 2. (a-b). US demonstrated hypoechoic glandular structure compatible with gynecomastia (star) and well-circumscribed mass shows predominantly cystic with solid components-thick septations that evaluated as complex lesion. Posterior acoustic enhancement was seen (stars) (a). On Doppler US, blood flow was seen in the solid components (b)

cumsccribed hypointense mass and bilateral hypointense parenchyma on pre-contrast T1-weighted sequences. Axial T2-weighted images revealed complex mass containing hypointense solid components and hyperintense cystic component. Axial T1-weighted contrast-enhanced subtraction images revealed enhancement of the cystic mass wall and solid components. Sagittal post-contrast images showed a circumscribed complex mass with a cystic component (star) and markedly enhancing wall and solid nodules (Type III kinetic curve/suggestive of malignancy-not illustrated) (Figure 3). The lesion was reported as intracystic mass with a preliminary diagnosis of papillary carcinoma. Core needle biopsy was performed under

US guidance. Histopathologically, the lesion had few papillary folds and was filled with uniform tumoral cells. Immunohistochemical analysis also confirmed no myoepithelial cells were stained with p40 in the lesion. So the final pathological diagnosis was EPC (Figure 4). Simple mastectomy was performed with axillary sentinel lymph node sampling. The size of the specimen was 15 cm and the tumor size was 2.5 cm. All 4 sentinel lymph nodes were negative. Receptor status was ER: 90% and PR:90%. The tumor cells were moderately differentiated (grade 2) and tumor stage was reported as T2N0. Written informed consent was obtained from the patient.

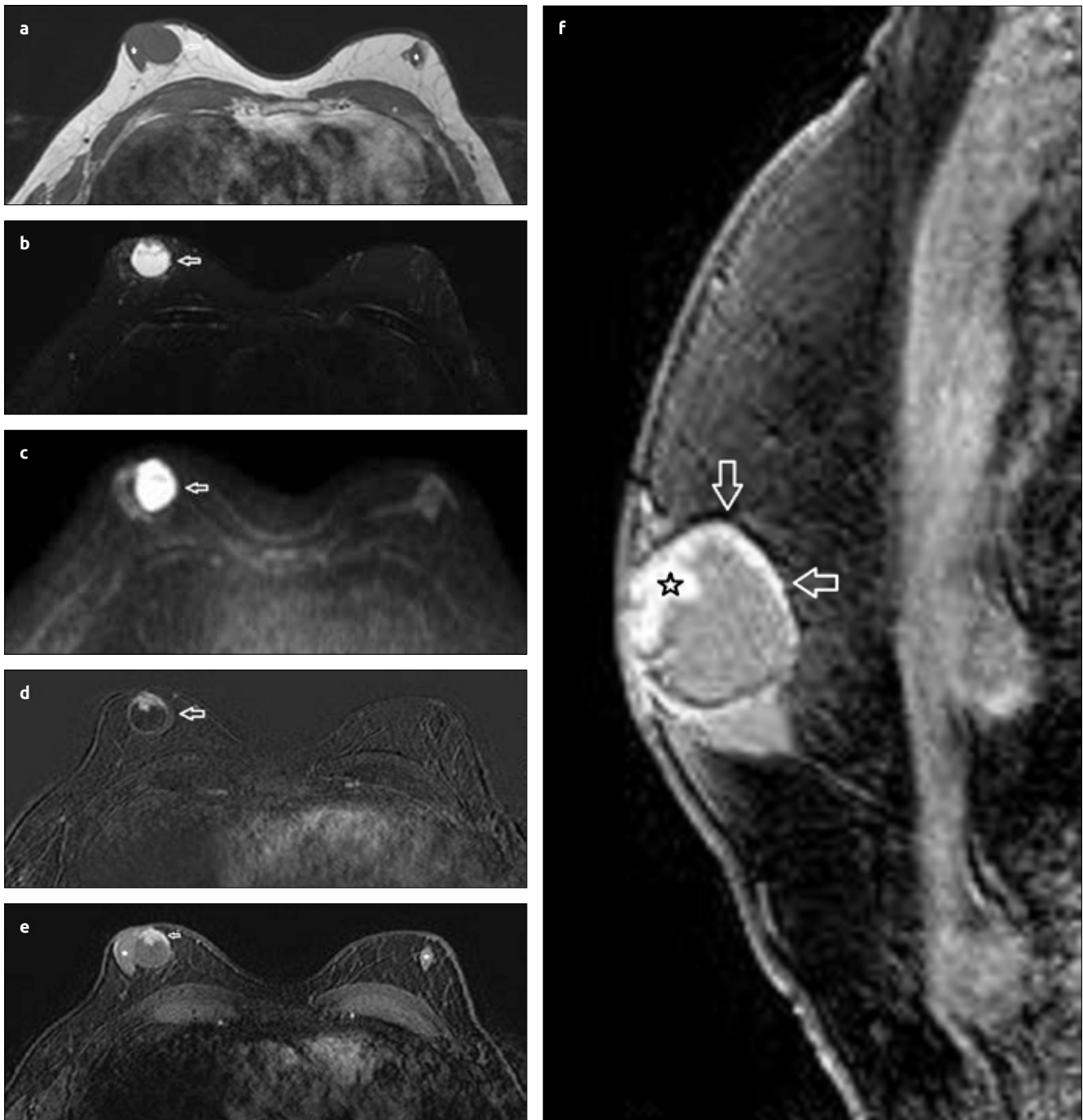


Figure 3. (a-f). a) MR images revealed a circumscribed hypointense mass (arrow) and bilateral hypointense parenchyma (stars) on pre-contrast T1-weighted image (a). Hyperintense complex cystic mass containing hypointense solid component (arrow) was seen on axial T2-weighted image (b). In diffusion-weighted image, the mass shows high signal intensity (c). Axial T1-weighted contrast-enhanced subtraction image showed enhancement of walls of cystic mass and solid nodules (d). Axial post-contrast T1-weighted gadolinium-enhanced image showed mass (arrow) and glandular appearance compatible with gynecomastia (stars) (e). Sagittal post-contrast image showed a circumscribed complex mass with a cystic component and marked enhancing solid nodules (arrows) and peripheral wall (star) (f)

Discussion and Conclusion

Encapsulated papillary carcinoma is a localized, encysted kind of papillary ductal cancer that surrounded by a fibrous capsule found within a dilated duct. EPC may be asymptomatic or present with a bloody nipple discharge or palpable mass. Many cases were also described in the male population in the literature, (12). The average age of EPC is higher than the other types of breast

cancer, being 65-year old (13). Gynecomastia is quite common in male breast. In our patient, cancer and gynecomastia was diagnosed at the same time. Gynecomastia is not an independent risk factor for male breast cancer; most of the time, it presents concurrently with relative estrogen excess associated clinical conditions. Usually, this tumor can show benign MG findings as a well-circumscribed, round or oval mass. However, true diagnosis of EPC can be made by adding US. US was absolutely necessary to evaluate internal structure of this

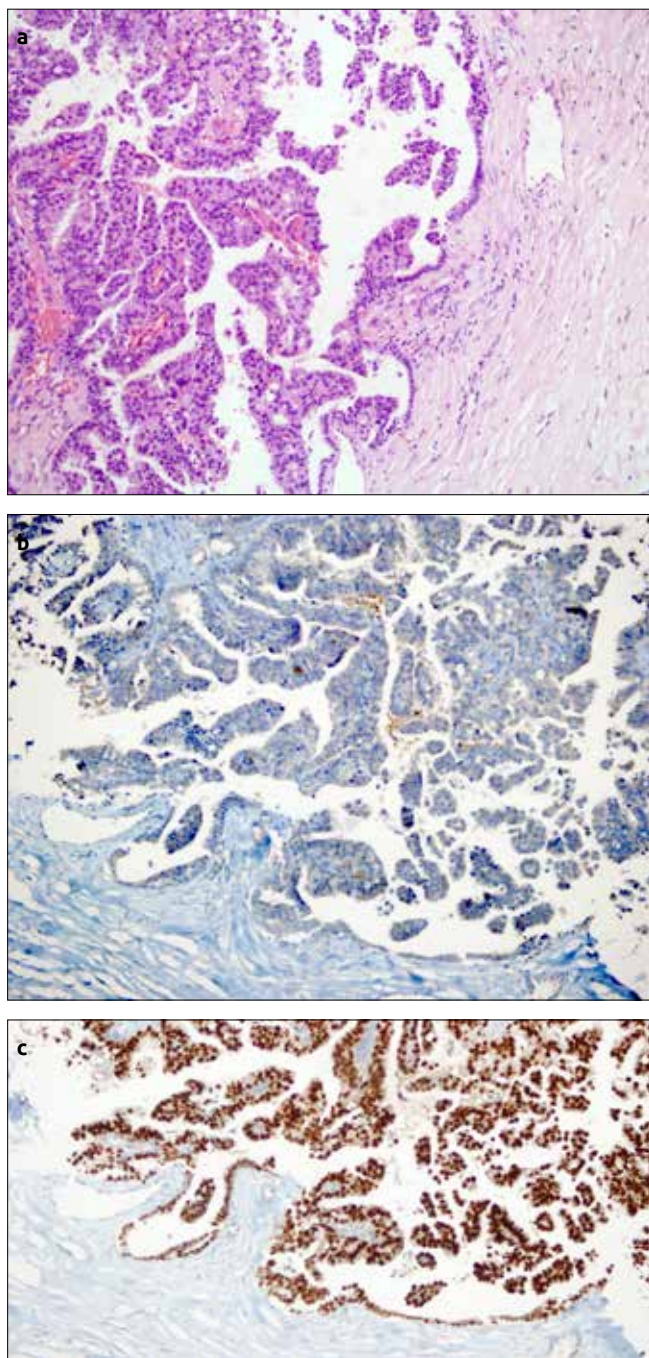


Figure 4. (a-c). Papillary configuration of the lesion within capsule (H&E, x20, original magnification) (a). No myoepithelial cells stained with p40 in the lesion (p40, x20, original magnification) (b). ER positivity is high in the lesion (ER, x20, original magnification) (c)

mass which typically reveals complex appearance that includes a cystic area with solid components originating from the wall of the cyst.

Magnetic resonance imaging can give additional information about the morphological features and the local extension of the mass for preoperative mapping (14, 15). At MR imaging, round or oval mass with circumscribed margins has typical heterogeneous internal composition with solid nodules of intermediate signal intensity and also depends on the cystic component. EPC shows strongly enhancing cyst wall and solid nodules on post-contrast images. Differentiating EPC from intracystic papilloma is difficult, however MR

imaging can guide us by showing the types of the kinetic curves of the solid nodules that demonstrate the presence of cancer (15). Even pathologically, EPC can be misdiagnosed as intraductal papilloma especially in small biopsies. Showing presence of myoepithelial layer is enough to give a diagnosis of intraductal papilloma. The recommended treatment is surgical excision with negative margins. Sentinel lymph node biopsy is recommended when tumor shows clinical N0 as usual breast cancer.

In conclusion, EPC in male breast is an extremely rare entity; however, cystic lesions in men should be worked up as potentially malignant lesions. MG and US together provide valuable information to direct us to the correct diagnosis. MR imaging of EPC in male breast has similar features as in female breast. Round or oval shape with predominantly circumscribed margins and the complex appearance of solid and cystic components are the specific features of EPC on US and MR imaging. Absence of myoepithelial cell layer by immunohistochemical study is significant for pathologic diagnosis.

Informed Consent: Written informed consent was obtained from patient who participated in this study.

Peer-review: Externally peer-reviewed

Author Contributions: Concept - R.Y., Y.T.; Design - R.Y., R.G.C.; Supervision - R.Y., V.O.; Resources - R.Y., S.A.; Materials - R.Y., S.E.; Data Collection and/or Processing - R.Y., R.C.G.; Analysis and/or Interpretation - R.Y., S.O.; Literature Search - R.Y., R.C.G.; Writing Manuscript - R.Y., S.A.; Critical Review - R.Y., V.O.

Acknowledgements: Authors would like to thank patients who participated this study.

Conflict of Interest: No conflict of interest was declared by the authors.

Financial Disclosure: The authors declared that this study has received no financial support.

References

1. Boring CC, Squires TS, Tony T, Montgomery S. Cancer statistics, 1994. *CA Cancer J Clin* 1994; 44: 7-26. (PMID: 8281473) [[CrossRef](#)]
2. Rosen PP. Carcinoma of the Male Breast. In: Rosen's Breast Pathology. 2nd ed. Philadelphia, PA: Lippincott Williams & Wilkins; 2001: 713-728.
3. Mulligan AM, O'Malley FP. Papillary lesions of the breast: a review. *Adv Anat Pathol* 2007; 14: 108-119. (PMID: 17471117) [[CrossRef](#)]
4. Schneider JA. Invasive papillary breast carcinoma: mammographic and sonographic appearance. *Radiology* 1989; 171: 377-379. (PMID: 2649917) [[CrossRef](#)]
5. Liberman L, Feng TL, Susnik B. Case 35: intracystic papillary carcinoma with invasion. *Radiology* 2001; 219: 781-784. (PMID: 11376269) [[CrossRef](#)]
6. Eiada R, Chong J, Kulkarni S, Goldberg F, Muradali D. Papillary lesions of the breast: MRI, ultrasound, and mammographic appearances. *AJR Am J Roentgenol* 2012; 198: 264-271. (PMID: 22268167) [[CrossRef](#)]
7. Lattin GE Jr, Jesinger RA, Mattu R, Glassman LM. From the radiologic pathology archives: diseases of the male breast: radiologic-pathologic correlation. *Radiographics* 2013; 33: 461-489. (PMID: 23479708) [[CrossRef](#)]
8. S H, Hariprasad P, Srinivas T. Intracystic papillary carcinoma of the breast in males: a case report and review of the literature. *J Clin Diagn Res* 2013; 7: 568-570. (PMID: 23634426)
9. Johnson JB, Emory TH. Intracystic Papillary Carcinoma in a Man with Gynecomastia. *Radiol Case Rep* 2015; 3: 214. (PMID: 27303554) [[CrossRef](#)]

10. Blaumeiser B, Tjalma WA, Verslegers I, De Schepper AM, Buytaert P. Invasive papillary carcinoma of the male breast. *Eur Radiol* 2002; 12: 2207-2210. (PMID: 12195471) [\[CrossRef\]](#)
11. Grabowski J, Salzstein SL, Sadler GR, and Blair S. Intracystic papillary carcinoma: a review of 917 cases. *Cancer* 2008; 5: 916-920. (PMID: 18661510) [\[CrossRef\]](#)
12. Akagi T, Kinoshita T, Shien T, Hojo T, Akashi-Tanaka S, Murata Y. Clinical and pathological features of intracystic papillary carcinoma of the breast. *Surg Today* 2009; 39: 5-8. (PMID: 19132460) [\[CrossRef\]](#)
13. Soo MS, Williford ME, Walsh R, Bentley RC, Kornguth PJ. Papillary carcinoma of the breast: imaging findings. *AJR Am J Roentgenol* 1995; 164: 321-326. (PMID: 7839962) [\[CrossRef\]](#)
14. Linda A, Zuiani C, Girometti R, Londero V, Machin P, Brondani G, Bazzocchi M. Unusual malignant tumors of the breast: MRI features and pathologic correlation. *Eur J Radiol* 2010; 75: 178-184. (PMID: 19446418) [\[CrossRef\]](#)
15. Rodríguez MC, Secades AL, Angulo JM. Best cases from the AFIP: intracystic papillary carcinoma of the breast. *Radiographics* 2010; 30: 2021-2027. (PMID: 21057133) [\[CrossRef\]](#)