



Primary Neuroendocrine Carcinoma of the Breast: A Report of Three Cases

Faruk Aksoy¹, Ebubekir Gündeş¹, Celalettin Varansev¹, Murat Çakır¹, Hatice Toy², Ganime Dilek Emlik³

¹Department of General Surgery, Necmettin Erbakan University Faculty of Medicine, Konya, Turkey

²Department of Pathology, Necmettin Erbakan University Faculty of Medicine, Konya, Turkey

³Department of Radiology, Necmettin Erbakan University Faculty of Medicine, Konya, Turkey

ABSTRACT

Primary neuroendocrine carcinoma of the breast is extremely rare. More than 97% of neuroendocrine tumors occur in the gastrointestinal and respiratory tracts. Three cases that have been operated in our clinic and had a diagnosis of primary neuroendocrine carcinoma of the breast were assessed, along with literature data. Histopathological diagnoses were obtained by preoperative core needle biopsy. Breast-conserving surgery was performed in two cases, and modified radical mastectomy in one. In all cases, immunohistochemical studies were positive for neuron-specific enolase and synaptophysin. All patients received adjuvant chemotherapy (CT) and one patient received additional radiotherapy (RT). Recurrence or distant metastasis was not detected during long-term follow-up after surgery.

Key words: Mastectomy, breast cancer, carcinoma, neuroendocrine

Introduction

The rare primary neuroendocrine tumor of the breast can be identified by histopathological examination as well as detection of whether the tumor is metastatic. Primary neuroendocrine carcinoma of the breast is a relatively rare neoplasm, known to behave aggressively (1, 2). Cubilla and Woodruff have described this entity first in 1977 (1, 3) and since then only a few case reports have been published. Adequate excision and adjuvant chemotherapy provide a favorable prognosis (2). There are no disease-specific clinical and radiological findings (4). The definitive diagnosis is made by histopathological evaluation. We aimed to present three cases that were operated for breast cancer in our clinic, and had a pathological diagnosis of primary neuroendocrine carcinoma of the breast.

Case Presentations

Case 1

A 37 year-old female patient complained of a mass in her right breast for the last year. Her past medical history was uneventful. On physical examination, a mobile, firm lesion about 4x4 cm in size was palpated in the upper outer quadrant of the right breast. Both the left breast and axilla were normal. The mammography and ultrasonography revealed a 4x3 cm in size, lobulated lesion that was sharply separated from the surrounding glandular tissue and was located peripherally in the upper outer quadrant of the right breast. It was interpreted as BIRADS 3 and a biopsy was recommended. The chest X-ray, abdominal ultrasonography and bone scans were normal. The core needle biopsy showed neuroendocrine carcinoma, and breast conserving surgery and sentinel lymph node biopsy was performed. Due to sentinel lymph node positivity, axillary dissection was performed. The postoperative course was uneventful and the patient was discharged on the fifth day after withdrawal of her surgical drains.

The histopathological tumor size was 4x4x3.5 cm. On microscopic tumor sections, round or oval atypical cells with hyperchromatic pleomorphic core and narrow pink cytoplasm were observed to form nests or solid islands. In addition, tumor cells formed scarce rosette-like sequences and contained areas of atypical mitosis or necrosis. Immunohistochemically, the tumor cells stained positive for neuron specific enolase (NSE) and synaptophysin, and negative for estrogen, progesterone, CerbB2 and chromogranin. Following axillary dissection, metastases were detected in 3 out of 16 lymph nodes. The patient received adjuvant chemotherapy and radiotherapy after surgery. Neither recurrence nor distant metastasis was detected during the postoperative follow-up of 56 months.

This case was presented as a poster at the 11th National Breast Diseases Congress, 5-9 October 2011, Antalya, Turkey.

Address for Correspondence:

Ebubekir Gündeş, Department of General Surgery, Necmettin Erbakan University Faculty of Medicine, Konya, Turkey
Phone: +90 332 223 61 23 e-mail: ebubekir82@hotmail.com

Received: 12.10.2012
Accepted: 23.11.2012

Case 2

A 30-year-old woman who noticed a swelling on her right breast about 6 months ago admitted to our clinic. On physical examination, a painless, mobile, hard mass of about 5x4 cm in size was palpated in the lower outer quadrant of the right breast. There was right axillary lymphadenopathy. The left breast and axilla were normal. On ultrasonography a hypoechoic heterogeneous lobulated mass lesion, 44x40 mm in size was observed in the upper outer quadrant of the right breast. In breast magnetic resonance imaging, a mass that was heterogeneously hypointense on T2-weighted sequences and slightly hypointense as compared to glandular tissue on T1-weighted sequences was visualized in the axial plane of the lower outer quadrant of the right breast (Figure 1). It was interpreted as BIRADS-4 and a biopsy was recommended. The chest X-ray, abdominal ultrasonography and bone scans were normal.

The core biopsy result showed a carcinoma and the patient underwent modified radical mastectomy (Figure 2a, b). On pathological examination two separate tumors, 4.5 x3 and 2x2 in size were detected. The tumor was composed of round or oval cells with hyperchromatic or vesiculated cores and marked pink granular cytoplasm that form rosette-like structures and solid islands separated by fibrovascular septa (Figure 3). On immunohistochemical studies, the tumor stained positive for NSE, synaptophysin, CerbB2 and estrogen and negative for progesterone and chromogranin.

All 18 lymph nodes removed by axillary dissection were reactive. She received chemotherapy as adjuvant treatment. During the postoperative follow-up of 25 months, there was no recurrence or distant metastasis.

Case 3

A 61-year-old female patient was referred to our clinic due to a mass in her left breast that was detected during routine breast examination. Her past medical history was unremarkable. Her family history revealed that her mother had breast cancer. On physical examination, an approximately 1x1 cm sized, mobile, hard mass was palpated in the upper inner quadrant of the left breast. The mammography and ultrasonography showed a hypoechoic solid lesion with faint contours, 1x1 cm in size that was located in the upper inner quadrant of the left breast (Figure 4). The lesion was evaluated as BIRADS 4.

The core needle biopsy revealed neuroendocrine carcinoma. Breast conserving surgery and sentinel lymph node biopsy was performed. The sentinel node biopsy was negative and axillary dissection was not applied. The tumor was 1,5 x1x1 cm in size. On microscopic evaluation, the tumor was composed of round or oval atypical cells with hyperchromatic pleomorphic cores and narrow pink cytoplasm that form nests and solid islands. Immunohistochemically, the tumor stained positive for NSE, synaptophysin, estrogen, progesterone, and chromogranin, and negative for CerbB2. She received adjuvant che-

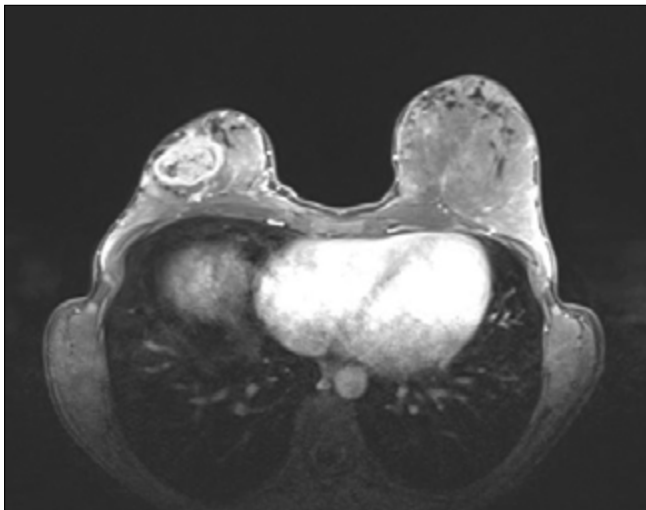


Figure 1. Magnetic resonance imaging view of breast mass in case 2.

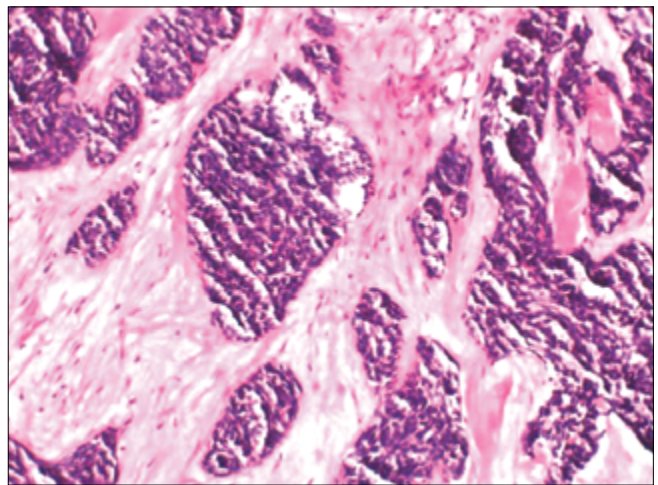


Figure 3. Neuroendocrine carcinoma composed of trabecular and solid islands with peripheral palisading pattern separated by fibrovascular stroma (HEX10)

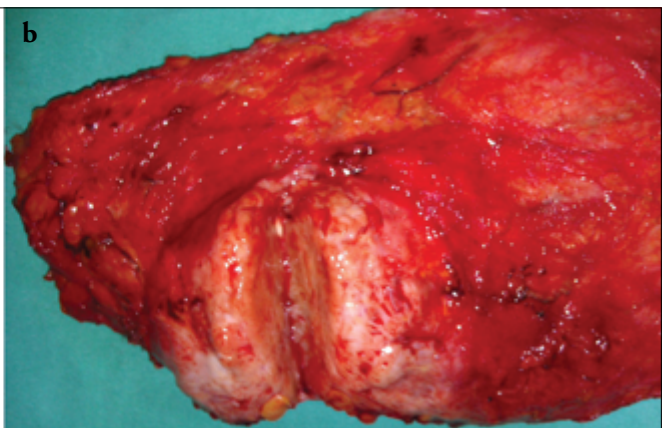
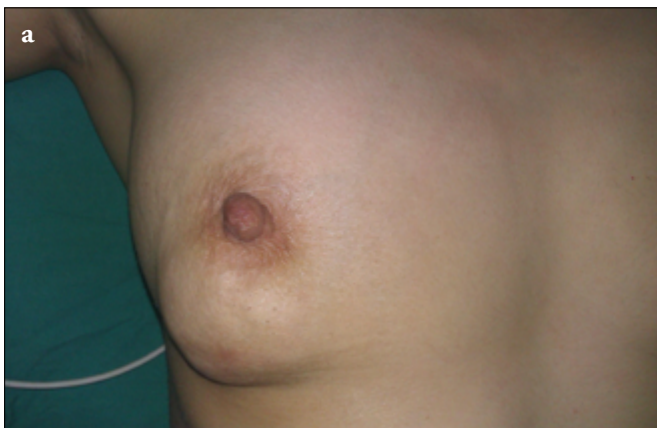

Figure 2. Preoperative view of the breast in case 2 (a). Cross-section of the specimen (b)

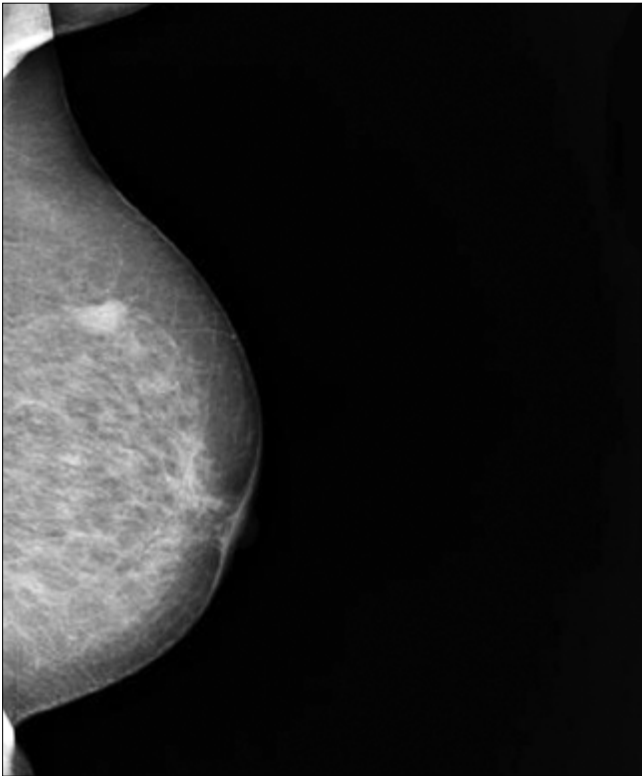


Figure 4. Mammographic view of a hypoechoic 1x1 cm solid lesion in the left breast upper inner quadrant in Case 3

motherapy. During the postoperative follow-up of 12 months, there was no recurrence or distant metastasis.

Discussion and Conclusions

Primary neuroendocrine carcinomas of the breast are relatively rare (1). Cubilla and Woodruff first defined it in 1977 (3). More than 97% of neuroendocrine tumors occur in the gastrointestinal and respiratory systems (1, 2). Neuroendocrine tumors are rarely described in cervix, prostate, pancreas, stomach, intestine, trachea, larynx and skin (5, 6). Although several authors have defined neuroendocrine neoplasms of the breast, the histogenesis is still uncertain, since the presence of neuroendocrine cells in the normal breast has not been proven yet (1-5). Endocrine differentiation is seen in 5-8% of breast carcinomas (6).

Diagnosis of primary neuroendocrine carcinoma can be made by proving that it does not originate from tissues other than the breast or identification of the in situ component (2-4). The World Health Organization (WHO) defined these tumors as 3 histological types in 2003; solid, small cell, large cell neuroendocrine carcinoma (2).

Neuron specific enolase, chromogranin A, and synaptophysin are considered as neuroendocrine markers and indicate the presence of neuroendocrine differentiation (2, 6). If neuroendocrine markers are observed in more than 50% of malignant cells, it is considered as a pure neuroendocrine tumor (1, 7). In addition, estrogen and progesterone receptor positivity provide additional evidence that the tumor is of primary breast origin (1). However, estrogen and progesterone positivity have been reported in some non-breast neuroendocrine tumors, especially in the lung (5, 8). In all three of our cases, NSE and synaptophysin were positive and the breast was found to be the primary focus.

Table 1. Patient demographics

	Case 1	Case 2	Case3
Age	37	30	61
Location	Right breast	Right breast	Left breast
Size (cm)	4	4.5	1.5
Treatment	BCS + CT + RT	MRM + CT	BCS + CT
Lymph node status	Positive	Negative	Negative
Disease-free follow up (month)	56	25	12
Recurrence or metastasis	No	No	No

BCS: Breast Conserving Surgery; CT: chemotherapy; RT: radiotherapy; MRM: modified radical mastectomy

Table 2. Immunohistochemical properties of the tumors

	Case 1	Case 2	Case3
NSE	+	+	+
Synaptophysin	+	+	+
Chromogranin A	-	-	+
ER	-	+	+
PR	-	-	+
Cerb B2	-	+	-

NSE: Neuron specific enolase; ER: estrogen receptor; PR: progesterone receptor

These tumors are usually seen in the 6th and 7th decades (1, 2, 5). There is only one report of a 52-year-old male patient in the literature (9). There are no specific clinical and imaging findings (1). The mean age of our patients was 42 (37-61) years. Clinical and radiographic findings were suggesting malignancy, but they were not specific for neuroendocrine carcinoma. The definitive preoperative diagnosis was made by core needle biopsy. The estrogen and progesterone receptors were both positive in one patient, both negative in another and one patient was positive for progesterone only. Patient demographic characteristics and immunohistochemical features of the tumor are summarized in Table 1 and Table 2.

With the determination of absence of any other primary focus, it was concluded that this tumor located in the breast is a pure primary neuroendocrine tumor of the breast. A sufficient idea regarding the presence of another tumor or metastasis can be obtained by thoracoabdominal CT and whole body bone scintigraphy (4, 5, 8). In all three cases, whole body scan was performed and there no other focus was detected.

Neuroendocrine carcinoma prognosis is still debatable due to the insufficient number of cases. Histologic grade is the most important prognostic factor (1). It is thought to have a good prognosis with adequate excision and adjuvant chemotherapy (2). The relationship of neuroendocrine differentiation with breast carcinoma prognosis has not been shown (5). According to latest reports, detection of the tumor at an early stage without lymph node metastasis is thought to provide a better prognosis (5, 6, 10, 11). Mucinous differentiation, estrogen and progesterone receptor positivity are favorable prognostic factors (1). The surgical treatment options were discussed with our patients; two cases underwent breast-conserving surgery, and modified radical mas-

tectomy was performed in one patient. Only one patient had axillary lymph node metastases. All patients received chemotherapy as adjuvant therapy and in the patient with axillary lymph node metastases RT was given in addition. No recurrence or metastasis was detected during the mean follow-up period of 33 (12-56) months.

Standard treatment method is controversial due to the rarity of these tumors. The detection of neuroendocrine tumors localized to the breast, either as classic breast cancer or as a separate clinical diagnosis, alters the treatment. Small cell neuroendocrine carcinoma of the breast is similar to small cell carcinoma of the lung in terms of morphological, clinical and histological features, thus their treatments are similar (6, 10-12).

Histopathological examination and excluding the presence of metastasis is important in primary neuroendocrine tumors of the breast. The impact of neuroendocrine differentiation on the clinical outcome is controversial. In all three cases, treatment approach for invasive breast tumors has been adopted. We believe that the prognosis of these tumors is favorable with early diagnosis, appropriate surgical and adjuvant treatments according to oncological principles. Data on larger series are required for clarification of treatment approaches.

Conflict of Interest: No conflict of interest was declared by the authors.

Peer-review: Externally peer-reviewed.

Informed Consent: Written informed consent was obtained from patients who participated in this case.

Author Contributions: Concept - F.A.; Design - E.G.; Supervision - C.V.; Funding - H.T., E.G.; Materials - F.A., E.G., G.D.E.; Data Collection and/or Processing - E.G., C.V.; Analysis and/or Interpretation - F.A., E.G.; Literature Review - E.G., C.V.; Writer - F.A., E.G., G.D.E.; Critical Review - F.A., E.G.

Financial Disclosure: The authors declared that this study has received no financial support.

References

1. Stita W, Trabelsi A, Gharbi O, Mokni M, Korbi S. Primary solid neuroendocrine carcinoma of the breast. *Can J Surg* 2009; 52:E289-290. (PMID: 20011167)
2. Kim JW, Woo OH, Cho KR, Seo BK, Yong HS, Kim A, Kang EY. Primary large cell neuroendocrine carcinoma of the breast: radiologic and pathologic findings. *J Korean Med Sci* 2008; 23:1118-1120. (PMID: 19119462) [[CrossRef](#)]
3. Cubilla AL, Woodruff JM. Primary carcinoid tumour of the breast: a report of eight patients. *Am J Surg Pathol* 1977; 4:283-292. [[CrossRef](#)]
4. Mariscal A, Balliu E, Díaz R, Casas JD, Gallart AM. Primary oat cell carcinoma of the breast: imaging features. *AJR Am J Roentgenol* 2004; 183:1169-1171. (PMID: 15385324) [[CrossRef](#)]
5. Adegbola T, Connolly CE, Mortimer G. Small cell neuroendocrine carcinoma of the breast: a report of three cases and review of the literature. *J Clin Pathol* 2005; 58:775-778. (PMID: 15976350) [[CrossRef](#)]
6. Kinoshita S, Hirano A, Komine K, Kobayashi S, Kyoda S, Takeyama H, Uchida K, Morikawa T, Nagase J, Sakamoto G.. Primary small-cell neuroendocrine carcinoma of the breast: report of a case. *Surg Today* 2008; 38:734-738. (PMID: 18668318) [[CrossRef](#)]
7. Sapino A, Righi L, Cassoni P, Papotti M, Pietribiasi F, Bussolati G. Expression of the neuroendocrine phenotype in carcinomas of the breast. *Semin Diagn Pathol* 2000; 17:127-137. (PMID: 10839613)
8. Harlak A, Zeybek N, Menteş Ö, Görgülü Z, Öngürü Ö, Peker Y, Somuncu İ, Tufan T. Primary neuroendocrine carcinoma of the breast. *J Breast Health* 2007; 3:156-159.
9. Jundt G, Schulz A, Heitz PU, Osborn M. Small cell neuroendocrine (oat cell) carcinoma of the male breast. Immunocytochemical and ultrastructural investigations. *Virchows Arch A Pathol Anat Histopathol* 1984; 404:213-221. (PMID: 6091325) [[CrossRef](#)]
10. Jochems L, Tjalma WA. Primary small cell neuroendocrine tumour of the breast. *Eur J Obstet Gynecol Reprod Biol* 2004; 115:231-233. (PMID: 15262362) [[CrossRef](#)]
11. Lütfi D, Niyazi K, Melda B, Cihangir Ö, Mehmet A. Small cell neuroendocrine carcinoma of the breast: case report and review of the literature. *The Journal of Breast Health* 2012; 8:200-203.
12. Salman WD, Harrison JA, Howat AJ. Small-cell neuroendocrine carcinoma of the breast. *J Clin Pathol* 2006; 59:888. (PMID: 16873572) [[CrossRef](#)]