



# Surgical Approach to Breast Hamartoma and the Diagnostic Accuracy in Preoperative Biopsies

## Meme Hamartomlarına Cerrahi Yaklaşım ve Preoperatif Biyopsilerde Tanının Doğruluğu

Cihad Tatar<sup>1</sup>, Fazilet Erözgen<sup>1</sup>, Sefa Tüzün<sup>1</sup>, Tamer Karşıdağ<sup>1</sup>, Erdem Yılmaz<sup>2</sup>, Hüsnü Aydın<sup>1</sup>, Celal Kızılkaya<sup>1</sup>, Bahri Özer<sup>1</sup>

<sup>1</sup>Department of General Surgery, Haseki Education and Research Hospital, İstanbul, Turkey

<sup>2</sup>Department of General Surgery, Okmeydanı Education and Research Hospital, İstanbul, Turkey

### ABSTRACT

**Objective:** Breast hamartomas are benign breast tumors, which are observed very rarely. We aimed to share our surgical approaches and a comparison of preoperative and postoperative pathology results of patients applying to breast polyclinics.

**Materials and Methods:** Out of 32.000 patients approximately, we reviewed data of 12 patients with the diagnosis of breast hamartoma retrospectively, who had applied to the breast polyclinic between dates of March 2007 and October 2012.

**Results:** All patients were female and their average age was 35 (17-58 years). Four of the hamartomas were detected in the right breast, and eight in the left breast. The average diameter of lesions was 7.3 cm (3-21cm). The diameter in our three cases was above 10 cm, and they were evaluated as giant hamartomas. All our cases underwent a fine needle aspiration biopsy (FNAB) or a core biopsy preoperatively. When the reports of preoperative biopsies performed on patients who had applied due to a palpable mass and the postoperative pathology reports were compared, it was detected that they showed a substantial correlation.

**Conclusion:** Hamartomas are benign tumors of the breast. The rate of preoperative diagnosis is high when physical examination, imaging and histopathology approaches are taken in combination. Although very rare, a surgical excision should be performed due to the malignant change in tumors.

**Key words:** Hamartoma, breast, biopsy

### ÖZET

**Amaç:** Meme hamartomları çok nadir görülen benign meme tümörleridir. Bu çalışmada meme polikliniğine başvuruda bulunan hastalarda preoperatif patoloji sonuçları ile postoperatif patoloji sonuçlarının karşılaştırılmasını ve cerrahi yaklaşımlarımızı paylaşmayı amaçladık.

**Yöntem ve Gereçler:** Mart 2007-Ekim 2012 tarihleri arasında meme polikliniğine başvuruda bulunan yaklaşık 32000 hasta arasından meme hamartomu tanısı alan 12 hastanın verilerini retrospektif olarak inceledik.

**Bulgular:** Tüm hastalar kadın olup yaş ortalaması 35 idi (min-maks; 17-58). Hamartomların dördü sağ memede sekizi sol memede saptandı. Lezyonların ortalama çapı 7,3 cm idi (min-maks; 3-21). Üç olguda lezyon çapı 10 cm üzerinde olup bu olgular dev hamartom olarak değerlendirildi. Olgularımızın hepsine preoperatif ince iğne aspirasyon biyopsisi (İİAB) veya kor biyopsi yapıldı. Ele gelen kitle ile başvuran hastalara yapılan preoperatif biyopsi ile postoperatif patoloji raporları karşılaştırıldığında büyük oranda korelasyon gösterdikleri tespit edildi.

**Sonuç:** Hamartomlar memenin iyi huylu tümörleridir. Fizik muayene, görüntüleme ve histopatolojinin birlikte ele alınmasıyla preoperatif tanı konma oranı yüksektir. Çok nadir de olsa malign değişim göstermesi sebebiyle cerrahi eksizyon yapılmalıdır.

**Anahtar sözcükler:** Hamartom, meme, biyopsi

### Introduction

Breast hamartomas are rarely seen, slowly growing and benign tumors (1-4). They can be observed in all age groups after puberty. Hamartomas in the male breast have been reported in only three cases. These tumors have smooth contours, and may include fat, fibrous and glandular tissue in various amounts. More than 60% of these are soft and cannot be palpated (5). As their contents vary, mammography findings show differences. A diagnosis is established by considering physical examination, imaging, and histopathology together (6).

Although these lesions were first called mastoma by Prym in 1928, then adenolipoma by Splading in 1945, and by Hogeman and Ostberg post-lactational breast tumors in 1968, they were finally identified as hamartoma by Arrigoni (1) in 1971.

In this study, we clinically, radiologically and histopathologically evaluated hamartoma which we have detected in our clinic.

### Materials and Methods

Out of 32.000 patients applying to the Breast Polyclinic of Haseki Training and Research Hospital between dates of March 2007 and October 2012, 12 patients with the diagnosis of breast hamartoma were examined retrospectively. The diagnosis of hamartoma was established by considering physical examination, imaging methods and histopathological findings together. Patients who had been diagnosed underwent a mass excision surgery. Excised masses were histopathologically reexamined once again. Patients who had been diagnosed

*This study was presented as a poster at the Meeting of New Approaches in Breast Cancer, 19-20 January 2013, İstanbul, Turkey.*

*Bu çalışma, Meme Kanseriinde Yeni Yaklaşımlar Toplantısı'nda poster olarak sunulmuştur, 19-20 Ocak 2013, İstanbul, Türkiye.*

**Address for Correspondence/Yazışma Adresi:**

Cihad Tatar, Department of General Surgery, Haseki Education and Research Hospital, İstanbul, Turkey

Phone / Tel.: +90 212 529 44 00 e-mail / e-posta: ctatargs@yahoo.com

Received / Geliş Tarihi: 14.11.2012

Accepted / Kabul Tarihi: 12.02.2013

by a biopsy performed prior to surgery, but were identified as non-hamartoma neoplasm in the pathological examination following the surgery, were excluded. Patients were asked to visit for purposes of control examination at 6-month intervals. Median follow-up period was 31 (min-max; 3-54) months. There was no ethics committee approval for this study. Written informed consent was obtained from patients who participated in this study.

### Statistical analysis

Data concerning demographic and clinical characteristics were analyzed by using descriptive methods (means, minimum-maximum). The statistical software used was SPSS for Windows, version 15.0 (SPSS Inc., Chicago, IL, USA).

### Results

All our patients applied to our polyclinic with the complaint of a palpable mass in the breast. All our patients were female, and the average age was 35 (min-max; 17-58). Hamartomas were detected in four patients in the right breast, and in seven patients in their left. The average diameter of the lesions was 7.3 cm (min-max; 3-21). The diameter of the lesion was above 10 cm in three patients, and those were evaluated as giant hamartoma (Table 1).

Our patients who had been identified with a palpable mass in the physical examination underwent ultrasonography and/or mammography. All our patients were identified as having a solid lesion. Results related to imaging had a benign appearance in ten patients, and two patients were

suspected of malignancy. Two patients with suspected malignancy underwent further imaging procedures by Magnetic Resonance Imaging (MRI); however, no findings which led to a differential diagnosis were detected radiologically, and the lesion identified in both cases was primarily considered as a fibroadenolipoma.

All patients underwent a preoperative biopsy. One patient received a fine needle aspiration biopsy (FNAB), while 11 patients underwent a core biopsy. Preoperative histopathological findings were consistent with hamartoma in eleven patients. In one patient receiving core biopsy, histopathological findings were found to be compatible with a phyllodes tumor. However, all the specimens were found to be consistent with hamartoma in the pathological examination of postoperatively excised masses.

### Discussion and Conclusions

Breast hamartoma make up 0.7% of benign breast tumors in females (7). The average age of incidence is around 45 years, and most of the patients are above 35 years of age. In our series, the patients were aged between 17-58, and the average age was determined as 35 years. Six patients were above 35 years of age, and six patients were under 35. Three cases of breast hamartoma have been reported in the literature, which could also be seen in males (8-10). All patients in our series were female.

The size of hamartomas in the literature vary between 1-25 cm (2). In our series, lesions with varying sizes of 3-21 cm were detected, and the average diameter was determined as 7.3 cm.

Table 1. Clinical summary of cases

Patient	Age (years)	Localization (quadrant)	USG	Mammography	MR	Biopsy FNAB	Size (cm)	Follow up (months)
1	58	Right Lower outer	+	+	-	Hamartoma	21x17x14	34
2	38	Left Upper outer	+	-	-	Hamartoma	3x6x4	23
3	17	Left Lower outer	+	-	-	Hamartoma	6x4x5	3
4	36	Right Lower outer	+	-	+	Hamartoma	7x5x4	18
5	29	Left Lower outer	+	-	-	Hamartoma	6x4x3	22
6	46	Left Lower inner	+	+	-	Phyllodes tumor	5x4x4	38
7	33	Left Upper outer	+	-	-	Hamartoma	3x2x3	46
8	27	Right Lower inner	+	-	-	Hamartoma	4x3x3	54
9	32	Right Lower outer	+	+	-	Hamartoma	3x4x4	44
10	23	Left Upper outer	+	-	+	Hamartoma	2x3x4	27
11	36	Left Lower outer	+	-	-	Hamartoma	10x8x7	34
12	44	Left Upper outer	+	+	-	Hamartoma	12x10x5	3

FNAB: Fine needle aspiration biopsy, +: done, -: was not done

Table 2. Localization of hamartomas

Localization (quadrant)	Patient (n)
Upper outer	4
Lower outer	6
Lower inner	2

Hamartomas are painless and slowly-growing tumors, which are mostly localized in the outer quadrant of the breast (7, 11). All the patients in our study presented with the complaint of a palpable painless mass. In studies, it has been reported that hamartomas are recorded as 2 times more frequently in the left breast and that 39% of those are localized in the upper outer quadrant (12). In our series, it has also been identified that lesions are localized twice as often in the left breast (in the left breast in eight patients, in the right breast in four patients). Four cases were identified with hamartoma in the upper outer quadrant, six cases in the lower outer quadrant, and two cases had those in the lower inner quadrant (Table 2).

They are painless, slowly-growing masses, which are mostly localized in the outer quadrant and do not invade the surrounding tissues. These lesions, which may be taken for fibroadenoma or phyllodes tumors, cannot be palpated and are only identified in mammography.

Pathologically, there are findings where a microglandular adenosis is present in fibroadipose stroma surrounded by a thin fibrous capsule (13). In these lesions, a cure can be ensured by local excision (14). They are not malignant lesions, but cases with recurrence have been reported (3, 4). The median follow-up period of the patients in our series was 31 months (min-max; 3-54), and no recurrence was noted. Very rarely, it has also been reported that hamartomas develop into carcinoma (7). While an invasive lobular carcinoma is reported to develop in some publications, development of ductal carcinoma is the most frequently reported (15-21). Thus, once the diagnosis is established, an excision should be performed (Figure 1-3).

Hamartomas are soft, mobile lesions with smooth contours, which have a nature similar to normal breast tissue (3). They are lesions that can be well-contoured and have thin capsules, and which show opacity in various degrees mammographically, depending on the fat amount in the breast tissue (Figure 4). Ultrasonography findings resemble the mammographic appearance. Breast hamartomas are not a substitute for the breast tissue, but they only occupy space by pushing the breast parenchyma (4, 22). In MRI, they appear as well-contoured and intense with breast tissue, surrounded with smooth capsule. All our patients underwent ultrasonography. Further imaging was performed on six patients by mammography and on two patients by MRI. Erdem et al. (23) reported that clinical and imaging findings are more important in diagnosis, and that the fine needle aspiration biopsy or the core biopsy has a limited contribution in diagnosis. However, in our study no findings suggesting hamartomas were detected in patients by imaging methods. Out of twelve patients, 11 of those were diagnosed with hamartoma by a preoperative biopsy.

In this study, we determined that preoperative biopsies show a substantial correlation with postoperative pathology results. Therefore, also considering the risk of a developing carcinoma, though very rarely, local excision by a preoperative biopsy should be performed on patients diagnosed with breast hamartoma.



Figure 1. Giant hamartoma on the left lower outer quadrant

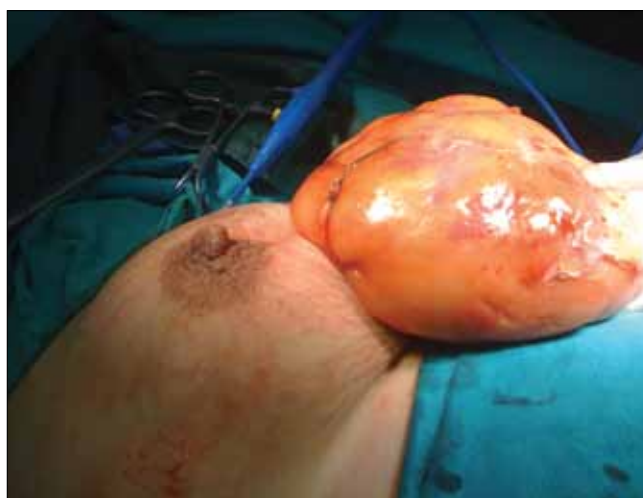

Figure 2. Image of intraoperative hamartoma

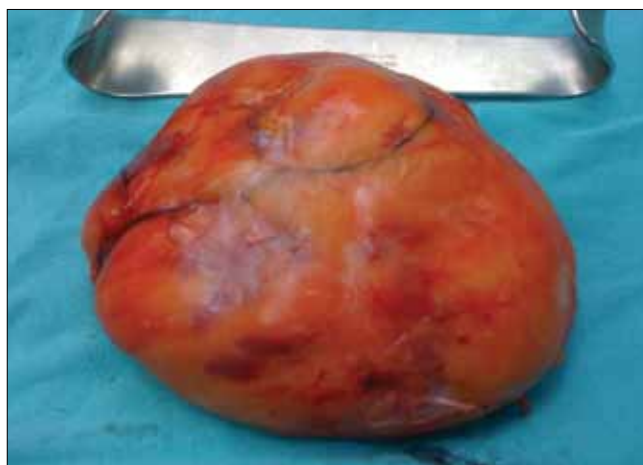

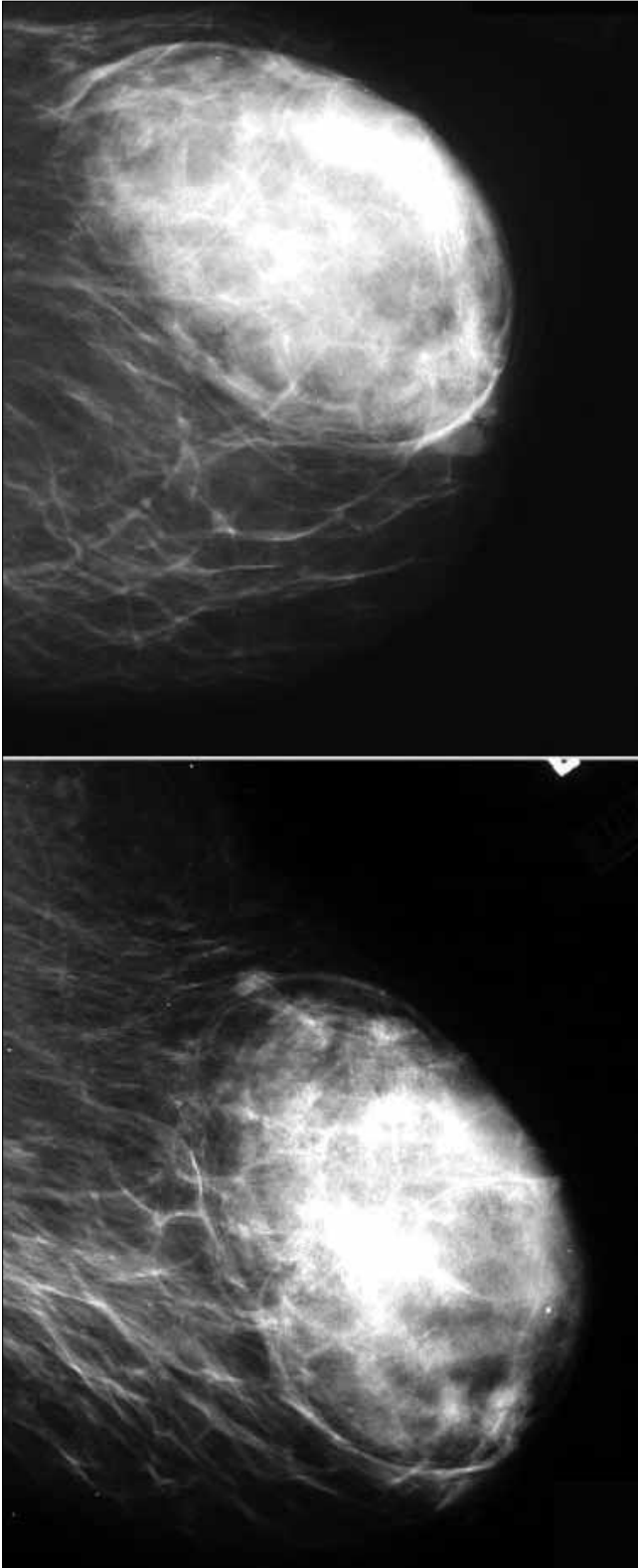
Figure 3. Breast hamartoma immediately following removal

**Conflict of Interest**

No conflict of interest was declared by the authors.

**Peer-review:** Externally peer-reviewed.

**Informed Consent:** Written informed consent was obtained from patients who participated in this study.



**Figure 4.** Mammographic image of hamartoma

#### Author Contributions

Concept - F.E., C.T.; Design - C.T., F.E.; Supervision - F.E., S.T., T.K.; Funding - C.T., C.K., E.Y.; Materials - C.T., F.E., C.K.; Data Collection and/or Processing - F.E., C.T., C.K., E.Y., H.A., B.Ö.; Analysis and/or Interpretation - F.E., C.T.; Literature Review - C.T., F.E., C.K.; Writer - C.T., F.E., C.K.; Critical Review - F.E., S.T., T.K.; Other - F.E., C.T., C.K.

#### Çıkar Çatışması

Yazarlar herhangi bir çıkar çatışması bildirmemişlerdir.

**Hakem değerlendirmesi:** Dış bağımsız.

**Hasta Onamı:** Yazılı hasta onamı bu çalışmaya katılan hastalardan alınmıştır.

#### Yazar Katkıları

Fikir - F.E., C.T.; Tasarım - C.T., F.E.; Denetleme - F.E., S.T., T.K.; Kaynaklar - C.T., C.K., E.Y.; Malzemeler - C.T., F.E., C.K.; Veri toplanması ve/veya işlemesi - F.E., C.T., C.K., E.Y., H.A., B.Ö.; Analiz ve/veya yorum - F.E., C.T.; Literatür taraması - C.T., F.E., C.K.; Yazıyı yazan - C.T., F.E., C.K.; Eleştirel İnceleme - F.E., S.T., T.K.; Diğer - F.E., C.T., C.K.

#### References

1. Arrigoni MG, Dockerty MB, Judd ES. The identification and treatment of mammary hamartoma. *Surg Gynecol Obstet* 1971; 133: 577-82. (PMID: 5096305)
2. Anani PA, Hessler C. Breast hamartoma with invasive ductal carcinoma. Report of two cases and review of the literature. *Pathol Res Pract* 1996; 192: 1187-94. (PMID: 9182287) [CrossRef]
3. Tse GM, Law BK, Ma TK, Chan AB, Pang LM, Chu WC, et al. Hamartoma of the breast: a clinicopathological review. *J Clin Pathol* 2002; 55: 951-4. (PMID: 12461066) [CrossRef]
4. Daya D, Trus T, D'Souza TJ, Minuk T, Yemen B. Hamartoma of the breast, an underrecognized breast lesion. A clinicopathologic and radiographic study of 25 cases. *Am J Clin Pathol* 1995; 103: 685-9. (PMID: 7785651)
5. Ruiz-Tovar J, Reguero-Callejas ME, Arano-Bermejo JI, Gonzalez-Palacios F, Cabanas-Navarro L. [Mammary hamartoma]. *Cir Esp* 2006; 79: 186-8. (PMID: 16545287) [CrossRef]
6. Weinzwieg N, Botts J, Marcus E. Giant Hamartoma of The Breast. *Plast Reconstr Surg* 2001; 15: 1216-20. (PMID: 11373565) [CrossRef]
7. Lee EH, Wylie EJ, Bourke AG, Bastiaan De Boer W. Invasive ductal carcinoma arising in a breast hamartoma: two case reports and a review of the literature. *Clin Radiol* 2003; 58: 80-3. (PMID: 12565210) [CrossRef]
8. Khadilkar V, Jehagirdar R. Breast hamartoma presenting as prepubertal gynecomastia. *Indian Pediatr* 2009; 46: 446-7. (PMID: 19478367)
9. Deshpande A, Munshi M. Mammary hamartoma: report of two cases including one in a male breast, and review of the literature. *Indian J Pathol Microbiol* 2004; 47: 511-5. (PMID: 16295379)
10. Ravakhah K, Javadi N, Simms R. Hamartoma of the breast in a man: first case report. *Breast J* 2001; 7: 266-8. (PMID: 11678806) [CrossRef]
11. Charpin C, Mathoulin MP, Andrac L, Barberis J, Boulat J, Sarradour B, et al. Reappraisal of breast hamartomas. A morphological study of 41 cases. *Pathol Res Pract* 1994; 190: 362-71. (PMID: 8078805) [CrossRef]
12. Wahner-Roedler DL, Sebo TJ, Gisvold JJ. Hamartomas of the breast: clinical, radiologic, and pathologic manifestations. *Breast J* 2001; 7: 101-5. (PMID: 11328316) [CrossRef]
13. Fisher CJ, Hanby AM, Robinson L, Millis RR. Mammary hamartoma-a review of 35 cases. *Histopathology* 1992; 20: 99-106. (PMID: 1559675) [CrossRef]
14. Jones MW, Norris HJ, Wargotz ES. Hamartomas of the breast. *Surg Gynecol Obstet* 1991; 173: 54-6. (PMID: 1866672)
15. Baron M, Ladonne JM, Gravier A, Picquenot JM, Berry M. Invasive lobular carcinoma in a breast hamartoma. *Breast J* 2003; 9: 246-8. (PMID: 12752637) [CrossRef]
16. Schrage CA, Schneider D, Gruener AC, Tsou HC, Peacocke M. Clinical and pathological features of breast disease in Cowden's syndrome: an underrecognized syndrome with an increased risk of breast cancer. *Hum Pathol* 1998; 29: 47-53. (PMID: 9445133) [CrossRef]
17. Tse GM, Law BK, Pang LM, Cheung HS. Ductal carcinoma in situ arising in mammary hamartoma. *J Clin Pathol* 2002; 55: 541-2. (PMID: 12101205) [CrossRef]

18. Ruiz-Tovar J, Reguero-Callejas ME, Aláez AB, Ramiro C, Rojo R, Colado MV, et al. Infiltrating ductal carcinoma and ductal carcinoma in situ associated with mammary hamartoma. *Breast J* 2006; 12: 368-70. (PMID: 16848850) [\[CrossRef\]](#)
19. Mester J, Simmons RM, Vazquez MF, Rosenblatt R. In situ and infiltrating ductal carcinoma arising in a breast hamartoma. *AJR Am J Roentgenol* 2000; 175: 64-6. (PMID: 10882247) [\[CrossRef\]](#)
20. Scally N, Campbell W, Hall S, McCusker G, Stirling WJ. Invasive ductal carcinoma arising within a breast hamartoma. *Ir J Med Sci* 2011; 180: 767-8. (PMID: 19662489) [\[CrossRef\]](#)
21. Kai M, Tada K, Tamura M, Gomi N, Horii R, Akiyama F, et al. Breast cancer associated with mammary hamartoma. *Breast Cancer* 2012; 19: 183-6. (PMID:19657714) [\[CrossRef\]](#)
22. Herbert M, Schvimer M, Zehavi S, Mendlovic S, Karni T, Pappo I, et al. Breast hamartoma: fine-needle aspiration cytologic finding. *Cancer* 2003; 99: 255-8. (PMID: 12925988) [\[CrossRef\]](#)
23. Erdem G, Karakaş HM, Işık B, Fırat AK. Advanced MRI findings in patients with breast hamartomas. *Diagn Interv Radiol* 2011; 17: 33-7. (PMID: 20658447)